RIO DE JANEIRO DENTAL JOURNAL

REVISTA CIENTÍFICA DO CRO-RJ

revcientifica.cro-rj.org.br

Editors-in-Chief
Lucianne Cople Maia
Andréa Fonseca-Gonçalves

Volume 5 - Nº2
May - August, 2020

ISSN 1518-5249
e-ISSN 2595-4733

IMAGEM FREEPIK

CRO RJ

The official journal of the
Conselho Regional de Odontologia do Rio de Janeiro

REVISTA CIENTÍFICA DO CRO-RJ (RIO DE JANEIRO DENTAL JOURNAL)

Conselho Regional de Odontologia do Rio de Janeiro
President: Altair Dantas de Andrade
Secretary: Ricardo Guimarães Fischer
Financial officer: Outair Bastazini Filho
Counselors: Felipe Melo de Araujo, Igor Bastos Barbosa, Juarez D´Avila Rocha Bastos, Leonardo Alcântara Cunha Lima, Marcelo Guerino Pereira Couto, Maria Cynesia Medeiros de Barros e Sávio Augusto Bezerra de Moraes

Editors-in-Chief/Editoras-chefes
• Lucianne Cople Maia de Faria
Professora Titular do Departamento de Odontopediatria e Ortodontia da Universidade Federal do Rio de Janeiro - maia_lc@ufrj.br
• Andréa Fonseca-Gonçalves
Professora Adjunta do Departamento de Odontopediatria e Ortodontia da Universidade Federal do Rio de Janeiro - andrea.goncalves@odonto.ufrj.br

Associate Editors / Editores Associados
Alessandra Buhler Borges (Unesp – SJC), Brazil
Alexandre Rezende Vieira (University of Pittsburgh), EUA
Anna Fuks (Hebrew University of Jerusalem), Israel
Antônio Carlos de Oliveira Ruellas (UFRJ), Brazil
Glória Fernanda Barbosa de Araújo Castro (UFRJ), Brazil
Ivo Carlos Corrêa (UFRJ), Brazil
Júnia Maria Cheib Serra-Negra (UFMG), Brazil
Laura SalignacGuimarães Primo (UFRJ), Brazil
Luiz Alberto Penna (UNIMES), Brazil
Marco Antonio Albuquerque de Senna (UFF), Brazil
Maria Augusta Portella Guedes Visconti (UFRJ), Brazil
Mauro Henrique Abreu (UFMG)
Senda Charone (UnB), Brazil
Tatiana Kelly da Silva Fidalgo (UERJ), Brazil
Walter Luiz Siqueira (University of Saskatchewan), Canada
Yuri Wanderley Cavalcanti (UFPB), Brazil

Ad Hoc Consultants
Adilis Kalina Alerxandria de França (UERJ), Brazil
Alessandra Reis Silva Loguercio (UEPG), Brazil
Alfredo Carrillo Canela (UAA), Paraguai
Aline Abrahão (UFRJ), Brazil
Ana Maria Gondim Valença (UFPB), Brazil
Andréa Neiva da Silva (UFF), Brazil
Andréa Pereira de Morais (UNIVERSO), Brazil
Andréa Vaz Braga Pintor (UFRJ), Brazil
Bianca Marques Santiago (UFPB), Brazil
Branca Heloisa Oliveira (UERJ), Brazil
Brenda Paula F. de Almeida Gomes (FOP-UNICAMP), Brazil
Camillo Anauate Netto (GBPD), Brazil
Carlos José Soares (UFU), Brazil
Casimiro Abreu Possante de Almeida (UFRJ), Brazil
Celso Silva Queiroz (UERJ), Brazil
Cinthia Pereira M. Tabchoury (FOP/UNICAMP), Brazil
Cláudia Maria Tavares da Silva (UFRJ), Brazil
Cláudia Trindade Mattos (UFF), Brazil
David Normando (UFPA), Brazil
Denise Fernandes Lopes Nascimento (UFRJ), Brazil
Eduardo Moreira da Silva (UFF), Brazil
Fabian Calixto Fraiz (UFPR), Brazil
Gisele Damiana da Silveira Pereira (UFRJ), Brazil
Issis Luque Martinez (PUC), Chile
Jonas de Almeidas Rodrigues (UFRGS), Brazil
Jônatas Caldeira Esteves (UFRJ), Brazil
José Valladares Neto (UFG), Brazil
Kátia Regina Hostilio Cervantes Dias (UFRJ), Brazil
Leopoldina de Fátima Dantas de Almeida (UFPB), Brazil
Lívia Azeredo Alves Antunes (UFF/Nova Friburgo), Brazil
Luciana Pomarico Ribeiro (UFRJ), Brazil
Maíra do Prado (FO-UVA), Brazil
Maria Cynésia Medeiros de Barros (UFRJ), Brazil
Maria Eliza Barbosa Ramos (UERJ), Brazil
Maria Elisa Janini (UFRJ), Brazil
Mariane Cardoso (UFSC), Brazil
Mario Vianna Vettore (UFMG), Brazil
Maristela Barbosa Portela (UFF), Brazil
Matheus Melo Pithon (UESB), Brazil
Matilde da Cunha Gonçalves Nojima (UFRJ), Brazil
Martinna Bertolini (University of Connecticut), USA
Michele Machado Lenzi da Silva (UERJ), Brazil
Miguel Muñoz (University of Valparaiso), Chile
Mônica Almeida Tostes (UFF), Brazil
Paula Vanessa P. Oltramari-Navarro (UNOPAR), Brazil
Paulo Nelson Filho (FORP),Brazil
Patrícia de Andrade Risso (UFRJ), Brazil
Rafael Rodrigues Lima (UFPA),Brazil
Rejane Faria Ribeiro-Rotta (UFG), Brazil
Roberta Barcelos (UFF), Brazil
RogérioLacerda Santos (UFJF) Brazil
Ronaldo Barcellos de Santana (UFF), Brazil
Ronir Ragio Luiz (IESC/UFRJ), Brazil
Samuel Jaime Elizondo Garcia (Universidad de León), México
Sandra Torres (UFRJ), Brazil
Taciana Marco Ferraz Caneppele (UNESP), Brazil
Tiago Braga Rabello (UFRJ), Brazil
Thiago Machado Ardenghi (UFSM), Brazil

Disclaimer
The Publisher, CRO-RJ and Editors cannot be held responsible for errors or any consequences arising from the use of information contained in this journal; the views and opinions expressed do not necessarily reflect those of the Publisher, CRO-RJ and Editors, neither does the publication of advertisements constitute any endorsement by the Publisher,CRO-RJ and Editors of the products advertised.

MAIL/CORRESPONDÊNCIA
All mail shoud be sent to revistacientifica@cro-rj.org.br
Toda correspondência deve ser enviada à Secretaria no endereço abaixo:
revistacientifica@cro-rj.org.br

ISSN (print): 1518-5249
e-ISSN 2595-4733

CONSELHO REGIONAL DE ODONTOLOGIA DO RIO DE JANEIRO
REVISTACIENTÍFICADOCRORJ(
RIODEJANEIRODENTALJOURNAL)
Rua Araújo Porto Alegre, 70, 5º andar, Centro, Rio de Janeiro-RJ - Cep 20030-015 • Tel. (21) 3505-7600. - Site: www.cro-rj.org.br
Graphic Design: Claudio Santana
Librarian: Vinicius da Costa Pereira
Trainee Librarian: Aline Chahoud e Jefferson Igor da Silva Farias
Information Technology Intern: Moisés Limeira e Paulo Felippe
Available on: www.revcientifica.cro-rj.org.br
2018 - Conselho Regional de Odontologia do Rio de Janeiro

Revista Científica do CRO-RJ (Rio de Janeiro Dental Journal)

Volume 5, Number 2

Summary
Contents

Editorial

Is it still worth treating patients with periodontal disease in the new era of dentistry?
Antonio Canabarro 1

Review

Nutritional influences on oral infections: the oral microbiota modulation
Marvin do Nascimento, Manoela Pereira Smith Silvestre, André Luiz Amorim da Costa, Mariana Barbosa Lopes, Talita Gomes Baeta Lourenço, Aline Tany Posch 2

Are glass carbomer sealants more efficient in preventing carious lesions in children's permanent molars when compared to other sealant materials? A systematic review and meta analysis
Célia Maria Condeixa de França Lopes, Letícia Maíra Wambier, Ana Cláudia Rodrigues Chibinski, Alessandra Reis, Denise Stadler Wambier 16

Original Article

Remnant adhesive flash in orthodontic bonding systems with different characteristics
Erika Machado Caldeira, Paola Estefan Sass, Vicente Telles, Nathalia Lima Freze Fernandes, Claudia Trindade Mattos, Carlos Nelson Elias, Ana Maria Bolognese, Matilde da Cunha Gonçalves Nojima 36

Impact of oral health on the quality of life and personal satisfaction of adolescents from urban and rural areas from a city in brazil: a cross-sectional study .....
Hiorran Coelho Almeida Matos, Gabrielle Carrozzino, Andréa Vaz Braga Pintor, Ivete Pomarico Ribeiro de Souza, Michelle Mikhael Ammari, Luciana Pomarico 43

Influence of cigarette smoke on enamel color stability after orthodontic debonding: an in vitro study
Flávio de Mendonça Copello, André Ramos Losso, Kelly Galisteu Luiz, Larine Ferreira Lira, Amanda Cunha Regal de Castro, Mônica Tirre de Souza Araujo 50

Case Report

Dental management for a child with Smith-magenis Syndrome under general anesthesia: case report
Sara Kelly Gurjão Farias, Desirée de Jesus Portelinha, Mônica Almeida Tostes, Viviane de Andrade Cancio de Paula 56

Impaction of mandibular canine associated with a dentigerous cyst: a 2.5-year follow-up report
Thiago Isidro Vieira, Thais Rodrigues Campos Soares, Priscila Assunção de Almeida, Fernanda Blaudt Carvalho Marques, Monica Tirre de Souza Araújo, Glória Fernanda Barbosa de Araújo Castro 61

Mirror image: a rare case of prolonged tooth retention in twins
Viviane Andrade Cancio de Paula, Maristela Barbosa Portela, Roberta Barcelos, Laura Guimarães Primo 65

The effect of a chemomechanical protocol to eliminate microorganisms from pulpectomized primary teeth: three case reports
Maysa Lannes Duarte, Daniele Vieira Cassol, Carolina Barbosa Andrade, Natalia Lopes Pontes Iorio, Andréa Fonseca-Gonçalves, Laura Guimarães Primo 69

IS IT STILL WORTH TREATING PATIENTS WITH PERIODONTAL DISEASE IN THE NEW ERA OF DENTISTRY?

Current advances in the medical field have facilitated the diagnosis and treatment of various diseases.[1] As periodontal disease (PD) is a widespread chronic inflammatory illness, reaching up to 80% of the Latin America population,[2] the scientific and technological arsenal for its management are made available to dental professionals during academic learning or through continued education. However, despite all knowledge related to PD, it is especially intriguing that even though several studies have shown the possibility of controlling PD for long periods of time, through a regular and effective mechanical control of the biofilm,[3] it remains so prevalent.

On the other hand, therapies that aim to replace teeth are gaining more space. As people prefer to maintain their teeth,[4] and the longevity of teeth and dental implant seems to be similar,[5] it is paradoxical that treatment modalities that replace natural teeth by artificial ones are increasingly popular among professionals and patients, especially if you consider that such treatment proposal does not decrease the prevalence of PD and is only available to a few people.

It is urgent to discuss a crucial point of periodontal treatment. Several studies present a treatment protocol that includes supra-and subgingival mechanical debridement at the same appointment.[6] Because the entire treatment requires only a few sessions, and the patient is not yet able to self-control the biofilm, the risk of periodontal pockets' recontamination increases, thus perpetuating the disease. Patients should receive repeated oral hygiene instructions, supragingival scaling and tooth cleaning before subgingival professional debridement, in order to learn how to maintain a low plaque score and to prevent cross-contamination in the post-active therapy phase.[6] The critical challenge of periodontal treatment is neither the lack of knowledge about the disease, nor the technical complexity involved in its therapy. Patients must change their lifestyle; they also need to be in a periodic maintenance schedule to stay focused on biofilm control.[7] Just by following these steps, you can guarantee long-term periodontal treatment success.[8]

It's unquestionable that treatments with dental substitutes can be considered as an option, especially after evaluating the survival rate of teeth. But it would be important to make more efforts in order to treat PD, focusing on what really works, mainly because it does not seem valid to offer treatment alternatives that are also harmed by the ubiquitous presence of biofilm, like dental implants. Undoubtedly, new cosmetic and reconstructive techniques and technologies have potential applications to satisfy the specific needs of the patient,[9] but as stated by Pjetursson et al. (2018)[10], implants are supposed to replace missing teeth, they are not supposed to replace teeth.

How about giving natural teeth a new chance?

REFERENCES

1. Lopes MT, Koch VH, Sarrubbi-Junior V, Gallo PR, Carneiro-Sampaio M. Difficulties in the diagnosis and treatment of rare diseases according to the perceptions of patients, relatives and health care professionals. Clinics (Sao Paulo). 2018;73:e68. doi: 10.6061/clinics/2018/e68.
2. Oppermann RV. An overview of the epidemiology of periodontal diseases in Latin America. Braz Oral Res. 2007;21:8-15. doi: 10.1590/S1806-83242007000500003.
3. Axelsson P, Nyström B, Lindhe J. The long-term effect of a plaque control program on tooth mortality, caries and periodontal disease in adults. Results after 30 years of maintenance. J Clin Periodontol. 2004 Sep;31(9):749-57. doi: 10.1111/j.1600-051X.2004.00563.x.
4. Re D, Ceci C, Cerutti F, Fabbro MD, Corbella S, Taschieri S. Natural tooth preservation versus extraction and implant placement: patient preferences and analysis of the willingness to pay. Br Dent J. 2017 Mar;222(6):467-71. doi: 10.1038/sj.bdj.2017.271.
5. Tomasi C, Wennstrom JL, Bergglundh T. Longevity of teeth and implants – systematic review. J Oral Rehabil. 2008 Jan;35(Suppl 1):23-32. doi: 10.1111/j.1365-2842.2007.01831.x.
6. Canabarro A, Marcantonio É Jr, De-Deus G. Use of the Strength of Recommendation Taxonomy (SORT) to assess full-mouth treatments of chronic periodontitis. J Oral Sci. 2015;57(4):345-53. doi: 10.2334/josnusd.57.345.
7. Chapple IL, Bouchard P, Cagetti MG, Campus G, Carra MC, Cocco F, et. al. Interaction of lifestyle, behaviour or systemic diseases with dental caries and periodontal diseases: consensus report of group 2 of the joint EFP/ORCA workshop on the boundaries between caries and periodontal diseases. J Clin Periodontol. 2017 Mar;44(Suppl 18):S39-S51. doi: 10.1111/jcpe.12685.
8. Shumaker ND, Metcalf BT, Toscano NT, Holtzclaw DJ. Periodontal and periimplant maintenance: a critical factor in long-term treatment success. Compend Contin Educ Dent. 2009 Sep;30(7):388-90.
9. Blatz MB, Chiche G, Bahat O, Roblee R, Coachman C, Heymann HO. Evolution of Aesthetic Dentistry. J Dent Res. 2019 Nov;98(12):1294-304. doi: 10.1177/0022034519875450.
10. Pjetursson BE, Heimisdottir K. Dental implants - are they better than natural teeth? Eur J Oral Sci. 2018 Oct;126(Suppl 1):81-7. doi: 10.1111/eos.12543.

Antonio Canabarro

Full Professor, Department of Periodontology, Universidade Veiga de Almeida (UVA), Rio de Janeiro, RJ, Brazil.
Associate Professor, Department of Periodontology, Universidade do Estado do Rio de Janeiro (UERJ), Rio de Janeiro, RJ, Brazil.

NUTRITIONAL INFLUENCES ON ORAL INFECTIONS: THE ORAL MICROBIOTA MODULATION

Marvin do **Nascimento**[1,3*], Manoela Pereira Smith **Silvestre**[2], André Luiz Amorim da **Costa**[3], Mariana Barbosa **Lopes**[4], Talita Gomes Baeta **Lourenço**[3], Aline Tany **Posch**[1]

[1]Department of Prosthesis and Dental Materials, Dental School, Universidade Federal do Rio de Janeiro, Rio de Janeiro, RJ, Brazil.
[2]Institute of Nutrition Josué de Castro, Universidade Federal do Rio de Janeiro, Rio de Janeiro, RJ, Brazil.
[3]Department of Medical Microbiology, Institute of Microbiology, Universidade Federal do Rio de Janeiro, RJ, Brazil.
[4]Medical School (Cardiology), Universidade Federal do Rio de Janeiro, Rio de Janeiro, RJ, Brazil.

Palavras-chave: Microbiota Oral. Cárie Dentária. Doença Periodontal. Saúde Nutricional. Probiótico. Prebiótico.

RESUMO

Introdução: A microbiota oral possui aproximadamente 700 microrganismos simbiontes responsáveis pela homeostase da saúde bucal. Contudo, alterações na microbiota oral podem gerar processos disbióticos que favorecem o agravamento de infecções como a cárie e a doença periodontal. Essas infecções orais, além do acometimento sistêmico, podem comprometer a integridade dos dentes e também da saúde bucal. Dessa forma, a alimentação inadequada mostra-se um fator de risco que influência na prevenção e no tratamento dessas infecções orais. **Objetivo**: Este estudo visa evidenciar a influência nutricional na modulação da microbiota oral afetando a longo prazo a microbiota intestinal, destacando o uso de probióticos e prebióticos no tratamento de infecções orais através de uma revisão de literatura. **Síntese de dados**: A suplementação de determinados nutrientes e a ingestão de uma dieta adequada em macronutrientes e micronutrientes influenciam diretamente no estado nutricional e consequentemente na manutenção da homeostase oral-sistêmica. Além disso, devido à multirresistência microbiana, terapias com probióticos e prebióticos têm sido adotadas como auxiliares no tratamento de infecções orais. **Conclusão**: A Odontologia Personalizada deve integrar conhecimentos multidisciplinares de atenção à saúde. Isso além de saber quando encaminhar e trabalhar junto com o Nutricionista.

Keywords: Oral Microbiota. Dental Caries Periodontal Disease. Health Nutrition. Probiotic and Prebiotic.

ABSTRACT

Introduction: The oral microbiota has approximately 700 symbiotic microorganisms responsible for oral health homeostasis. However, changes in oral microbiota can generate dysbiotic processes that favor the worsening of infections such as caries and periodontal disease. These oral infections, in addition to systemic involvement, can compromise the teeth integrity as well as oral health. Thus, inadequate nutrition proves to be a risk factor influencing the prevention and treatment of these oral infections. **Objective**: This study aims to evidence the nutritional influence on the oral microbiota modulation affecting, in the longterm, the gut microbiota, highlighting the use of probiotics and prebiotics in the treatment of oral infections by a literature review. **Synthesis of data** : Supplements of certain nutrients and the intake of an adequate diet in macronutrients and micronutrients directly influence nutritional status and consequently in the maintenance of oral-systemic homeostasis. In addition, due to microbial multidrug resistance, therapies using probiotics and prebiotics have been adopted as aids to the treatment of oral infections. **Conclusion**: Personalized Dentistry must integrate multidisciplinary knowledge of attention for health care. This in addition to knowing when to refer and work together with a Nutritionist.

Submitted: October 20, 2020
Modification: March 31, 2021
Accepted: April 13, 2021

***Correspondence to**:
Marvin do Nascimento
Address: Rua Professor Rodolpho Paulo Rocco, 325 - Ilha do Fundão, Rio de Janeiro, RJ, Brazil.
Telephone number: +55 (21) 9 6642-8431
E-mail: mvnascimento@hotmail.com.br

INTRODUCTION

Oral Health (OH) is governed by an extensive and diverse oral microbiota, and alterations in this composition are associated with dysbiosis process and oral infections development[1] such as Caries and Periodontal Disease (PD), which are polymicrobial and multifactorial processes that may compromise the integrity of the teeth, as well as oral and systemic health.[2] Among the risk factors for Caries and PD, malnutrition stood out as one of the most influential factors.[3]

Moreover, one of the factors that should be considered in this perspective is the Nutritional Health (NH). The NH requires the adequate supply of macronutrients and micronutrients in cells and organisms for systemic health homeostasis. Thus, there are strong associations, with many interrelating factors of NH, OH and systemic health conditions in a bidirectional relationship.[4,5]

Due to the treatment's difficulty and the antimicrobial resistance, probiotic and prebiotic nutritional therapy has been adopted as adjunctive resource to non-surgical oral infections treatment.[6] Probiotics and Prebiotics are, respectively, live microorganisms and nondigestible food components that affect beneficially the microbiota, modulating it and selectively stimulating bacterial species.[7,8] Therefore, the aim of this review is to evidence the nutritional influence on the oral microbiota modulation affecting, in the long-term, the gut microbiota, highlighting the use of probiotics and prebiotics in the treatment of oral infections.

Oral-gut microbiota interaction: the role of oral health in systemic health

The oral cavity has many sites, each one of them coated with a saliva pellicle and bacterial biofilms. Some of these bacteria have been implicated in oral diseases such as caries and periodontitis, that are among the most common bacterial infections in humans. Within the oral cavity, there are distinct microenvironments colonized by microorganisms that may have genetic and physiologically evolved to tolerate it.[9] A successful bacterium is the one who survived the harmful environment in the oral cavity and that specifically adhered to a surface. More than 700 species were detected in the oral cavity, however almost 50% are uncultivable species. They are constantly making interactions, including substrate supply for site attachment and colonization, nutritional cross feeding, and the coordinated metabolism of complex substrates, sustaining the polymicrobial synergy concept.[2]

The Gastrointestinal Tract (GI tract) is the most densely colonized human organ, it harbors complex microorganisms' communities residing in or passing through the GI tract.[10,11] These microorganisms form complex interactions in the GI tract and their communities contain approximately 500-1,000 species. These species, interestingly, belong to only few numbers of bacterial phyla: Firmicutes, Bacteroidetes, Proteobacteria, Verromicrobia, Actinobacteria, Fusobacteria and Cyanobacteria.[12] Each microbe participates in many physiological processes, such as improvement of gut mucosal immunity, uptake and production of essential nutrients, maturation and maintenance of the GI sensory and motoric functions and defense against pathogens by antimicrobial compounds production. These defenses are mostly promoted due to the intestinal barrier integrity, constituted of an epithelium arranged in villus and the submucosal tissue with immune functions. The pathogens developed many attributes that allow them to damage and break this barrier, which gives access to the bloodstream and, consequently, other tissues and organs, ending in the putative participation of intestinal pathogens in the systemic disease's pathogenesis.[13,14]

Given the scientific evidences of oral bacteria presence in extra-oral sites in disease conditions, many authors hypothesized the plausibility of an oral-gut axis in these cases.[10,15,16] By swallowing an oral pathogen, its presence in gut microenvironment causes homeostasis disturbance, a situation called dysbiosis.[17] Dysbiosis is a sufficient trigger for the intestinal barrier imbalance, raising bacteria or bacterial products to spread through the bloodstream.[18,19] The enteral route as a pathway of ectopic gut colonization by oral bacteria is supported by the amount of oral strains found in maladies and health patients stool samples, such as *Fusobacterium nucleatum*, *Porphyromonas gingivalis*, *Klebsiella* spp., *Veillonella* spp., *Prevotella* spp., *Streptococcus* spp. and *Aggregatibacter* spp.[10,20] The virulence compounds excess in the blood causes endotoxaemia and contributes to the production of acute phase proteins at the liver.[21,22] These mediators are known to act in systemic conditions, such as heart diseases, diabetes and pregnancy complications.[15,18] Besides the metastatic inflammation, the gut pathogens have the potential to stimulate T helper 1 (Th1) lymphocytes subpopulation differentiation, which has a pro-inflammatory profile.[16] Likewise, the oral inflammation per si is responsible for a huge production of pro-inflammatory cytokines and its presence in plasma also affects health homeostasis. Proinflammatory mediators, such as IL1â, IL6, TNFá and PGE_2, produced locally in the inflamed gingival tissues may "spill" into the circulation and have systemic impact, such as induction of endothelial dysfunction.[23] Oral bacteria, disseminated from periodontal, endodontic or mucosal lesions, can survive in the bloodstream and may adhere at nonoral body sites. Since the gut microbiota and oral microbiota directly or indirectly influence the evocation of systemic diseases, may the use of probiotics protect intestinal barrier damage and prevent bacteria to spread through the bloodstream, avoiding systemic complications. Therefore, the gut microbiota modulation can cause oral health and vice-versa.[24]

Caries: Cariogenic Biofilm Specificity and Risk Factors

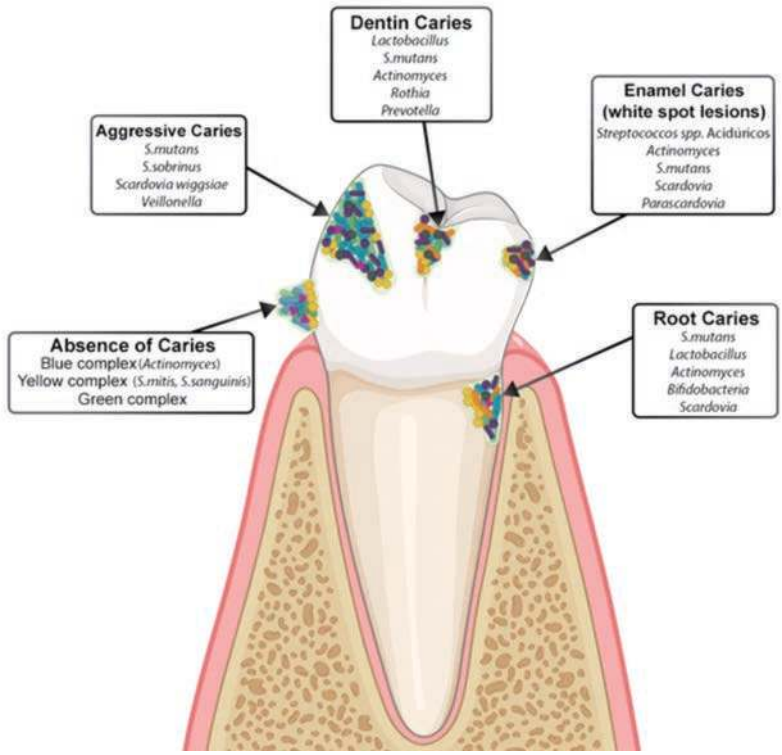

***Figure 1**: Biofilm Relationship in types of Dental Caries in a Symbiotic and Dysbiotic state. Incorporating concepts of Takahashi and Nyvad (2016); created with Biorender (2020). Source: Nascimento's personal* archive.

Caries is a multifactorial disease, modulated by a dysbiotic and sugar-dependent process that promotes teeth demineralization and destruction, and may also cause endodontic complications or to dental element loss (Figure 1).[2,25,26,27] This is a progressive and transmissible infection characterized by mineral teeth loss due to long exposure to acidic *pH* due to the oral bacterial metabolization dietary carbohydrates. This dysbiosis begins due to a deregulation of the homeostasis of the oral microbiota favoring aciduric and acidogenic microorganisms.[28,29]

Cariogenic Biofilm (CB) is composed by acidogenic and acid-tolerant species and classified in streptococcal and non-streptococcal species. The first group is formed mainly of *Streptococcus* spp., especially *S. mutans* and *S. sobrinus*, and the second presents itself with the participation of *Lactobacillus* spp., *Bifidobacterium* spp., *Scardovia* spp., *Actinomyces* spp., *Veillonella* spp., as well as fungi (for example the *Candida albicans*, which has a coaggregation with *S. mutans* in the presence of sucrose, in which there is a beneficial bidirectional action between its virulence factors and biochemical characteristics favoring both species). Gram-negative anaerobic species such as *Prevotella* spp., *Porphyromonas* spp. and *Selenomonas* spp. have been associated with deep caries lesions in dentin. These species interact in a dynamic microbial synergistic relationship within the biofilm.[30,31,32]

The diet factor is important to be considered because the high carbohydrates intake influences the biofilms formation. The fermentation of food carbohydrates, mainly sucrose, favors the glycosyltransferases production to catalyze the synthesis of extracellular polysaccharides and acid metabolites, selecting the predominance of acidic and acidogenic species. What results in a CB with pathogens capable of producing acids that demineralize teeth enamel.[33,34]

Although there are several biological risk factors that directly influence caries, the relationship of how the diet affects the oral microbiota and the composition of dental biofilm plays a critical role in this infection development.[35,36]

Periodontal disease: periodontopathogenic biofilm specificity and risk factors

Periodontal Disease (PD) is a multifactorial disease, modulated by a dysbiotic and an inflammatory process that directly affects the teeth supporting tissues and is the second cause of teeth loss in the world with prevalence in up to 70% of the population.[27]

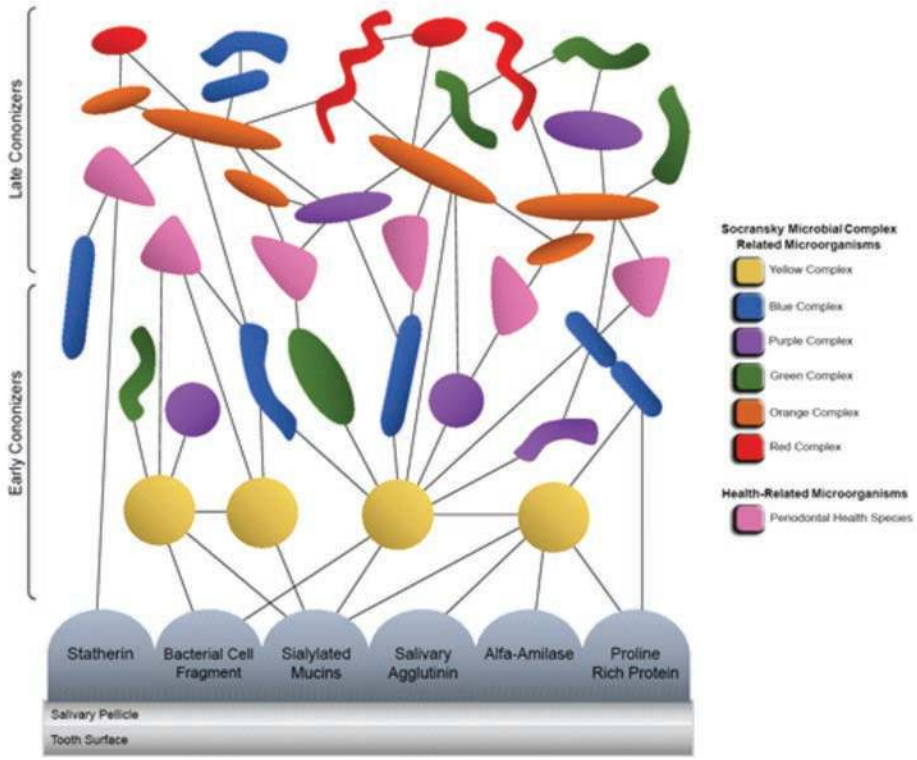

***Figure 2**: Symbiotic Supragingival Biofilm Scheme. Incorporating concepts of Socransky Microbial Complex (1988), Kolenbrander and collaborators (2010) and Colombo & Tanner (2019). Source: Nascimento's personal archive.*

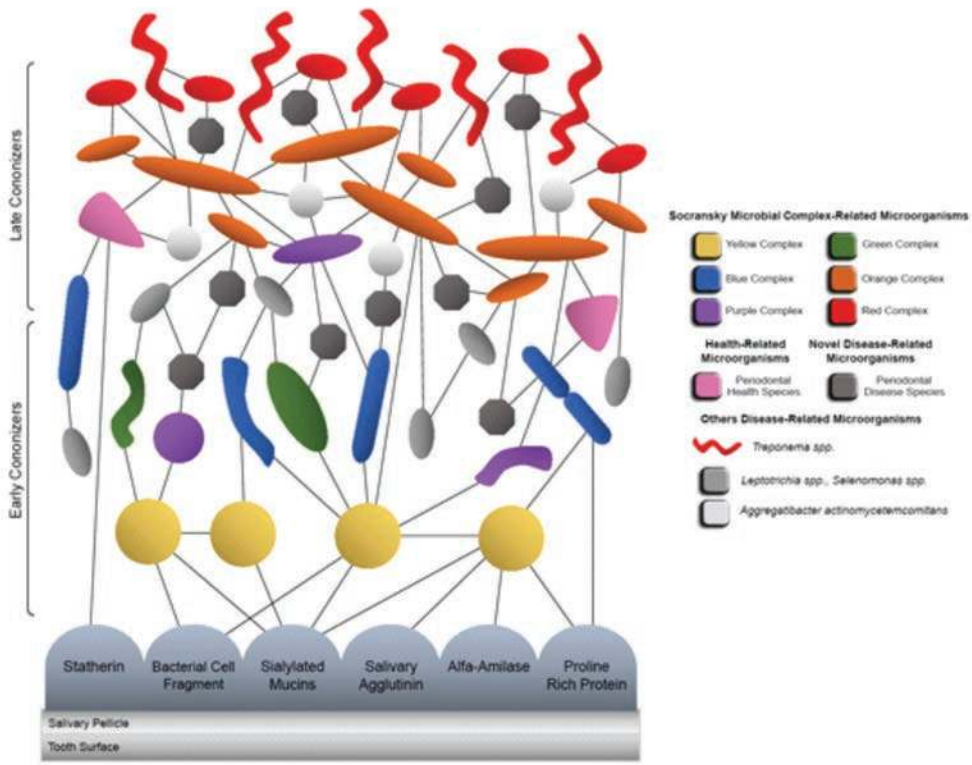

***Figure 3**: Dysbiotic Subgingival Biofilm Scheme.* Incorporating concepts of Socransky Microbial Complex (1988), Kolenbrander and collaborators (2010) and Colombo & Tanner (2019). Source: Nascimento's personal archive.

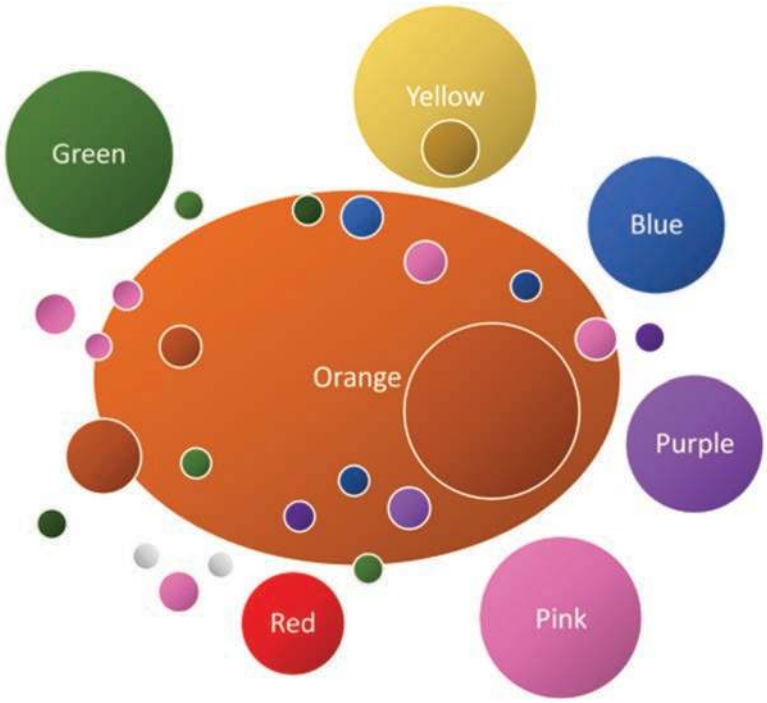

***Figure 4**: Socransky Microbial Complex. Microbial Complex established by Socransky and collaborators (1988) adapted with concepts by Colombo & Tanner (2019). Source: Nascimento's personal archive.*

Periodontal biofilm is a non-randomly organized microbial community adhered to the tooth surface under the gingival line involved in a glycoprotein matrix and composed by true periodontal pathogens and health-related microorganisms (Figure 2).[37] The progress of the disease's onset, the oral microbiome virulence begins to increase and the host resistance decrease, which is where opportunistic pathogens and disease-related microorganisms will give specificity to a Periodontopathogenic Biofilm (PPB) resulting in a dysbiosis process of oral microbiota, eventual teeth loss and can also affect the systemic health. The PPB itself acts as a virulence factor generating harmful bacteriocins and designating greater resistance to them (Figure 3).[38]

There is a high diversity in the PPB, which is composed predominantly of gram-negative, proteolytic and anaerobic bacteria.[39] In disease state, there is a red complex prevalence (*Porphyromonas gingivalis, Tannerella forsythia, Treponema denticola*), as well as the orange complex, as described by Socransky (1998) (Figure 4), and other medical importance bacteria that act as opportunists in the middle of the dysbiotic process generated by PD. Periodontal biofilm has its own life activity, a biofilm lifestyle. There are specific interactions between microorganisms within the biofilm, based on shared characteristics and symbiosis relationships. Thus, the interaction between microorganisms in the periodontal biofilm functions as a symbiotic feedback mechanism among species.[40,41,42,43] For example, the symbiotic relationship between *T. denticola* and *P.gingivali*s. The first one ferments the amino acids from the subgingival biofilm and produces succinate (used to coagulate the surface by *P. gingivalis*), while the second produces some fatty acids that favor the proliferation of *T. denticola.*[44]

Furthermore, the absence of oral biofilm control causes changes in the oral microbiota favoring pathogenic complexity, since PD has a biofilm-dependent load and maturity correlation. Thus, the pathogenic microbiota and PD mediators of chronic inflammation contribute to the development or continuity of chronic inflammatory diseases in a bidirectional relationship.[45] Although, there are risk factors that aggravate PD, such as smoking, type 2 diabetes, bad habits of oral hygiene, high consumption of alcoholic beverages, obesity, psychosocial factors and high blood pressure.[46] In addition to these risk factors, malnutrition can stand out as an influential factor that can influence the oral microbiota.[3]

Nutritional health: influence and impact of macro and micronutrients in oral-systemic health perspective

Nutrition is considered one of the main pillars for human development, based on the food-body relationship. The nutritional status is directly associated with the adequate supply of macronutrients (carbohydrates, fats and proteins) (Table 1) and micronutrients (vitamins, minerals and others), especially for the proper functioning of cells and the systems'

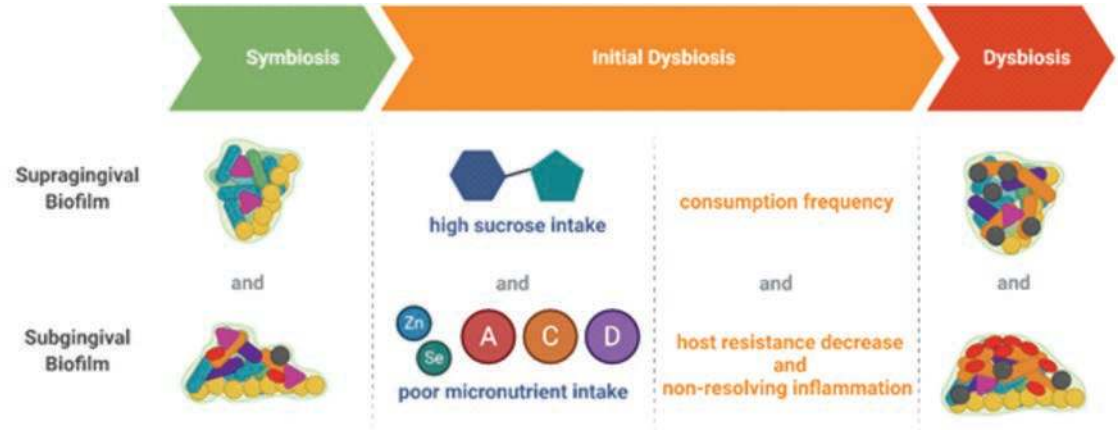

***Figure 5**: Nutritional Influence on Supragingival and Subgingival Biofilm.* The supragingival biofilm in Symbiosis is in homeostasis. In Initial Dysbiosis begins the dysbiotic state due to high sucrose intake and high frequency of consumption (time factor), thus not allowing pH buffering. In Dysbiosis, the characterization of the cariogenic biofilm already exists. The subgingival biofilm in Symbiosis is compatible with periodontal health. In Initial Dysbiosis due to the influence of poor micronutrient intake, the immune system and the host's responses are compromised generating a destructive inflammatory response induction. In dysbiosis there is already a characterization of periodontopathogenic biofilm; created with Biorender (2020). Source: Nascimento's personal archive.

homeostasis. According to the World Health Organization (WHO): "Nutrition is the science of food and its relationship to health" and "Malnutrition is the cellular imbalance between the supply of the nutrients and the energy and the body's demand for them to ensure growth, maintenance, and specific functions". There is a strong association between the role of nutrition and OH conditions with many interrelating factors. Furthermore, understanding the main aspects of nutrition is essential for an individual's health.[4,47,48]

The systemic nutritional factors have an important OH impact, especially during the period of tooth development, it affects cellular metabolism, protein synthesis, and other biochemical processes like calcification. For instance, proteins are an essential macronutrient, and they are important to the body throughout life, as it secures muscle and bone metabolism, ensures the maintenance and development of a normal nervous system, and helps to sustain muscle mass and physical performance in older ages, for instance. In addition, carbohydrates are considered organic compounds whose main function is to provide energy supplies for the body; fats are components of adipose tissue, cholesterol, hormones, nervous tissue, cellular components (phospholipids) and other structures. Imbalance on these macronutrients or micronutrients status may interfere in OH conditions and lead to oral diseases development.[49,50,51]

The relationship between nutrition and OH has been discussed in many studies. Diet is considered one of the risk factors for caries and enamel erosion, also nutritional imbalance impacts on teeth development and the host's resistance to many oral conditions, such as PD. Furthermore, these aspects play essential roles in the OH, in the integrity of the gum and mucous membrane, in the strength of the bones as well as in the oral infections' treatment. Therefore, NH may affect the development and maintenance of the oral and dental tissues. As we have seen, diet can intervene the tooth integrity; the type, shape and frequency of foods and drinks consumed affect, directly, the oral *pH* and microbial activity, which can promote dental caries (Figure 5).[5,59,67]

Nutrition and diet are associated with the oral cavity's integrity, also nutrition imbalance may lead to disease progression in the OH, reduce resistance to oral bacteria and prevents tissue healing and it may directly affect its development on early life (Table 2).[68,69]

The periodontal defenses are influenced by proper functioning of the host's humoral and cellular immune system, the phagocytic system and the integrity of the oral mucosa. The crevicular and junctional epithelium build an epithelial barrier function and it provides a major defensive barrier against invasion by antigens, pathogens or noxious products. It undergoes a rapid turnover and is therefore dependent of good nutritional status. In addition, systemic factors associated with the PD initiation or progressions include diabetes mellitus, osteoporosis and osteopenia, stress and inadequate coping, and the periodontal pathogens presence in the subgingival microbiota.[72,73,74]

Moreover, the pro resolving lipid mediators, resolvins and protectins with anti-inflammatory and immunoregulatory actions are biosynthesizes from metabolism of ù-3, through cessation of proinflammatory cytokines production and regulating the recruitment of inflammatory cells to the inflammation sites, thus enhancing clearance of inflammation within the lesion to promote tissue regeneration. However, a recent research showed a broad range of antibacterial activity for both Eicosapentaenoic Acid (EPA) and Docosahexaenoic Acid (DHA), including the inhibition of putative periodontal pathogens, such as red and orange complex. As well as futures therapies with long chain ù-3 PUFAs may therefore combine periodontitis treatment with an anti-inflammatory and antimicrobial approach.[75,76]

***Table 1**: Macronutrients and Oral and Systemic Relationship.*

Macronutrient	Oral and Systemic Impact	References
Carbohydrates	Some studies have been suggesting that diets high in refined carbohydrates trigger a hyperinflammatory state evidenced in caries and PD. Also, sugars and other fermentable carbohydrates are metabolized to bacterial biofilm acids, resulting in low pH and it is favoring the growth of the acidogenic and aciduric species. Hence, the dynamic enamel mineral loss is initiated for acid produced CB metabolizing fermentable carbohydrates, so they may interfere in the demineralization-remineralization process. Besides that, carbohydrate consumption or biofilm accumulation can perturbate the oral microbiota and lead to the oral infection's development. In contrast, a diet rich in complex carbohydrates and soluble fibers may reduce the risk of periodontitis and disease progression, especially among older adults. Also, they are associated with greater insulin sensitivity and lower risk of diabetes and metabolic syndrome. In fact, this relationship is important, especially because some studies showed the relation between periodontitis and hyperglycemic state, also the association between dietary fiber intake and periodontal health.	**Salazar et al., (2018)[52]; Bernabé et al., (2016)[53]; Zhan (2018)[54]; Nielsen et al., (2016)[55]; Laiola et al., (2020)[56]**
Fats	There are two major families of Polyunsaturated Fatty Acids (PUFAs) and they are involved in the inflammatory process. In addition, omega-3 (ù-3) derived mediators might lead anti-inflammation effect, while most of omega-6 (ù-6) derived mediators aggravate inflammation, these effects may affect directly if in a balanced diet. Western diets are typically ù-6 rich (soy, cereals, sunflower oil, and animal products) and present low sources of the ù-3 fatty acids, consequentially, they promote low concentrations of ù-3 PUFAs through conversion to arachidonic acid in our body. Moreover, ù-3 fatty acids include á-Linolenic Acid (ALA), Eicosapentaenoic Acid (EPA) and Docosahexaenoic Acid (DHA) that are in high concentrations especially in fish oil, linseed, and walnut oil. The EPA and DHA serve as important precursors for gene expression, inflammatory processes and lipid-derived modulators of cell signaling. Also, the synthesis of ù-3 polyunsaturated fatty acids in humans is limited and it is considering an essential dietary component.	**Calder, (2017)[57]; Azzi et al., (2018)[58]; Kruse et al., (2020)[59]; Iwasaki et al., (2011)[60];Dawson et al., (2014)[61]**
Proteins	Disorders in protein metabolism can affect the matrix formation of both enamel and dentin in the developing tooth as well as formation of the intercellular matrix of the fibrous periodontal ligament, alveolar bone, and cementum. Proteins have an important effect on satiety and reduce simple carbohydrates consumption such as sugar, e.g. Also, studies have showed association between dental caries and dietary habits, especially high consumption of these types of carbohydrate. Alterations in dietary protein intake may impact muscle and whole-body protein balance, negatively impacting muscle mass maintenance, and its function. Moreover, obesity and overweight conditions directly affect body-composition, especially contributing to the increase of adipose tissue and consequently reduction of muscle mass. Therefore, these conditions promote a disbalance on inflammatory state (pro-inflammatory cytokines) and an increase of oxidative stress by adipose tissue, and associate with PD, this inflammation may increase gingival inflammation and promote bacterial proliferation on the tooth's root surface. Some studies reported the beneficial effects of dietary protein on glycemic control. This relation may assume an important role in PD, and also influence the systemic inflammation.	**Carbone et al., (2019)[62]; Drummen et al., (2018)[63]; Hopkins et al. (2016)[64]; Martines Herrera et al., (2017)[65]; Khan et al., (2018)[66]**

***Table 2**: Micronutrients and Oral and Systemic Relationship.*

Macronutrient	Oral and Systemic Impact	References
Vitamins and Minerals	Vitamins are catalysts for all metabolic reactions, using macronutrients for energy, growth and cell maintenance. They also function as electron donors, antioxidants, and transcription effectors. Vitamins are categorized into 2 major groups: fat-soluble (A, D, E and K) and water-soluble (B-complex and vitamin C). Minerals serve as structural or catalytic components of enzymes and regulate cellular energy transduction, gas transport, antioxidant defense, membrane receptor functions, second-messenger systems, and integration of physiologic systems. Minerals can be classified as either major minerals (>100 mg/day) or trace elements (<100 mg/day). The major minerals are sodium, potassium, calcium, magnesium, phosphorus and sulfur. The trace minerals are: iron, zinc, iodine, selenium, fluoride, copper, cobalt, chromium, manganese and molybdenum. Thus, a fast-immune response, especially in the case of inflammatory process, present in some oral infections like gingivitis and periodontitis, may be limited with insufficiency of nutrients, i.e., malnutrition. This condition may influence the immune system's function, especially on innate and adaptive defenses of the host, including cell mediated immunity, phagocytic function, secretory antibodies, complement system, and cytokines action. it can intensify the severity oral infections and lead to their evolution of many diseases. As well as impacts on OH may affect daily dietary intake, which consequently degrades the nutritional balance and general health. Furthermore, it has a negative impact especially on the quality of life since the diet influences the individual's food choices.	**Shay et al., (2019)[68]; Cagetti et al., (2020)[69]; Uwitonze et al., (2016)[70]; Badrasawi et al., (2020)[71]; Hujoel et al., (2017)[72]**

Functional role of probiotics and prebiotics in oral and systemic health

"Probiotics are live microorganisms that, when administered in adequate amounts, confer a health benefit on the host".[77] There are numbers of probiotic characteristics that can promote OH. We hypothesize that oral probiotic may compete for nutrients and/or buffer the oral *pH* towards a more neutral *pH*, reducing the numbers of opportunistic pathogens, may limit the dental biofilm progression by bacterial co-aggregation and by the antibacterial substances production, such as bacteriocins and nitric oxide. It is also possible the adherence to the oral surfaces, outcompeting pathogen adhesion and proliferation.[1]

When ingested, probiotics reach the GI tract and exert many effects, such as modifying the gut microbiota, improving the intestinal barrier function and the immunity, resulting in systemic benefits. Probiotics have been intensively studied due to their amount of benefits on many human and animal diseases, participating in the treatment scheme for acute infectious diarrhea, Irritable Bowel Syndrome, Ulcerative colitis, Crohn's disease, atopic dermatitis and psoriasis.[78,79]

Commercial probiotics are, generally, presented as fermented foods, such as milks, yogurts and cheese. They can be classified in the functional foods group, particularly in the division of the Dairy Products. Functional foods are those that when consumed regularly exert a specific health-beneficial effect beyond their nutritional properties, and this effect must be scientifically proven. Functional foods are similar to conventional foods, which are consumed as part of a usual diet but are known to improve health status beyond primary nutritional function.[80]. The Functional foods provide ways to reduce the increasing burden on the health care system by continuous preventive mechanisms, including about OH, coupled with public interest and consumer demand.

The major microbe groups present in probiotics include the Lactic Acid Bacteria (LAB), *Bifidobacterium*, the yeast *Sacharomyces cerevisae*, *Bacillus* spp. and a strain of *Escherichia coli.*[81] The LAB group's composition accomplishes *Lactococcus*, *Enterococcus*, *Oenococcus*, *Pediococcus*, *Streptococcus*, *Leuconostoc* and *Lactobacillus* species.[82] Typically, LAB are found as dominant organisms in many spontaneous fermentations of food and feed.[83]

The capacity to adhere and colonize the oral surfaces

is a crucial condition for a microorganism to be elected as a great probiotic for OH. The main microbial groups used as oral probiotics include the genus *Lactobacillus*, *Bifidobacterium*, *Lactococcus* and *Streptococcus*. An important issue found among the studies is that the probiotic that has effect is strain-specific and disease-specific efficacy, which means that a bacterial specie known as a pathogen member can be a good strain having a probiotic effect probiotic effect on a given disease.[84] *Escherichia coli* is an example, commonly regarding a gut microbiome member and pathogen, but studies showed the probiotic effect of the Nissle strain 1917, which colonizes the mammalian gut.[85]

The use of probiotics in dentistry for oral therapy has become increasingly frequent and aim to reestablish the biofilm equilibrium, which acts as a cascade trigger events that constitute the oral diseases spectrum. The following mechanisms of probiotics action in the oral cavity are: direct interaction with dental biofilm, oral microorganisms binding to product proteins and intervention/competition in bacterial adherence and ecology plaque formation.[86,87]

Corroborating the inhibitory probiotics effect against oral pathogens, Shin, Baek and Lee (2018) demonstrated that *Lactococcus lactis* has antimicrobial activity against periodontopathogens, such as *F. nucleatum*, *P. gingivalis, T. forsythia* and *T. denticola* using the culture supernatant as well as performing co-cultivation. In addition, neutralizing activity on the production of volatile sulfur compounds was observed, as well as a reduction in the pro-inflammatory cytokines production from cells challenged with LPS of these pathogens.[88] Chen (2020) also showed the antibacterial activity of viable and heat-killed probiotic strains (*Lactobacillus salivarius* subsp. salicinius AP-32, L. *rhamnosus* CT-53, L. *paracasei* ET-66 and *Bifidobacterium animalis* subsp. lactis CP-9) against oral pathogens, such as *Streptococcus mutans, Porphyromonas gingivalis, Fusobacterium nucleatum* and *Aggregatibacter actinomycetemcomitans.*[89]

Studies about prebiotics are extremely recent yet, and also, it's exact role in the microbiome balance improvement in the human body is still unknown. However, some researches have been demonstrated to be already an aid to complement prebiotics in the oral disease's treatment. Currently, the term prebiotic is defined as "selectively fermented ingredients that allow specific changes, both in the composition and/or activity in the gut microbiota, that confer benefits upon the host well-being and health". Moreover, the resistant Oligosaccharides-Fructo-Oligosaccharides (FOS) and Galacto-Oligosaccharides (GOS) are considered nondigestible carbohydrates, two existing prebiotic dietary fiber types. Prebiotics could stimulate the beneficial bacteria growth and suppress the pathogens growth in the gut microbiota. Also, they could improve the mucosal barrier function, enhance the production of Short-Chain Fatty Acid (SCFAs) and influence the host's immunity. For this reason, probiotics and prebiotics may be considered an important strategy, especially because they can reestablish the ecological balance regaining the intestinal and oral microbiota biodiversity in the early stages. This maintenance also contributes to reduce levels of inflammatory mediators and the host's immune responses.[8,90,91]

The nutrition impact on the oral microbiota modulation

In addition to other risk factors for Caries and PD, NH has an influence in modulating the oral microbiota's composition and function, as well as OH, acting as a perspective not only of treatment, but as a preventive role maintaining microbiome homeostasis. In this sense, the use of probiotics and prebiotics nutrition therapy has been shown to be very effective in the treatment of these oral infections as opposed to the antimicrobials use. To support this concept, this review determined the impact of nutrients on oral and systemic health and it was observed that there is a pre-existing bidirectional relationship between the oral-systemic axis. And, although all nutrients have their importance and specific effects for OH homeostasis, micronutrients proved to be of greater relevance.

Colombo and Tanner[27] showed that dental biofilm assumes a very influential role in the oral infections' etiopathogenesis. Oral diseases, such as Caries and PD, should not be seen as caused by one or some true pathogens as described in classical infections, but as a polymicrobial holistic community that has the potential to trigger dysbiosis of microbial community, due to changes in complexes mechanisms between microbiota-environment-host.

Some studies have raised the hypothesis that dysbiotic oral microbiota may disturb the gut microbiota at the long-term period. The high ingestion of oral pathogens may induce a dysbiotic process in the gut microbiota and a systemic inflammation state, endotoxemia, insulin resistance, high dysfunction of glucose levels and a hypofunction of the intestinal barrier. In contrast, the disturbed gut microbiota is able to modulate the severity and frequency of oral infections.[51,92,93]

About the association between OH and NH, Hugar[94] demonstrated an association between deficiencies or inadequate micronutrient intake with the increase susceptibility to caries and DP. Bhargava[95] declares that vitamin D plays a crucial role in bone maintenance and immunity, and the imbalance of its status in the body can induce dentin and enamel defects during tooth development

and it could negatively affect the periodontium. Adegboye[5] declares that malnutrition can elicit adverse alterations in volume, physiochemical and antibacterial properties, which may have consequences on the *pH* and oral microbiome. In summary, this synergy between nutritional status, OH and dietary practices combined with removal of the inflammatory periodontal stimuli is important to diminish the severity of PD. Also, Shay[68] showed that the nutritional status has a direct influence on the immune system. In turn, it affects the innate, adaptive and cellular immune responses, especially the protection against host invasion by microorganisms and inflammatory response. Undernutrition and nutrient deficiency suppress immune functions, compromising the synthesis and the release of cytokines and their action. Consequently, when associated with increased needs for calories, protein and micronutrients promote repletion, that replicates immune cells, balance of antioxidant and oxidants agents, wound healing, and an improved immune response (Figure 5).

Another important role of nutrients in the host are the benefits of ù-3 fatty acids in inflammatory response. However, researches about the cellular and molecular mechanisms underlying their host modulatory action with use of long chain ù-3 fatty acids are still largely unknown in various systemic diseases.[96] The majority of PUFAs from dietary are usually used to construct phospholipids present in cell membranes, and they act as precursors for lipid mediators involved in cell signaling and contribute to the cell's membrane integrity and fluidity. Omega fatty acids are the PUFAs, and they had three major types of ù-3 derived from food and used by our body, especially, EPA acid and DHA.

Zohoori & Duckworth[97] points another relevant aspect, vitamins are essential organic compounds and biologically active constituents of a diet. Also, they are catalysts for the body's metabolic reactions; they also function as electron donors, antioxidants, and transcription effectors. The absence or scarcity of certain vitamins has been implicated as being etiological factor in the PD's pathogenesis. Tada & Miura[98] have shown that vitamin C deficiency may result in lack of collagen formation by affecting hydroxylation of proline and increased permeability of endotoxin from the oral mucosa. Also, this vitamin has an antioxidant potential in the body's defense system, it is directly neutralizing free radicals, scavenging the hydroxyl radicals which mediate tissue damage, and suppressing macrophage secretion of superoxide anions. As a result of this, vitamin C can be considered an important nutrient present on the dietŻ for periodontal health, and it has capacity to control excessive Reactive Oxygen Species (ROS) produced in oral infections.

Following this line, the probiotic and prebiotic supplementation can influence and play an important role in the oral infection's treatment and prevention. Corroborating the inhibitory effect of probiotics against oral pathogens, Dassi[99] showed that the saliva microbiome enhanced its diversity after probiotic intake, and the principal effect of probiotic bacteria to reduce the caries risk is inhibition of CB formation by killing the pathogens (bacteriocins, growth inhibition) or avoiding their co-aggegation. Given the dysbiotic biofilm nature of the dental caries, the inhibition of a single pathogen makes little sense, so a great probiotic essentially needs to act on different members of an oral community.

Hedayati-Hajikand[100] study evaluated the effect of probiotic chewing tablets on early childhood caries development in preschool children living in a low socioeconomic multicultural area. They concluded that caries development could be reduced through administration of these probiotic chewing tablets as adjunct to daily use of fluoride toothpaste. Short-term consumption of *Lactobacillus rhamnosus* GG, *Limosilactobacillus reuteri*, and *Bifidobacterium lactis* BB-12 have reduced counts of *S. mutans*, the major caries pathogen.[101] More trials are needed to gain better knowledge of probiotic supplements and to confirm that their use is beneficial and cost-effective in caries care.

Esteban-Fernández[102] published their results about the beneficial effects of *Streptococcus dentisani* as potential oral probiotic for PD. This specie was found at high levels in the gingival crevice, inhibiting the periodontal pathogens by competition, adherence and displacement mechanisms. Besides that, the oral probiotic increased the secretion of the anti-inflammatory cytokine IL-10 after incubations with oral pathogens in a simple *in vitro* model. Another specie showed probiotic effect: Garcia[103] presented *Saccharomyces cerevisae* as a monotherapy and as an adjuvant to the mechanical treatment of experimental periodontitis in rats and it showed positive effects. Theodoro et al[104] evaluated the effect of *Lactobacillus reuteri* in chewable tablets as an adjunct to non-surgical periodontal treatment of chronic periodontitis in smoking patients. The adjuvant use of *L. reuteri* in the treatment of chronic periodontitis was effective in controlling gingival inflammation because it reduced bleeding on probing, which means it reduced gingival inflammation and was effective in reducing deep pocket in a clinically relevant manner.

Shin et al[88] demonstrated that *Lactococcus lactis* has antimicrobial activity against periodontopathogens, such as *F. nucleatum, P. gingivalis, T. forsythia and T. denticola* using the culture supernatant as well as performing co-cultivation. In addition, neutralizing activity on the production of volatile sulfur compounds was observed, as well as a reduction in the pro-inflammatory cytokines production from cells challenged

with LPS of these pathogens. Chen[89] also showed the antibacterial activity of viable and heat-killed probiotic strains (*Lactobacillus salivarius* subsp. salicinius AP-32, *L. rhamnosus* CT-53, *L. paracasei* ET-66 and *Bifidobacterium animalis* subsp. lactis CP-9) against oral pathogens, such as *Streptococcus mutans, Porphyromonas gingivalis, Fusobacterium nucleatum* and *Aggregatibacter actinomycetemcomitans.*

Nevertheless, Almoznino[105] evidences nutritional imbalance effect on cellular and molecular levels, oral biofilms, tissue metabolism and immune response, suggesting that nutrition has the potential to affect biological gradient and thus affect periodontal infections. Accordingly, PD develops faster in undernourished populations. Food intake is not a treatment for oral and dental infection, but depleted nutrition can negatively impact tissue integrity, mineralization, progressive damage to mucosa, as well as a diminished resistance to colonization and invasion by pathogens and other aspects that had been previously described.

CONCLUSION

This study concluded that malnutrition is an important risk factor to be considered in the oral infection's treatment and that it should receive more attention by the Dentist. The macronutrients and micronutrients' frequency of ingestion is able to modulate the oral microbiota and impact OH. The preventive character is more resolutive and effective than during the treatment itself. NH is much more than just "dieting" and plays a key role in OH. In addition, supplementation with probiotics and prebiotics for the nutrition treatment of Caries and DP is shown with very satisfactory research that increasingly directs this treatment. However, more studies need to be done to better understand the nutrition and oral microbiota subject. Furthermore, it is up to the Dentist to allow itself a holistic look, to study to the point of knowing what to ask the patient about NH, to think how far it can go and to know when it is time to refer to a Nutritionist or even make a joint multidisciplinary treatment.

REFERENCES

1. Saha S, Tomaro-Duchesneau C, Rodes L, Malhotra M, Tabrizian M, Prakash S. Investigation of probiotic bacteria as dental caries and periodontal disease biotherapeutics. Beneficial Microbes. 2014;5(4),447–60. doi: 10.3920/bm2014.0011.
2.Lamont RJ, Koo H, Hajishengallis G. The oral microbiota: dynamic communities and host interactions. Nat Rev Microbiol. 2018;16(12):745-759. doi: 10.1038/s41579-018-0089-x.
3. Luo PP, Xu HS, Chen YW, Wu SP. Periodontal disease severity is associated with micronutrient intake. Australian Dental Journal. 2018;63(2),193–01. doi: 10.1111/adj.12606.
4. Gondivkar SM, Gadbail AR, Gondivkar RS, Sarode SC, Sarode GS, Patil S, et al. Nutrition and oral health. Disease-a-Month. 2019;v.65, n.6, p. 147–154. doi: 10.1016/j.disamonth.2018.09.009.
5. Adegboye AR, Boucher BJ, Kongstad J, Fiehn NE, Christensen LB, Heitmann BL. Calcium, Vitamin D, casein and whey protein intakes and periodontitis among Danish adults. Public Health Nutrition. 2015;v.19, n.3, p.503–510. doi: 10.1017/S1368980015001202.
6. Matsubara VH, Bandara HMHN, Ishikawa KH, Mayer MPA, Samaranayake LP. The role of probiotic bacteria in managing periodontal disease: a systematic review. Expert Review of Anti-Infective Therapy. 2016;14(7),643–55. doi: 10.1080/14787210.2016.1194198.
7. Gruner D, Paris S, Schwendicke F. Probiotics for managing caries and periodontitis: Systematic review and meta-analysis. Journal of Dentistry. 2016;48, 16–25. doi: 10.1016/j.jdent.2016.03.002.
8. Hijová E, Bertková I, Stofilov J. Dietary fibre as prebiotics in nutrition. Central European Journal of Public Health. 2019;27,n.3,p.251–255. doi: 10.21101/cejph.a5313
9. Tordesillas L, Berin MC. Mechanisms of oral tolerance. Clinical reviews in allergy & immunology, 2018, 55(2), 107-117.
10. Schmidt TS, Hayward MR, Coelho LP, Li SS, Costea PI, Voigt AY, et al. Extensive transmission of microbes along the gastrointestinal tract. Elife, 2019, 8, e42693.
11. Gerritsen J, Smidt H, Rijkers GT, de Vos WM. Intestinal microbiota in human health and disease: the impact of probiotics. Genes Nutr. 2011;6, 209–240. doi: 10.1007/s12263-011-0229-7.
12. Sommer F, Bäckhed F. The gut microbiota - masters of host development and physiology. Nature Reviews Microbiology. 2013;11,227–238. doi: 10.1038/nrmicro2974.
13. Ventura M, Milani C, Lugli GA, van Sinderen D. Health benefits conferred by the human gut microbiota during infancy. Microbial Biotechnology. 2018. doi: 10.1111/1751-7915.13334.
14. Brown EM, Sadarangani M, Finlay BB. The role of the immune system in governing host-microbe interactions in the intestine. Nature Immunology. 2013;14, 660–667. doi: 10.1038/ni.261.
15. Hajishengallis G. Periodontitis: from microbial immune subversion to systemic inflammation. Nature Reviews Immunology. 2015;15(1),30–44. doi: 10.1038/nri3785.
16. Cao X. Intestinal inflammation induced by oral bacteria. Science. 2017;358(6361), 308–309. doi: 10.1126/science.aap9298.
17. Carding S, Verbeke K, Vipond DT, Corfe BM, Owen LJ. Dysbiosis of the gut microbiota in disease. Microbial Ecology in Health & Disease. 2015, 26(0). doi: 10.3402/mehd.v26.26191.
18. Pham TA, Lawley TD. Emerging insights on intestinal dysbiosis during bacterial infections. Curr Opin Microbiol. 2014;17(100):67-74. doi: 10.1016/j.mib.2013.12.002
19. Tavares CO, Rost FL, Silva RBM, Dagnino AP, Adami B, Schirmer H, et al. Cross Talk between Apical Periodontitis and Metabolic Disorders: Experimental Evidence on the Role of Intestinal Adipokines and Akkermansia muciniphila. Journal of Endodontics. 2019;45,174–180. doi: 10.1016/j.joen.2018.10.013.
20. Kitamoto S, Nagao-Kitamoto H, Hein R, Schmidt TM, Kamada N. The Bacterial Connection between the Oral Cavity and the Gut Diseases. Journal of Dental Research. 2020. 0022034520924633. doi: 10.1177/0022034520924633.
21. Lavelle A, Sokol H. Gut microbiota-derived metabolites as key actors in inflammatory bowel disease. Nature Reviews Gastroenterology & Hepatology. 2020. doi: 10.1038/s41575-019-0258-z.
22. Yuzefpolskaya M, Bohn B, Nasiri M, Zuver AM, Onat DD,

Royzman EA, et al. Gut microbiota, endotoxemia, inflammation, and oxidative stress in patients with heart failure, left ventricular assist device, and transplant. The Journal of Heart and Lung Transplantation. 2020. doi: 10.1016/j.healun.2020.02.004.
23. Van Dyke TE, van Winkelhoff AJ. Infection and inflammatory mechanisms. Journal of Clinical Periodontology. 2013;40, S1–S7. Doi: 10.1111/jcpe.12088.
24. Azad MAK, Sarker M, Li T, Yin J. Probiotic Species in the Modulation of Gut Microbiota: An Overview. BioMed Research International. 2018,1–8. doi: 10.1155/2018/9478630.
25. Li J, Wu T, Peng W, Zhu Y. Effects of resveratrol on cariogenic virulence properties of Streptococcus mutans. BMC Microbiol. 2020;20(1):99. doi: 10.1186/s12866-020-01761-3.
26. Takahashi N, Nyvad B. Ecological hypothesis of dentin and root caries. Caries Res. 2016;50(4):294–303. doi: 10.1159/000447309.
27. Colombo APV, Tanner ACR. The Role of Bacterial Biofilms in Dental Caries and Periodontal and Peri-implant Diseases: A Historical Perspective. J Dent Res. 2019; Apr;98(4):373-385. Doi: 10.1177/0022034519830686.
28. Johansson I, Witkowska E, Kaveh B, Lif Holgerson P, Tanner AC. The Microbiome in Populations with a Low and High Prevalence of Caries. J Dent Res. 2016;95(1):8086. doi: 10.1177/0022034515609554.
29. Tanner ACR, Kressirer CA, Rothmiller S, Johansson I, Chalmers NI. The Caries Microbiome: Implications for Reversing Dysbiosis. Advances in Dental Research. 2018;29(1), 78–85. doi: 10.1177/0022034517736496.
30. Tanner AC, Mathney JM, Kent RL, Chalmers NI, Hughes CV, Loo CY, et al. Cultivable anaerobic microbiota of severe early childhood caries. J Clin Microbiol. 2011;49(4):14641474. doi: 10.1128/JCM.02427-10.
31. Flemming HC, Wingender J. The biofilm matrix. Nat Rev Microbiol. 2010;9: 623–633.
32. Mathur VP, Dhillon JK. Dental Caries: A Disease Which Needs Attention. The Indian Journal of Pediatrics. 2017;85(3), 202–206. doi: 10.1007/s12098-017-2381-6.
33. Esberg A, Haworth S, Hasslöf P, Lif Holgerson P, Johansson I. Oral Microbiota Profile Associates with Sugar Intake and Taste Preference Genes. Nutrients. 2020;12(3):681. doi: 10.3390/nu12030681.
34. Takahashi N, Nyvad B. The role of bacteria in the caries process: ecological perspectives. J Dent Res. 2011;90(3):294–303.
35. Tanner AC, Kressirer CA, Faller LL. Understanding caries from the oral microbiome perspective. J Calif Dent Assoc. 2016;44(7):437–446.
36. Hu J, Jiang W, Lin X, Zhu H, Zhou N, Chen Y, et al. Dental Caries Status and Caries Risk Factors in Students Ages 12-14 Years in Zhejiang, China. Med Sci Monit. 2018;24:36703678. doi: 10.12659/MSM.907325.
37. Popoviæ N, Diniæ M, Tolinaèki M, Mihajloviæ S, Terziæ-Vidojeviæ A, Bojiæ S, et al. New Insight into Biofilm Formation Ability, the Presence of Virulence Genes and Probiotic Potential of Enterococcus sp. Dairy Isolates. Frontiers in Microbiology. 2018;9. doi: 10.3389/fmicb.2018.00078.
38. Kumar S, Chandra N, Singh L, Hashmi MZ, Varma A. Biofilms in Human Diseases: Treatment and Control. 2019. doi: 10.1007/978-3-030-30757-8.
39. Colombo APV, Boches SK, Cotton SL, Goodson JM, Kent R, Socransky SS, et. al. Comparisons of subgingival microbial profiles of refractory periodontitis, severe periodontitis and periodontal health using the human oral microbe identification microarray. J Periodontol. 2009;80(9),1421-1432.
40. Colombo APV, Boches SK, Cotton SL, Goodson JM, Kent R, Haffajee AD, el. al. Impact of Periodontal Therapy on the Subgingival Microbiota of Severe Periodontitis: Comparison between Good Responders and Refractory Subjects by the Human Oral Microbe Identification Microarray (HOMIM). Journal of Periodontology. 2012;83, 1279-1287.
41. Heller D, Silva-Boghossian CM, Souto RM, Colombo AP. Subgingival microbial profiles of generalizes aggressive and chronic periodontal diseases. Arch Oral Biol. 2012;57(7), 973-980.
42. Silva-Boghossian CM, Orrico SR, Golçalves D, Correa FO, Colombo AP. Microbiological changes after periodontal therapy in diabetic patients with inadequate metabolic control. Braz Oral Res. 2014;28(1).
43. Souto R, Silva CM, Colombo APV. Prevalence of Pseudomonas aeruginosa and Acinetobacter spp. in subgingival biofilm and saliva of subjects with chronic periodontal infection. Brazilian Journal of Microbiology. 2014;45, 495-501.
44. Tan KH, Seers CA, Dashper SG, Mitchell HL, Pyke JS, Meuric V, et al. Porphyromonas gingivalis and Treponema denticola exhibit metabolic symbioses. PLOS Pathog. 2014;10:e1003955. doi: 10.1371/journal.ppat.1003955.
45. Lourenòo TB, Spencer SJ, Alm EJ, Colombo APV. Defining the gut microbiota in individuals with periodontal diseases: an exploratory study, Journal of Oral Microbiology. 2018; 10:1, 1487741, doi: 10.1080/20002297.2018.1487741.
46. Kinane DF, Stathopoulou PG, Papapanou PN. Periodontal diseases. Nature Reviews Disease Primers. 2017;3, 17038. doi: 10.1038/nrdp.2017.38.
47. Kaye EK. Nutrition, dietary guidelines and optimal periodontal health. Periodontology 2000. 2012;v.58,n.1, p.93–111. doi: 10.1111/j.1600-0757.2011.00418.x.
48. Sheetal A, Hiremath VK, Patil AG, Sajjansetty S, Kumar SR. Malnutrition and its oral outcome – A review. Journal of Clinical and Diagnostic Research. 2013;v.7,n.1,p.178–180. doi: 10.7860/JCDR/2012/5104.2702
49. Leturque A, Brot-Laroche E, Le Gall M. Carbohydrate intake. 1. ed. [s.l.] Elsevier Inc. 2012. v. 108. doi: 10.1016/B978-0-12-398397-8.00005-8.
50. Karlund A, Gómez-Gallego C, Turpeinen AM, Palo-oja, OM, El-Nezami H, Kolehmainen M. Protein supplements and their relation with nutrition, microbiota composition and health: Is more protein always better for sportspeople? Nutrients. 2019;v.11,n.4, p.1–19. doi: 10.3390/nu11040829.
51. Woelber JP, Tennert C. Chapter 13: Diet and Periodontal Diseases. Monographs in oral science. 2020;28, 125–133. doi: 10.1159/000455380.
52. Salazar CR, Laniado N, MossavarRahmani Y, Borrell LN, Qi Q, SotresAlvarez D, et al. Better-quality diet is associated with lower odds of severe periodontitis in US Hispanics/Latinos. Journal of Clinical Periodontology. 2018;v. 45, n. 7, p. 780–790. doi: 10.1111/jcpe.12926.
53. Bernabé E, Vehkalahti MM, Sheiham A, Lundqvist A, Suominen AL. The Shape of the Dose-Response Relationship between Sugars and Caries in Adults. Journal of Dental Research. 2016; v.

95, n. 2, p. 167–172. doi: 10.1177/0022034515616572.
54. Zhan L. Rebalancing the Caries Microbiome Dysbiosis: Targeted Treatment and Sugar Alcohols. Advances in dental research. 2018; v. 29, n. 1, p. 110–116. doi: 10.1177/0022034517736498.
55. Nielsen SJ, Trak-Fellermeier MA, Joshipura K, Dye BA. Dietary Fiber Intake Is Inversely Associated with Periodontal Disease among US Adults. The Journal of Nutrition. 2016;v. 146, n. 12, p. 2530–2536. doi: 10.3945/jn.116.237065.
56. Laiola M, De Filippis F, Vitaglione P, Ercolini D. A Mediterranean Diet Intervention Reduces the Levels of Salivary Periodontopathogenic Bacteria in Overweight and Obese Subjects. Applied and environmental microbiology. 2020;v.86, n. 12. doi: 10.1128/AEM.00777-20.
57. Calder PC. Omega-3 fatty acids and inflammatory processes: From molecules to man. Biochemical Society Transactions. 2017; v.45, n.5, p.1105–1115. doi: 10.3390/nu2030355.
58. Azzi DV, Viafara JAS, Zangeronimo MG, Lima RR, Marques LS, Pereira LJ. n-3 ingestion may modulate the severity of periodontal disease? Systematic review Diana. 2018;v.58,p.1–32. doi: 10.1080/10408398.2017.1278677.
59. Kruse AB, Kowalski CD, Leuthold S, Vach K, Ratka-Krüger P, Woelber JP. What is the impact of the adjunctive use of omega-3 fatty acids in the treatment of periodontitis? A systematic review and meta-analysis. Lipids in health and disease. 2020; v.19, n.1, p.100. Doi: 10.1186/s12944-020-01267-x.
60. Iwasaki M, Manz MC, Moynihan P, Yoshihara A, Muramatsu K, Watanabe R, et al. Relationship between saturated fatty acids and periodontal disease. Journal of Dental Research. 2011;v.90,n.7,p.861–867. doi: 10.1177/0022034511405384
61. Dawson DR III, Branch-Mays G, Gonzalez OA, Ebersole JF. Dietary modulation of the inflammatory cascade. Periodontology 2000. 2014; v.64, n.1, p.161–197. doi: 10.1111/j.1600-0757.2012.00458.x.
62. Carbone JW, Pasiakos SM. Dietary protein and muscle mass: Translating science to application and health benefit. Nutrients. 2019;v.11, n.5, p.1–13. doi: 10.3390/nu11051136.
63. Drummen M, Tischmann L, Gatta-Cherifi B, Adam T, Westerterp-Plantenga M. Dietary protein and energy balance in relation to obesity and co-morbidities. Frontiers in Endocrinology. 2018 aug,v.9. doi: 10.3389/fendo.2018.00443.
64. Hopkins M, Blundell JE. Energy balance, body composition, sedentariness and appetite regulation: Pathways to obesity. Clinical Science. 2016; v. 130, n. 18, p. 1615–1628. doi: 10.1042/CS20160006.
65. Martinez-Herreira M, Silvestre-Rangil J, Silvestre FJ. Association between obesity and periodontal disease. A systematic review of epidemiological studies and controlled clinical trials. Medicina Oral, Patologia Oral y Cirugia Bucal. 2017;v. 22, n. 6, p. e708–e715. doi: 10.4317/medoral.21786.
66. Khan S, Barrington G, Bettiol S, Barnett T, Crocombe L. Is overweight/obesity a risk factor for periodontitis in young adults and adolescents?: a systematic review. Obesity Reviews. 2018; v. 19, n. 6, p. 852–883. doi: 10.1111/obr.12668.
67. Mahan LK, Escott-Stump S, Raymond JK. Krause: Food & Nutrition Care Process. 14ª ed. Rio de Janeiro: Elsevier, 2016. 1228 p.
68. Shay B, Ami OB, Lanculovici DL, Zini A, Lanculovici C, Almoznino G. "Oral health-related quality of life in patients with disorders of nutrition." Journal of oral rehabilitation. 2019;vol.46,4: 355-368. doi: 10.1111/joor.12754.
69. Cagetti MG, Wolf TG, Tennert C, Camoni N, Lingström P, Campus G. The role of vitamins in oral health. A systematic review and meta-analysis. International Journal of Environmental Research and Public Health. 2020;v. 17, n. 3. doi: 10.3390/ijerph17030938.
70. Uwitonze AM, Murererehe J, Claireneza M, Harelimana EI, Nsabimana U, Uwambaye P, et al. Effects of vitamin D status on oral health. Journal of Steroid Biochemistry and Molecular Biology. 2018;v.175, n.2016, p. 190–194. doi: 10.1016/j.jsbmb.2017.01.020.
71. Badrasawi MMH, Nijjeh NH, Amer RS, Allan RM, Altamimi M. Nutrition Awareness and Oral Health among Dental Patients in Palestine: A Cross-Sectional Study. International Journal of Dentistry. 2020; v. 2020. doi: 10.1155/2020/3472753.
72. Hujoel PP, Lingstrom P. Nutrition, dental caries and periodontal disease: a narrative review. Journal of Clinical Periodontology. 2017; v. 44, p. S79–S84. doi: 10.1111/jcpe.12672.
73. Shils ME, Shilke M, Ross AC, Caballero B, Cousins RJ. Modern Nutrition in Health and Disease. 11ed. São Paulo: Manole, 2016.
74. Pulido-Moran M, Bullon P, Morillo JM, Battino M, Quiles JL, Ramirez-Tortosa M. The relationship between insulin resistance and periodontitis is not affected by Mediterranean diet in a Spanish population. Archives of Oral Biology. 2017; v. 77, p. 62–67. doi: 10.1016/j.archoralbio.2017.01.023.
75. Elkhouli AM. The efficacy of host response modulation therapy (omega-3 plus low-dose aspirin) as an adjunctive treatment of chronic periodontitis (Clinical and biochemical study). Journal of Periodontal Research. 2011; v. 46, n. 2, p. 261–268. doi: 10.1111/j.1600-0765.2010.01336.x.
76. Sun M, Zhou Z, Dong J, Zhang J, Xia Y, Shu R. Antibacterial and antibiofilm activities of docosahexaenoic acid (DHA) and eicosapentaenoic acid (EPA) against periodontopathic bacteria. Microbial Pathogenesis. 2016; v. 99, p. 196–203. doi: 10.1016/j.micpath.2016.08.025.
77. Hill C, Guarner F, Reid G, Gibson GR, Merenstein DJ, Pot B, et al. The International Scientific Association for Probiotics and Prebiotics consensus statement on the scope and appropriate use of the term probiotic. Nat Rev Gastroenterol Hepatol. 2014;11, 506–514. doi: 10.1038/nrgastro.2014.66.
78. Rather IA, Bajpai VK, Kumar S, Lim J, Paek WK, Park YH. Probiotics and Atopic Dermatitis: An Overview. Frontiers in Microbiology. 2016;7. doi: 10.3389/fmicb.2016.00507.
79. Dalal IA, Haidar MA, Yahya AA, Dania NA, Nada SA, Marwan EA. The role of gut microbiome in the pathogenesis of psoriasis and the therapeutic effects of probiotics. Journal of Family Medicine and Primary Care. 2019;8:11, 3496-3503. doi: 10.4103/jfmpc.jfmpc_709_19.
80. Gul K, Singh AK, Jabeen R. Nutraceuticals and Functional Foods: The Foods for the Future World. Critical Reviews in Food Science and Nutrition. 2015;56(16), 2617–2627. doi:10.1080/10408398.2014.903384.
81. Sullivan Å, Nord C. The place of probiotics in human intestinal infections. International Journal of Antimicrobial Agents. 2002;20(5), 313–319. doi: 10.1016/s0924-8579(02)00199-1.
82. Makarova K, Slesarev A, Wolf Y, Sorokin A, Mirkin B, Koonin E, et al. Comparative genomics of the lactic acid bacteria. Proceedings of the National Academy of Sciences. 2006; 103(42), 15611–15616. doi: 10.1073/pnas.0607117103.
83. Bachmann H, Molenaar D, Branco dos Santos F, Teusink B. Experimental evolution and the adjustment of metabolic

strategies in lactic acid bacteria. FEMS Microbiology Reviews. 2017; 41(Supp_1), S201–S219. doi: 10.1093/femsre/fux024.
84. McFarland LV, Evans CT, Goldstein EJC. Strain-Specificity and Disease-Specificity of Probiotic Efficacy: A Systematic Review and Meta-Analysis. Frontiers in Medicine. 2018; 5. doi: 10.3389/fmed.2018.00124.
85. Crook N, Ferreiro A, Gasparrini AJ, Pesesky MW, Gibson MK, Wang B, et al. Adaptive Strategies of the Candidate Probiotic E. coli Nissle in the Mammalian Gut, Cell Host & Microbe. 2019; Volume 25, Issue 4, 499-512.e8. doi: 10.1016/j.chom.2019.02.005.
86. Esteban-Fernández A, Zorraquín-Peña I, Ferrer MD, Mira A, Bartolomé B, González de Llano D, et al. Inhibition of Oral Pathogens Adhesion to Human Gingival Fibroblasts by Wine Polyphenols Alone and in Combination with an Oral Probiotic. Journal of Agricultural and Food Chemistry. 2018; 66(9), 2071–2082. doi: 10.1021/acs.jafc.7b05466.
87. Singh MP, Bhatia A. Role of functional foods in periodontal health and disease. Indian Journal of Dental Advancements. 2011; 03, 587–592. doi: 10.5866/3.3.587.
88. Shin HS, Baek DH, Lee SH. Inhibitory effect of Lactococcus lactis on the bioactivity of periodontopathogens. The Journal of General and Applied Microbiology. 2018; 64, 55–61.
89. Chen YT, Hsieh PS, Ho HH, Hsieh SH, Kuo YW, Yang SF, et al. Antibacterial activity of viable and heatkilled probiotic strains against oral pathogens. Letters in Applied Microbiology. 2020. doi: 10.1111/lam.13275.
90. Zhang Y, Wang X, Li H, Ni C, Du Z, Yan F. Human oral microbiota and its modulation for oral health. Biomedicine and Pharmacotherapy. 2018; v. 99, n. Septembe 2017, p. 883–893. doi: 10.1016/j.biopha.2018.01.146.
91. Bustamente M, Oomah BD, Mosi-Roa Y, Rubilar M, Burgos-Díaz C. Probiotics as an Adjunct Therapy for the Treatment of Halitosis, Dental Caries and Periodontitis. Probiotics and Antimicrobial Proteins. 2019. doi: 10.1007/s12602-019-9521-4.
92. Arimatsu K, Yamada H, Miyazawa H, Minagawa T, Nakajima M, Ryder MI, et al. Oral pathobiont induces systemic inflammation and metabolic changes associated with alteration of gut microbiota. Sci. Rep. 2014;4:4828.
93. Nakajima M, Arimatsu K, Kato T, Matsuda Y, Minigawa T, Takahashi N, et al. Oral administration of P. gingivalis induces dysbiosis of gut microbiota and impaired barrier function leading to dissemination of enterobacteria to the liver. Plos One 2015;10: e0134234.
94. Hugar SM, Dhariwal NS, Majeed A, Badakar C, Gokhale N, Mistry L. Assessment of Vitamin B12 and Its Correlation with Dental Caries and Gingival Diseases in 10- to 14-year-old Children: A Cross-sectional Study. International Journal of Clinical Pediatric Dentistry. 2017; v. 10, n. 2, p. 142–146. doi: 10.5005/jp-journals-10005-1424.
95. Bhargava A, Rastogi P, Lal N, Singhal R, Khatoon S, Ali Mahdi A. Relationship between Vitamin D and chronic periodontitis. Journal of Oral Biology and Craniofacial Research. 2019; v. 9, n. 2, p. 177–179. doi: 10.1016/J.JOBCR.2018.07.001.
96. Chee B, Park B, Fitzsimmons T, Coates AM, Bartold PM. Omega-3 fatty acids as an adjunct for periodontal therapy-a review. Clinical Oral Investigations. 2016;v.20,n.5,p.879–894. doi: 10.1007/s00784-016-1750-2.
97. Zohoori FV, Duckworth RM. Chapter 5: Microelements: Part II: F, Al, Mo and Co. The Impact of Nutrition and Diet on Oral Health. 2019; 48–58. doi: 10.1159/000455370.
98. Tada A, Miura H. The relationship between vitamin C and periodontal diseases: A systematic review. International Journal of Environmental Research and Public Health. 2019; v. 16, n. 14. doi: 10.3390/ijerph16142472.
99. Dassi E, Ballarini A, Covello G, Quattrone A, Jousson O, De Sanctis V, et al. Enhanced microbial diversity in the saliva microbiome induced by short-term probiotic intake revealed by 16S rRNA sequencing on the IonTorrent PGM platform. Journal of Biotechnology. 2014; 190, 30–39. doi: 10.1016/j.jbiotec.2014.03.024.
100. Hedayati-Hajikand T, Lundberg U, Eldh C, Twetman S. Effect of probiotic chewing tablets on early childhood caries—a randomized controlled trial. BMC oral health. 2015; 15(1), 112. doi: 10.1186/s12903-015-0096-5.
101. Stamatova I, Meurman J. Probiotics: health benefits in the mouth. Am J Dent. 2009; 22: 32938.
102. Esteban Fernández A, Ferrer MD, ZorraquínPeña I, LópezLópez A, Moreno Arribas MV, Mira A. In vitro beneficial effects of Streptococcus Dentisani as potencial oral probiotic for periodontal diseases. Journal of Periodontology. 2019. doi: 10.1002/jper.18-0751.
103. Garcia VG, Knoll LR, Longo M, Novaes VCN, Assem NZ, Ervolino E, et al. Effect of the probiotic Saccharomyces cerevisae on ligature-induced periodontitis in rats. Journal of Periodontal Research. 2016; 51:26-37. doi: 10.1111/jre.12274.
104. Theodoro LH, Cláudio MM, Nuernberg MAA, Miessi DMJ, Batista JA, Duque C, et al. Effects of Lactobacillus reuteri as an adjunct to the treatment of periodontitis in smokers: randomised clinical trial. Beneficial microbes. 2019; 10(4), 375-384.
105. Almoznino G, Gal N, Levin L, Mijiritsky E, Weinberg G, Lev R, et al. Diet practices, body mass index, and oral health- related quality of lifein adults with periodontitis- acase-control study. International Journal of Environmental Research and Public Health. 2020; v. 17, n. 7.

ARE GLASS CARBOMER SEALANTS MORE EFFICIENT IN PREVENTING CARIOUS LESIONS IN CHILDREN'S PERMANENT MOLARS WHEN COMPARED TO OTHER SEALANT MATERIALS? A SYSTEMATIC REVIEW AND META-ANALYSIS

Célia Maria Condeixa de França **Lopes**[1], Letícia Maíra **Wambier**[2], Ana Cláudia Rodrigues **Chibinski**[3*], Alessandra **Reis**[4], Denise Stadler **Wambier**[3]

[1]University of Joinville Region, Joinville, SC, Brazil.
[2]Department of Dentistry, School of Dentistry, Positivo University, Curitiba, PR, Brazil.
[3]Department of Pediatric Dentistry, School of Dentistry, State University of Ponta Grossa, PR, Brazil.
[4]Department of Restorative Dentistry, School of Dentistry, State University of Ponta Grossa, PR, Brazil.

Palavras-chave: Selantes de Fóssulas e Fissuras. Cárie Dental. Revisão Sistemática.

RESUMO

Objetivo: Esta revisão sistemática foi realizada para avaliar a eficácia de selantes de fóssulas e fissuras em carbômero de vidro comparados a outros materiais seladores na prevenção de lesões cariosas em crianças e retenção em fóssulas e fissuras. **Fontes dos dados**: Este estudo incluiu apenas estudos clínicos randomizados que compararam selantes em carbômero de vidro com selantes em outros materiais em molares permanentes em crianças com um acompanhamento mínimo de 6 meses. Uma busca sistemática foi realizada nas bases de dados PubMed, Scopus, Web of Science, LILACS, BBO, Cochrane Library e literatura cinzenta. Resumos de IADR, registros de triagens clínicas não publicadas, bases de dissertações e teses também foram pesquisados. O risco de viés dos estudos foi avaliado por meio da ferramenta Cochrane e a qualidade da evidência com o GRADE. Metanálises foram realizadas com os estudos que permitiram a coleta de dados. **Síntese dos dados**: Um total de 1685 artigos foram identificados e 54 selecionados para revisão. Destes, 40 artigos foram excluídos depois da leitura do resumo e 8 foram incluídos na análise qualitativa e quantitativa. A prevalência de fóssulas e fissuras livres de cárie foi similar após 6 (p=0,77; I^2= 0%) e 12 meses (p=0,60; I^2= 0%) e qualidade da evidência foi considerada baixa; após 24 meses, os outros materiais tiveram melhor desempenho (p=0,30; I^2=7%) com evidência moderada. Não houve diferença nas taxas de retenção dos diferentes materiais após 6 (p<0,0001; I^2= 96%), 12 meses (p<0,0001; I^2= 99%), ou 24 meses (p<0,0001; I^2= 100%) de acompanhamento; a qualidade foi considerada muito baixa. **Conclusão**: Selantes de carbômero de vidro tem retenção similar aos outros materiais seladores utilizados. Em relação ao desenvolvimento de novas lesões de cárie, os outros materiais apresentaram melhor desempenho ao longo do tempo. Todavia, novos estudos clínicos devem ser desenvolvidos para corroborar estes achados, uma vez que há falta de qualidade na evidência obtida.

Keywords: Pit and Fissures Sealants. Dental Caries. Systematic Review. Glass Carbomer Cement.

ABSTRACT

Objective: This systematic review was performed to evaluate the efficacy of glass carbomer when compared with other sealant materials in preventing carious lesions in children and retention in pit and fissures. **Sources of data**: The paper included only randomized clinical trials that compared pit and fissure sealants with glass carbomer and other sealant materials in children's permanent molars with at least six-month follow-up. A systematic search was performed in PubMed, Scopus, Web of Science, LILACS, BBO, Cochrane Library and Grey literature (December 2020/January 2021). The risk of bias tool from the Cochrane Collaboration was used for quality assessment of the studies and GRADE approach for the quality of the evidence. Meta-analysis was performed on studies from which data could be achieved. **Synthesis of data**: A total of 1685 papers were identified, 54 were selected for review. From these, 40 articles were excluded after the reading of the abstract and 14 articles were put aside for assessment. Eight papers were included in qualitative and quantitative synthesis. The prevalence of caries-free pit and fissures did not show differences after six (p=0.77; I^2= 0%) or 12 months (p=0.60; I^2= 0%) and the quality of the evidence was judged as low; after 24 months, other sealant materials performed better (p=0.30; I^2=7%) and the quality as moderate. There were no differences in the retention rates of the different materials after six-month (p<0.0001; I^2= 96%), 12-month follow-up (p<0.0001; I^2= 99%) and 24 months (p<0.00001; I^2= 100%); the quality of the evidence was considered very low. **Conclusion**: Glass carbomer sealants have a similar performance to other sealant materials when retention is considered. For the development of new carious lesions, other sealant materials performed better over time. However, new clinical trials are needed to corroborate these findings since it still lacks quality to the evidence raised.

Submitted: August 21, 2020
Modification: February 01, 2021
Accepted: February 17, 2021

***Correspondence to:**
Ana Claudia Rodrigues Chibinski
Departament of Dentistry, State University of Ponta Grossa
Address: Av. General Carlos Cavalcanti, 4748. Ponta Grossa, Paraná, Brasil. CEP: 84.030-900. Bloco M, Sala 04
E-mail: anachibinski@hotmail.com

INTRODUCTION

Young permanent molars' susceptibility to caries is related to their stage of eruption (limited mechanical oral function) and the anatomy of the groove-fossa system that favors the biofilm accumulation.[1] This is probably the reason why preventive methods such as water fluoridation or fluoride toothpastes have a greater effect in reducing the prevalence of caries on smooth surfaces when compared to occlusal ones.[2]

Therefore, occlusal caries control programs should be implemented from the very beginning of tooth eruption.[1] One treatment that has been proved effective in arresting or inhibiting the carious lesions on young permanent molars is the use of pit and fissure sealant.[3-5] For this purpose, different sealant materials can be used: resin-based sealants, glass ionomer sealants (GI), polyacid-modified resin sealants and resin-modified glass ionomer sealants.[2]

Systematic reviews have compared the efficacy of the different materials in preventing dental decay in permanent molars. Clinical evidence suggests similar caries preventive effectiveness of high viscosity glass ionomer cements and resin-based sealants[6,7] as well as no superiority of resin-modified GIC and resin-based sealants[8] or between resin-modified GIC and conventional GIC.[9] Recently, one systematic review stated that the relative effectiveness of glass ionomer compared to resin sealants remains inconclusive.[10] Therefore, there is still room for further research, especially when new sealant materials are considered.

The resin-based sealants rely only on the mechanical retention on the tooth surface to prevent or arrest caries progression;[6] they act as a physical barrier that blocks the biofilm/enamel contact and they are highly moisture-sensitive. GIC sealants show hydrophilic characteristics and lower retention rates,[6,11] particularly for conventional GIC,[12] but there is an "anti-caries" effect related to the material that remains deep in the fissures and the release of fluoride inherent in GICs.[6, 13]

Even so, none of the cited materials fulfill all the requirements for an ideal fissure sealant, which includes biocompatibility, anticariogenicity, adequate bond strength to enamel, good marginal integrity, resistance to abrasion and wear and low cost.[14]

Recently, an alternative material has been launched in the market: glass carbomer cement (GCC). It is a new type of GIC that is claimed to have enhanced bioactivity compared with conventional GIC.[13] Its powder has nanocrystals of calcium fluorapatite that acts as nuclei for the remineralization process and a much finer particle size compared to GIC.[15] The manufacturer states that the incorporation of nanosized filler particles can improve compressive strength and wear resistance.[16,17]

When this product was tested as a pit and fissure sealant controversial results have been reported[18-22] in comparison to resin-based and/or glass ionomer cement.

Therefore, the purpose of this systematic review was to answer the following question: Are glass carbomer sealants more efficient in preventing/arresting carious lesions in children's permanent molars when compared to other sealant materials?

MATERIAL AND METHODS

Protocol and registration

This study protocol was registered at the PROSPERO database (CRD42016036918). The PRISMA statement recommendations were followed for its report.[23] The research was developed in December 2020/January 2021 at the State University of Ponta Grossa, Paraná, Brazil.

Information sources and search strategy

The controlled vocabulary (MeSH terms) and free keywords in the search strategy were defined based on the PICOS question:

1. Population (P): children's permanent molars.
2. Intervention (I): glass carbomer cement used as pit and fissure sealant.
3. Comparison (C): other sealant materials (GIC or resin-based materials).
4. Primary outcome (O): preventing/arresting carious lesions; secondary outcome: retention rates of sealants after at least 6 months.
5. Study design (S): randomized clinical trials (RCT).

We combined controlled vocabulary (MeSH terms) and free keywords, using the Boolean operators OR and AND to define the search strategy for the PubMed database (Table 1). Then, we adapted the PubMed search strategy to other electronic databases such as Scopus, Web of Science, the Latin American and Caribbean Health Sciences Literature database (LILACS), the Brazilian Library in Dentistry (BBO) and the Cochrane Library (Table 1).

Hand searching of the reference lists of all primary studies was carried out to find additional relevant publications. The first page of related article links of each primary study in the PubMed database was also investigated. We did not restrict studies based on publication date or languages.

The grey literature was explored using the database System for Information on Grey Literature in Europe (SIGLE). Abstracts of the annual conference of the International Association for Dental Research (IADR) and its regional

***Table 1**: Search strategy and electronic databases.*

Pubmed		
#1 molar [MeSH Terms]) OR dentition, permanent [MeSH Terms]) OR dentition, mixed[MeSH Terms]) OR dental caries [MeSH Terms]) OR "permanent molars" [Title/Abstract]) OR "permanent molar" [Title/Abstract]) OR "mixed dentition" [Title/Abstract]) OR "occlusal surfaces" [Title/Abstract	**#2** pit and fissure sealants[MeSH Terms]) OR dental fissures [MeSH Terms]) OR "caries prevention"[Title/Abstract]) OR Sealant* [Title/Abstract]) OR "pits and fissures" [Title/Abstract]) OR "pit and fissure" [Title/Abstract]) OR sealing [Title/Abstract]) OR "sealant retention" [Title/Abstract]) OR "preventing caries" [Title/Abstract]) OR "dental sealants" [Title/Abstract]) OR "fissure sealant"[Title/Abstract]) OR "sealant pleacement"[Title/Abstract]) OR "placed sealants" [Title/Abstract]) OR "sealant leakage" [Title/Abstract])	**#3** glass carbomer cement [Supplementary concept]) OR glass ionomer cements [MeSH Terms]) OR "glass carbomer" [Title/Abstract]) OR ionomer [Title/Abstract]) OR "resin sealants"[Title/Abstract])
	#1 and #2 and #3	
Cochrane Library		
#1 MeSH descriptor: [Molar] explode all trees **#2** MeSH descriptor: [Dentition, permanent] explode all trees **#3** MeSH descriptor: [Dentition, Mixed] explode all trees **#4** MeSH descriptor: [Dental Caries] explode all trees **#5** permanent next molar*:ti,ab,kw or mixed next dentition:ti,ab,kw or occlusal next surfaces:ti,ab,kw (Word variations have been searched) **#6** #1 OR #2 OR #3 OR #4 or #5	**#7** MeSH descriptor: [Pit and Fissure Sealants] explode all trees **#8** MeSH descriptor: [Dental Fissures] explode all trees **#9** caries next prevention: ti,ab,kw or Sealant*: ti,ab,kw or "pit and fissure": ti,ab,kw or "pits and fissures": ti,ab,kw or sealing: ti,ab,kw (Word variations have been searched) **#10** sealant near retention: ti,ab,kw or preventing next caries: ti,ab,kw or dental next sealants: ti,ab,kw or fissure next sealant or sealant next pleacement:ti,ab,kw (Word variations have been searched) **#11** placed near sealants:ti,ab,kw *or* sealant near leakage:ti,ab,kw(Word variations have been searched) **#12** #7 or #8 or #9 or #10 or #11	#**13** MeSH descriptor: [Glass Ionomer Cements] explode all trees **#14** "glass carbomer cement":ti,ab,kw or glass next carbomer:ti,ab,kw or ionomer:ti,ab,kw or resin near sealants:ti,ab,kw (Word variations have been searched) **#15** #12 or #13
	#6 and #12 and #15	

***Table 1**: Search strategy and electronic databases.*

Web of Science		
#1 TOPIC: (molar) *OR* TOPIC: ("dentition permanent") *OR* TOPIC: ("dentition mixed") OR TOPIC: ("dental caries") *OR* TOPIC: ("permanent molar$") *OR* TOPIC: ("mixed dentition") *OR* TOPIC: ("occlusal surfaces")	**#2** TOPIC: ("pit and fissures sealants") *OR* TOPIC: ("dental fissures") *OR* TOPIC: ("caries prevention") *OR* TOPIC: (sealant$) *OR* TOPIC: ("pit* and fissure*") *OR* TOPIC: (sealing) *OR* TOPIC: ("sealant retention") *OR* TOPIC:("preventing caries") *OR* TOPIC:("dental sealants") *OR* TOPIC:("fissure sealant") *OR* TOPIC:("sealant pleacement") *OR* TOPIC: ("placed sealants") *OR* TOPIC:("sealant leakage"))	**#3** TOPIC: ("glass carbomer cement") *OR* TOPIC: ("glass ionomer cements") *OR* TOPIC: ("glass carbomer") *OR* TOPIC: (ionomer) *OR* TOPIC:("resin sealants")
#1 and #2 and #3		
Scopus		
#1 (TITLE-ABS-KEY (molar) OR TITLE-ABS-KEY ("dentition permanent") OR TITLE-ABS-KEY ("dentition mixed") OR TITLE-ABS-KEY ("dental caries") OR TITLE-ABS-KEY ("permanent molar*") OR TITLE-ABS-KEY ("mixed dentition") OR TITLE-ABS-KEY ("occlusal surfaces")	**#2** (TITLE-ABS-KEY ("pit and fissures sealants") OR TITLE-ABS-KEY ("dental fissures") OR TITLE-ABS-KEY ("caries prevention") OR TITLE-ABS-KEY (sealant*) OR TITLE-ABS-KEY ("pit and fissure") OR TITLE-ABS-KEY (sealing) OR TITLE-ABS-KEY ("sealant retention") OR TITLE-ABS-KEY ("preventing caries") OR TITLE-ABS-KEY ("dental sealants") OR TITLE-ABS-KEY ("fissure sealant") OR TITLE-ABS-KEY ("sealant placement") OR TITLE-ABS-KEY ("placed sealants") OR TITLE-ABS-KEY ("sealant leakage"))	**#3** TITLE-ABS-KEY ("glass carbomer cement") OR TITLE-ABS-KEY ("glass ionomer cements") OR TITLE-ABS-KEY ("glass carbomer") OR TITLE-ABS-KEY (ionomer) OR TITLE-ABS-KEY ("resin sealants")) AND (LIMIT-TO (SUBJAREA , "DENT"))
#1 and #2 and #3		

***Table 1**: Search strategy and electronic databases.*

Lilacs/ BBO		
#1 (MH:molar OR MH:"dentition permanent" OR MH:"dentition mixed" OR MH:"dental caries" OR "permanent molars" OR "molares permanentes" OR "permanent molar" OR "molar permanentes" OR "mixed dentition" OR "dentición mixta" OR "dentição mista" OR "occlusal surfaces" OR "superficies oclusales" OR "superfícies oclusais")	**#2** (MH:"pit and fisure sealants" OR MH:"dental fissures" OR "caries prevention" OR "prevención de caries" OR "prevenção de cáries" OR sealant OR sellador OR selante OR sealants OR selladores OR selantes OR "pits and fissures" OR "fosas y fisuras" OR "sulcos e fissuras" OR "pit and fissure" OR "fosa y fisura" OR "sulco e fissura" OR sealing OR "caza de focas" OR vedação OR "sealant retention" OR "retención del sellador" OR "retenção de selante" OR "preventing caries" OR "prevención de caries" OR "prevenção da cárie" OR "dental sealants" OR "selladores dentales" OR "selantes dentários" OR "fissure sealant" OR "sellador de fisuras" OR "selante de fissura" OR "sealant pleacement" OR "colocación del sellador" OR "colocação de selante" OR "placed sealants" OR "selladores colocados" OR "selantes colocados" OR "sealant leakage" OR "filtración de sellador" OR "perda de selante")	**#3** (MH:"glass ionomer cements" OR"cimento ionômero de vidro" OR "glass carbomer cement" OR "cemento de vidrio carbómero" OR " cimento carbomero de vidro" OR "glass carbomer" OR "carbómero cristal" OR "carbómero de vidro" OR ionomer OR ionômero OR "resin sealants" OR "selladores de resina" OR "selantes de resina")
#1 and #2 and #3		

***Table 2**: Summary of the studies included in this systematic revie.*

Study ID	Follow-up (months)	Study design [study setting]	Subjects' mean age (mean± SD) [range]	Number subjects/ teeth	Type of teeth	Criteria for teeth to be eligible	Isolation method	Materials	Sealant Application Protocol	Outcomes evaluated (Evaluation criteria)
Elkwatehy, Bukhari, (2019)[32]	6, 12, 18, 24 months	Split mouth design [dental clinic; university]	n.r.n.r. [6-8]	44 children/ 176 teeth	First permanent molars	Fully erupted first permanent molar, ICDAS 0, 1 or 2	Cotton roll isolation	IC: ICON™ (DMG Dental Materials, Hamburg, Germany) CR: Seal It (SPIDENT CO., LTD. Kojan-dong, Namdong-ku, Incheon, Korea.) GC: GCP glass seal (GCP Dental | First ScientificDental GmbH, Elmshom, Germany) IC + CR: ICON (DMG Dental Materials, Hamburg, Germany) + Seal It (SPIDENT CO., LTD. Kojan-dong, Namdong-ku, Incheon, Korea.)	IIC: application of ICONEtch (15% hydrochloric acid) for 2 min, followed by rinsing with water for 30 s and drying with oilfree and waterfree air; the etched surface was desiccatedusing the ICON dry (99% ethanol) for 30 sfollowed by drying with oilfree and waterfree air.ICONInfiltrant syringe was placed on the targeted surfaceand the resininfiltrant dispensed. After 3 min, the excesswas wiped off and the surface was lightcured for 40 s. Finally, the infiltrant was reapplied for 1 min and light curedfor 40 s.CR: acid etching with 37% phosphoric acidgel for 30 s, rinse, dry, sealant placement over the pits and fissures, light cure for 30 s. GC: GCP sealant capsule was mixed for 7 s in a amalgamator and applied on the teeth, followed by GCP gloss application on the surface of the material with a cotton pellet and light cured for 60 s (GCP Carboled CL) IC + CR: the teeth were treated with the resin infiltrant followed by the application of SealIt. The clinical steps were described above	Sealant retentio n(score A = sealant is present in all the fissure system; score B = sealant is present in >50%; of the fissure system; score C = sealant is present in <50% of the fissure system; score D = absent sealant Development of new carious lesions (ICDAS)

***Table 2**: Summary of the studies included in this systematic revie.*

Study ID	Follow-up (months)	Study design [study setting]	Subjects' mean age (mean± SD) [range]	Number subjects/ teeth	Type of teeth	Criteria for teeth to be eligible	Isolation method	Materials	Sealant Application Protocol	Outcomes evaluated (Evaluation criteria)
Gorseta et al., (2014)[16]	6 and 12	Split-mouth design [n.r]	8.0±2.3 [n.r]	24 children 48 teeth	First and second permanent molars	Fully erupted permanent molars with their contra-lateral tooth present-Caries-free molars-No evidence of hypoplasia-No previous sealant application	Rubber dam	CR: HeliosealF (Ivoclar Vivadent, Schaan, Liechtenstein) GC: Glass Carbomer (GCP Dental | First Scientific Dental GmbH, Elmshom, Germany)	CR: prophylaxis with pumice, enamel acid etch (30 s) (37.5% phosphoric acid Kerr Etchand[c], rinse and dry (20 s), sealant application, light polimerization (20s)GC: prophylaxis with pumice, enamel conditioning (20s) (Tooth cleaner; EDTA solution, Glass Carbomer Products[b]) rinse and dry (20 s), sealant application, light application (60s) (polymerization unit Bluephase[d] 16i - 1600 mW/cm2)	Sealant retention (Kilpatrick et al, 1996[25])* New carious lesions (score 1-absent; score 2-present.)

***Table 2**: Summary of the studies included in this systematic revie.*

Study ID	Follow-up (months)	Study design [study setting]	Subjects' mean age (mean± SD) [range]	Number subjects/ teeth	Type of teeth	Criteria for teeth to be eligible	Isolation method	Materials	Sealant Application Protocol	Outcomes evaluated (Evaluation criteria)
Chen et al., (2012) a[19 ¥]	6, 12 and 24 months	Parallel design Multiple sealants per patient (mean 3.3 teeth) [at school]	8 years old (n.r) [7 – 9.1]	407 children 1352 teeth	First permanent molars	Fully erupted first permanent molars- No dentine carious lesions in pits and fissures - Deep and/or intermediate pits or fissures - dmft (decayed, missing and filled teeth) ≥2	Cotton wool rolls	HVGI:Ketac Molar Easymix (3M Oral Care, St Paul, MN, USA) HVGI + light: Ketac Molar Easymix (3M Oral Care, St Paul, MN, USA) GC: Glass Carbomer (GCP Dental| First Scientific Dental GmbH, Elmshom, Germany) CR: Clinpro (3M Oral Care, St Paul, MN, USA)	HVGI: tooth cleaning with wet cotton pellets, dried with dry cotton wool pellets, conditioned with glass-ionomer liquid (10s), washed and dried with cotton pellets, sealant application, finger printing technique (5-10s), petroleum jelly cover. HVGI + light: HVGI application protocol plus the application of LED curing light (60s – 750mW/cm^2) before petroleum jelly cover GC: tooth cleaning with wet cotton pellets followed by a cotton pellet dipped in Glass Carbomer Tooth Cleaner[b] (20s) , washed and dried with cotton pellets, sealant application, application of Glass Garbomer Surface Gloss[b] finger printing technique (5-10s), application of LED curing light (60s – 750mW/cm^2) CR: tooth cleaning woth rotating brush Prophy Angles[f] and suction device, rinse and dry, enamel acid etch (20s) (Scotchbond™ etchant[f]), rinse and dry, sealant application, application of LED curing light (20s – 750mW/cm^2)	Development of carious lesions

***Table 2**: Summary of the studies included in this systematic revie.*

Study ID	Follow-up (months)	Study design [study setting]	Subjects' mean age (mean± SD) [range]	Number subjects/ teeth	Type of teeth	Criteria for teeth to be eligible	Isolation method	Materials	Sealant Application Protocol	Outcomes evaluated (Evaluation criteria)
Chen et al., 2012 b[20 ¥]	6, 12, 24 and 48	Parallel design Multiple sealants per patient (mean 3.3 teeth) [at school]	8 years old (n.r) [7.0 – 9.1]	407 children 1352 teeth	First permanent molars	Fully erupted first permanent molars- No dentine carious lesions in pits and fissures - Deep and/or intermediate pits or fissures - dmft (decayed, missing and filled teeth) ≥2	Cotton wool rolls	HVGI:Ketac Molar Easymix (3M Oral Care, St Paul, MN, USA) HVGI + light: Ketac Molar Easymix (3M Oral Care, St Paul, MN, USA) GC: Glass Carbomer (GCP Dental | First ScientificDental GmbH, Elmshom, Germany) CR: Clinpro (3M Oral Care, St Paul, MN, USA)	HVGI: tooth cleaning with wet cotton pellets, dried with dry cotton wool pellets, conditioned with glass-ionomer liquid (10s), washed and dried with cotton pellets, sealant application, finger printing technique (5-10s), petroleum jelly cover. HVGI + light: HVGI application protocol plus the application of LED curing light (60s – 750mW/cm^2) before petroleum jelly cover GC: tooth cleaning with wet cotton pellets followed by a cotton pellet dipped in Glass Carbomer Tooth Cleaner[b] (20s) , washed and dried with cotton pellets, sealant application, application of Glass Garbomer Surface Gloss[b] finger printing technique (5-10s), application of LED curing light (60s – 750mW/cm^2) CR: tooth cleaning woth rotating brush Prophy Angles[f] and suction device, rinse and dry, enamel acid etch (20s) (Scotchbond™ etchant[f]), rinse and dry, sealant application, application of LED curing light (20s – 750mW/cm^2)	Sealant retention

***Table 2**: Summary of the studies included in this systematic revie.*

Study ID	Follow-up (months)	Study design [study setting]	Subjects' mean age (mean± SD) [range]	Number subjects/ teeth	Type of teeth	Criteria for teeth to be eligible	Isolation method	Materials	Sealant Application Protocol	Outcomes evaluated (Evaluation criteria)
Zhang et al, (2014)[21 ¥]	6, 12, 24 and 48 months	Parallel design Multiple sealants per patient (mean 3.3 teeth) [at school]	8 years old (n.r) [7.0 – 9.1]	407 children 1352 teeth	First permanent molars	Fully erupted first permanent molars - No dentine carious lesions in pits and fissures - Deep and/or intermediate pits or fissures -dmft (decayed, missing and filled teeth) ≥2	Cotton wool rolls	HVGI:Ketac Molar Easymix (3M Oral Care, St Paul, MN, USA) HVGI + light: Ketac Molar Easymix (3M Oral Care, St Paul, MN, USA) GC: Glass Carbomer(GCP Dental | First ScientificDental GmbH, Elmshom, Germany) CR: Clinpro (3M Oral Care, St Paul, MN, USA)	HVGI: tooth cleaning with wet cotton pellets, dried with dry cotton wool pellets, conditioned with glass-ionomer liquid (10s), washed and dried with cotton pellets, sealant application, finger printing technique (5-10s), petroleum jelly cover. HVGI + light: HVGI application protocol plus the application of LED curing light (60s – 750mW/cm^2) before petroleum jelly cover GC: tooth cleaning with wet cotton pellets followed by a cotton pellet dipped in Glass Carbomer Tooth Cleaner[b] (20s) , washed and dried with cotton pellets, sealant application, application of Glass Garbomer Surface Gloss[b] finger printing technique (5-10s), application of LED curing light (60s – 750mW/cm^2) CR: tooth cleaning woth rotating brush Prophy Angles[f] and suction device, rinse and dry, enamel acid etch (20s) (Scotchbond™ etchant[f]), rinse and dry, sealant application, application of LED curing light (20s – 750mW/cm^2)	Sealant retention (clinical evaluation and occlusal replica – SEM) Development of carious lesions (ART caries assessment criteria)**

***Table 2**: Summary of the studies included in this systematic revie.*

Study ID	Follow-up (months)	Study design [study setting]	Subjects' mean age (mean± SD) [range]	Number subjects/ teeth	Type of teeth	Criteria for teeth to be eligible	Isolation method	Materials	Sealant Application Protocol	Outcomes evaluated (Evaluation criteria)
H u et al., (2014)[31 ¥]	6, 12 and 24 months	Parallel design Multiple sealants per patient (mean 3.3 teeth) [at school]	8 years old (n.r) [7.0 – 9.1]	370 children 1095 teeth	First permanent molars	Fully erupted first permanent molars - No dentine carious lesions in pits and fissures - Deep and/or intermediate pits or fissures -dmft (decayed, missing and filled teeth) ≥2	Cotton wool rolls	HVGI:Ketac Molar Easymix (3M Oral Care, St Paul, MN, USA) HVGI + light: Ketac Molar Easymix (3M Oral Care, St Paul, MN, USA) GC: Glass Carbomer(GCP Dental | First ScientificDental GmbH, Elmshom, Germany) CR: Clinpro (3M Oral Care, St Paul, MN, USA)	HVGI: tooth cleaning with wet cotton pellets, dried with dry cotton wool pellets, conditioned with glass-ionomer liquid (10s), washed and dried with cotton pellets, sealant application, finger printing technique (5-10s), petroleum jelly cover. HVGI + light: HVGI application protocol plus the application of LED curing light (60s – 750mW/cm^2) before petroleum jelly cover GC: tooth cleaning with wet cotton pellets followed by a cotton pellet dipped in Glass Carbomer Tooth Cleaner[b] (20s) , washed and dried with cotton pellets, sealant application, application of Glass Garbomer Surface Gloss[b] finger printing technique (5-10s), application of LED curing light (60s – 750mW/cm^2) CR: tooth cleaning woth rotating brush Prophy Angles[f] and suction device, rinse and dry, enamel acid etch (20s) (Scotchbond™ etchant[f]), rinse and dry, sealant application, application of LED curing light (20s – 750mW/cm^2)	Sealant retention (clinical evaluation and occlusal replica – SEM)

***Table 2**: Summary of the studies included in this systematic revie.*

Study ID	Follow-up (months)	Study design [study setting]	Subjects' mean age (mean± SD) [range]	Number subjects/ teeth	Type of teeth	Criteria for teeth to be eligible	Isolation method	Materials	Sealant Application Protocol	Outcomes evaluated (Evaluation criteria)
H u et al., (2017)[22 ¥]	24 and 36 months	Parallel design Multiple sealants per patient (mean 3.3 teeth) [at school]	8 years old (n.r) [7.0 – 9.1]	157 children 332 teeth	First permanent molars	Fully erupted first permanent molars - No dentine carious lesions in pits and fissures - Deep and/or intermediate pits or fissures -dmft (decayed, missing and filled teeth) ≥2	Cotton wool rolls	HVGI:Ketac Molar Easymix (3M Oral Care, St Paul, MN, USA) HVGI + light: Ketac Molar Easymix (3M Oral Care, St Paul, MN, USA) GC: Glass Carbomer(GCP Dental | First ScientificDental GmbH, Elmshom, Germany) CR: Clinpro (3M Oral Care, St Paul, MN, USA)	HVGI: tooth cleaning with wet cotton pellets, dried with dry cotton wool pellets, conditioned with glass-ionomer liquid (10s), washed and dried with cotton pellets, sealant application, finger printing technique (5-10s), petroleum jelly cover. HVGI + light: HVGI application protocol plus the application of LED curing light (60s – 750mW/cm^2) before petroleum jelly cover GC: tooth cleaning with wet cotton pellets followed by a cotton pellet dipped in Glass Carbomer Tooth Cleaner[b] (20s) , washed and dried with cotton pellets, sealant application, application of Glass Garbomer Surface Gloss[b] finger printing technique (5-10s), application of LED curing light (60s – 750mW/cm^2) CR: tooth cleaning woth rotating brush Prophy Angles[f] and suction device, rinse and dry, enamel acid etch (20s) (Scotchbond™ etchant[f]), rinse and dry, sealant application, application of LED curing light (20s – 750mW/cm^2)	Sealant retention (clinical evaluation and occlusal replica – SEM)

*Note: identification; SD – standard deviation; n.r. – not reported; CR – Resin-based sealant; GC – Glass Carbomer; HVGI – high viscosity glass ionomer; IC – Icon resin infiltrant. *Criteria of Kilpatrick[25]: sealant retention: type 1 to 4 (1-intact sealant ; 2- 1/3 sealant missing; 3- 2/3 sealant missing; 4- whole sealant missing), new carious lesions (1-absent; 2-present). Score sealant retention criteria: 1 to 9 (1 –Pits and fissures completely covered with material; 2-Pits and fissures partly visible. Sharp fracture edge, creating plaque retention site; 3- Pits and fissures partly visible. Crumbled fracture edge, not creating plaque retention site; 4- Pits and fissures totally visible; If score 4 has been given then pits and fissures are re-observed using compressed air; 5- Pits and fissures totally covered with remnants; 6- Pits and fissures partly covered with remnants; 7- Other treatment performed; 9- Unable to diagnosis). **ART caries assesment criteria: 0 to 9 (0 – Sound surface; 1 – Early enamel lesion. White/opaque or brownish/dark lesion in enamel only, including loss of tooth surface; considered being active or inactive; 2- Carious lesion involving the dentine slightly; lesion cannot be penetrated with CPI probe; 3 – Dentinal lesion; lesion can be penetrated with CPI probe; 4- Dentinal lesion: pulp possibly or definitely exposed; 5 – Restoration; 6 – Sealant; 7 – Missing due to caries; 8 – Unerupted permanent tooth; 9 – Unable to make diagnosis. ¥ All the papers are different reports of only one clinical trial, approved by the Research Ethics Committee of Wuhan University (Reference No. 00704) and registered at the Dutch Trial Registration Centre (Reference No. 1411).*

divisions (1990–2016) were searched. Dissertations and theses were explored using the ProQuest Dissertations and Theses Full-Text databases and the Periodicos Capes Theses database.

Unpublished and ongoing trials were located using clinical trial registries: Current Controlled Trials (www.controlled-trials.com), International Clinical Trials Registry Platform (http://apps.who.int/trialsearch/), the ClinicalTrials.gov (www.clinicaltrials.gov), Rebec (www.rebec.gov.br) and EU Clinical Trials Register (https://www.clinicaltrialsregister.eu).

Eligibility criteria

The included studies were RCTs with parallel or split-mouth designs that compared glass carbomer versus GIC and resin-based pit and fissure sealants in permanent molars in children. There were no restrictions regarding publication language or publication date.

RCTs were excluded if glass carbomer was not used as a sealant in permanent molars of children or if there was not a minimum follow-up period of 6 months. Case reports, in vitro studies, non-randomized trials were also excluded.

The primary outcome evaluated was the prevention of carious lesions in permanent molars; sealant retention was studied as a secondary outcome. Full-text versions of the papers that met the inclusion criteria were retrieved for further assessment and data extraction.

Study selection and data collection process

All the retrieved papers were sent to a managing software (EndNote X9, Clarivate, Philadelphia, PA). Duplicated articles were removed from the selection and considered once. Title and abstract of the retrieved studies were analyzed to check out if they met the eligibility criteria; if insufficient information prevented a decision, full-texts were used. This was done by one research (C.M.C.F.L.).

The remaining articles were classified by two reviewers jointly (C.M.C.F.L and L/M/W.) after full-text reading. An ID for each eligible study was created, combining the first author's name and year of publication. Relevant information about the study design, participants, interventions and outcomes was extracted using customized extraction forms. All the data from different sealing materials that were compared to glass carbomer sealant were grouped and annotated under the denomination "other sealants".

When there were reports with different follow-ups from the same study, data from the reports were extracted directly into a single data collection form to avoid overlapping data. This form was pilot tested to certify that the retrieved data was consistent with the research question.

Risk of bias in individual studies

The Cochrane Collaboration tool for assessing the risk of bias in RCT was used for the quality assessments of the trials.[23] This procedure was accomplished by two independent reviewers.

There are six domains in the assessment criteria: adequate sequence generation, allocation concealment, blinding of the outcome assessors, incomplete outcome data, selective outcome reporting, and other possible sources of bias. For each aspect of the quality assessment, the risk of bias was scored following the recommendations described in the Cochrane Handbook for Systematic Reviews of Interventions 5.1.0 (http://handbook.cochrane.org). The judgment for each domain consisted of recording "yes" (low risk of bias), "no" (high risk of bias) or "unclear" (either lack of information or uncertainty over the potential for bias).

If one or more key domains were classified as "unclear" risk of bias, the study was considered at "unclear" and if at least one domain was judged as "high" risk of bias, the study was judged as "high" risk of bias. If there was any disagreement between the reviewers in judging the key domains, it was solved through discussion or by consulting a third reviewer (A.C.R.C.).

Summary measures and synthesis of the results

Data from eligible studies were dichotomous (prevalence of caries-free pits and fissures and retention rates). Studies from which data could be extracted were included in the meta-analyses. The outcomes were summarized by calculating the risk ratio/risk difference for dichotomous data. For both summary measures, the 95% confidence interval (CI) was calculated.

Random-effects models were employed. Heterogeneity was assessed using the Cochran Q test and I^2 statistics. All analyses were conducted using CMA software (version 3, Biostat Englewood, USA). No subgroup analysis was performed.

Assessment of the quality of evidence using GRADE

The quality of the evidence for each outcome across studies (body of evidence) was assessed using the Grading of Recommendations: Assessment, Development and Evaluation (GRADE) (http://www.gradeworkinggroup.org/). This determines the overall strength of evidence for each meta-analysis and classifies it into 4 levels: very low, low, moderate, high. The "high quality" suggests that we are very confident that the true effect lies close to the estimate of the effect. On the other extreme "very low quality" suggests that

we have very little confidence in the effect estimate and the estimate reported can be substantially different from what it was measured.

GRADE analyses the limitations in 5 criteria (risk of bias, imprecision, inconsistency, indirectness of evidence and publication bias) to rate down the quality of the evidence in 1 or 2 levels. Each domain was assessed as "no limitation" (no downgrade), "serious limitations" (1 level downgraded), and "very serious limitations" (2 levels downgraded). The GRADEpro Guideline Development Tool (www.gradepro.org) was used to create a summary of findings table.

Results

Study selection

After the database screening and removal of duplicates, 1053 papers were identified (Figure 1). After analysis of titles, 54 papers remained. Forty papers were excluded after the reading of abstracts, resulting in 14 full-text papers for assessment of eligibility. From these, six papers were excluded due to different reasons: in vitro studies,[24,25] non-randomized trial,[26] cost-effectivity study[27,28] prevention of carious lesions in permanent molars with micro-cavities in dentin.[29] One project of clinical trials, registered at the Dutch Trial Registration Centre (# 1441), resulted in 6 different papers[19-22,30,31] that showed data from distinct follow-up periods and outcomes. They were combined to describe the study characteristics, the risk of bias and the data to be included in the meta-analysis to avoid data overlap. Besides those papers, only two other clinical trials were identified.[18,32]

Characteristics of the included papers

The characteristics of the studies included are listed in Table 2. Two studies[18,32] used the split-mouth design; the treatments were accomplished at a university dental clinic in one of them.[32] The other six papers reported parallel design.[19-22,30,31] and the clinical procedures were carried out at primary schools in China. The mean age of the participants included in the RCTs was 8 years old.

All the included papers had samples composed of fully erupted permanent molars without dentin carious lesions.[19-22,30,31] The follow-up period of the clinical trials ranged from 6 to 12 months to 48 months. The sealants were performed with rubber dam and prophylaxis with pumice in one study.[18] In the other studies, isolation with cotton rolls were used.[19-22,30,31]

The materials used for pit and fissure sealing were glass carbomer (GC Products, Leiden, Netherlands),[18-22,30-32] which was compared to high viscosity GIC,[19-22,30,31] resin-based sealants[18-22, 31] and resin infiltrant.[32]

The prevalence of carious lesion-free pits and fissures was based on a yes/no criteria,[18] International Caries Detection and Assessment. System (ICDAS)[32] or with a 0-9 scale (ART caries criteria).[19-22,30,31] The evaluation criteria used for assessment of the sealant retention were not the same. In one study,[18] the authors used the Kilpatrick criteria[33] for sealant evaluation with scores ranging from 1 to 4; other papers[19-22,30,31] used clinical exam and occlusal replicas; and the other study used scores from A to D.[32]

Assessment of the risk of bias

The risk of bias of the selected studies is presented in Figure 2. One study was judged to be at unclear risk of bias,[18] the other studies were judged to be at low risk of bias.[19-22,30-32]

Meta-analysis

All meta-analyses were performed for the outcomes "prevalence of new carious lesions" and "sealant retention" in three follow-up periods: 6, 12 and 24 months.

Prevalence of new carious lesion

The meta-analyses related to the outcome "prevalence of new carious lesions" are presented in Figure 3.

No difference between glass carbomer sealants and the other sealant materials was detected for 6 (p=0.63) and 12 (p=0.81) months follow-up periods; these meta-analyses showed no heterogeneity (I^2=0%). The quality of the evidence for both periods was graded as "low", which means that the confidence in the effect estimate is limited and the true effect may be substantially different from the estimated effect. The quality was downgraded two levels due to imprecision because the optimal information size was not met and the confidence interval doesn't exclude benefit or harm (Table 3).

However, after 24 months, other sealant materials performed better than glass carbomer sealant (p=0.002) and the meta-analysis showed low heterogeneity (I^2=7%). For this outcome, the quality of the evidence was graded as "moderate", since we are moderately confident that the true effect is close to the estimate of the effect, but there is yet a possibility that it is substantially different. The quality was downgraded one level due to imprecision since the optimal information size was not met (Table 3).

Sealants retention

The meta-analyses related to the outcome "sealant retention" for 6, 12 and 24 months follow-up periods are presented in Figure 4. Regardless, the follow-up period, no differences were detected between glass carbomer sealant and other sealant materials tested (p<00001). All the analyses exhibited heterogeneity values higher than 95%. The quality of evidence for all the evaluation periods was graded as "very low". It means that there is little confidence in the estimated effect and that the true effect probably is different from the estimated one. The quality of evidence was downgraded in two levels for inconsistency and imprecision, which is related to non-explained heterogeneity and a wide confidence interval, respectively (Table 4).

Table 3: *Summary-of-findings table and quality of the evidence regarding the outcome "development of new carious lesions". Only comparisons with meta-analysis were included.*

Development of new carious lesions in permanent molars in children: Glass carbomer X other sealing materials

Outcomes	Nº of participants (studies)Follow up	Certainty of the evidence (GRADE)	Relative effect (95% CI)	Anticipated absolute effects	
				Risk with other sealants	Risk difference with glass carbomer sealant
New carious lesions - 6 months	1515(3 RCTs)	⊕⊕◯◯ LOW [a]	**Rate ratio 0.00** (0.01 to 0.00)	0 per 1000	**0 fewer per 1000** (0 fewer to 0 fewer)
New carious lesions - 12 months	1515(3 RCTs)	⊕⊕◯◯ LOW [a]	**RR 1.15** (0.36 to 3.72)	8 per 1000	**1 more per 1000** (5 fewer to 22 more)
New carious lesions - 24 months	1804(2 RCTs)	⊕⊕⊕◯ MODERATE [b]	**RR 1.93** (1.27 to 2.93)	37 per 1000	**35 more per 1000** (10 more to 72 more)

*Note: *The risk in the intervention group (and its 95% confidence interval) is based on the assumed risk in the comparison group and the relative effect of the intervention (and its 95% CI). CI: Confidence interval; RR: Risk ratio. GRADE Working Group grades of evidenceHigh certainty: We are very confident that the true effect lies close to that of the estimate of the effectModerate certainty: We are moderately confident in the effect estimate: The true effect is likely to be close to the estimate of the effect, but there is a possibility that it is substantially differentLow certainty: Our confidence in the effect estimate is limited: The true effect may be substantially different from the estimate of the effectVery low certainty: We have very little confidence in the effect estimate: The true effect is likely to be substantially different from the estimate of effect. Explanations: a. The optimal information size criterion was not met, there were few events and the CI included appreciable benefit and harm; b. The optimal information size criterion was not met.*

Table 4: *Summary-of-findings table and quality of the evidence regarding the outcome "sealant retention". Only comparisons with meta-analysis were included.*

Sealant retention in permanent molars in children: Glass carbomer X other sealing materials

Outcomes	Nº of participants (studies)Follow up	Certainty of the evidence (GRADE)	Relative effect (95% CI)	Anticipated absolute effects	
				Risk with other sealants	Risk difference with glass carbomer sealant
Sealant retention -6 months	1515(3 RCTs)	⊕◯◯◯ VERY LOW [a,b]	**RR 0.12** (0.13 to 0.38)	79 per 1000	**70 fewer per 1000**(69 fewer to 49 fewer)
Sealant retention - 12 months	1515(3 RCTs)	⊕◯◯◯ VERY LOW [a,c]	**RR 2.12** (0.49 to 9.16)	170 per 1000	**191 more per 1000**(87 fewer to 1391 more)
Sealant retention - 24 months	1436(2 RCTs)	⊕◯◯◯ VERY LOW [a,c]	**RR 2.02** (0.51 to 8.07)	289 per 1000	**295 more per 1000**(142 fewer to 2046 more)

*Note:*The risk in the intervention group (and its 95% confidence interval) is based on the assumed risk in the comparison group and the relative effect of the intervention (and its 95% CI). CI: Confidence interval; RR: Risk ratio. GRADE Working Group grades of evidenceHigh certainty: We are very confident that the true effect lies close to that of the estimate of the effectModerate certainty: We are moderately confident in the effect estimate: The true effect is likely to be close to the estimate of the effect, but there is a possibility that it is substantially differentLow certainty: Our confidence in the effect estimate is limited: The true effect may be substantially different from the estimate of the effectVery low certainty: We have very little confidence in the effect estimate: The true effect is likely to be substantially different from the estimate of effect. Explanations: a. Inconsistency in the data due to high and non-explained heterogeneity; b. Imprecision due to a high confidence interval that does not exclude great benefit or great harm; optimal information size was not reached; c. Imprecision due to a high confidence interval that does not exclude great benefit or great harm.*

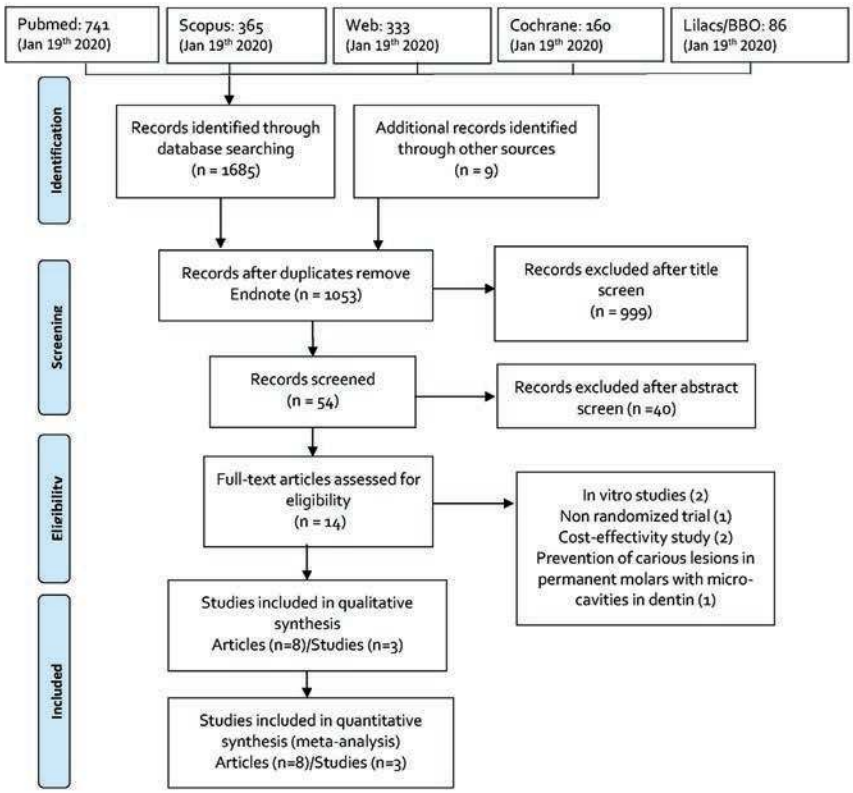

Figure 1: *Flow diagram of included studies.*

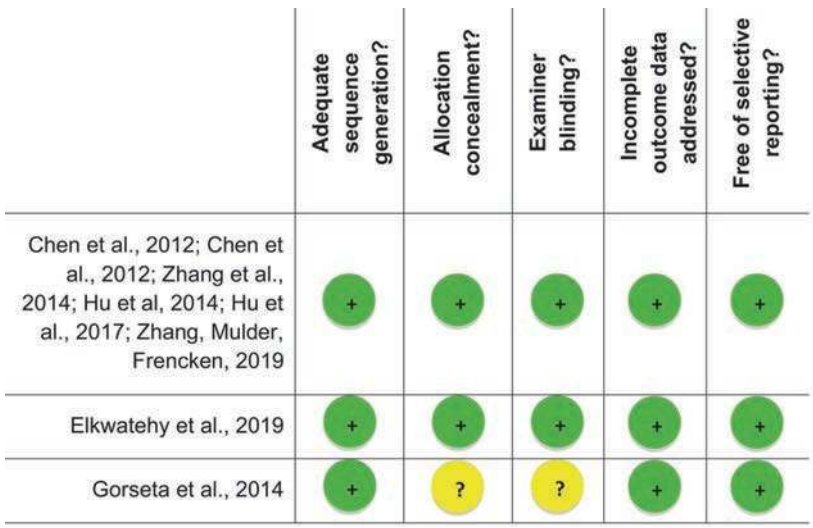

Figure 2: *Summary of the risk of bias assessment according to the Cochrane Collaboration tool.*

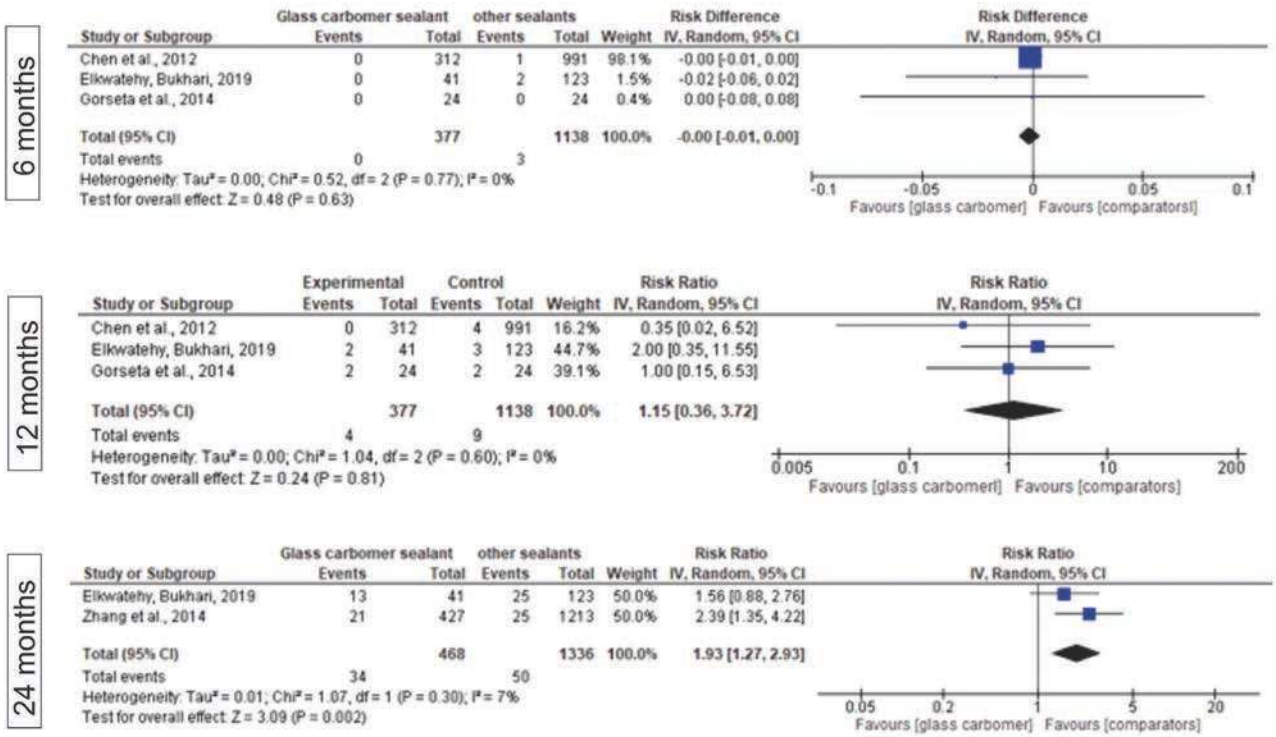

Figure 3: *Forest plots of development of new carious lesions after 6, 12 and 24 months of follow-up.*

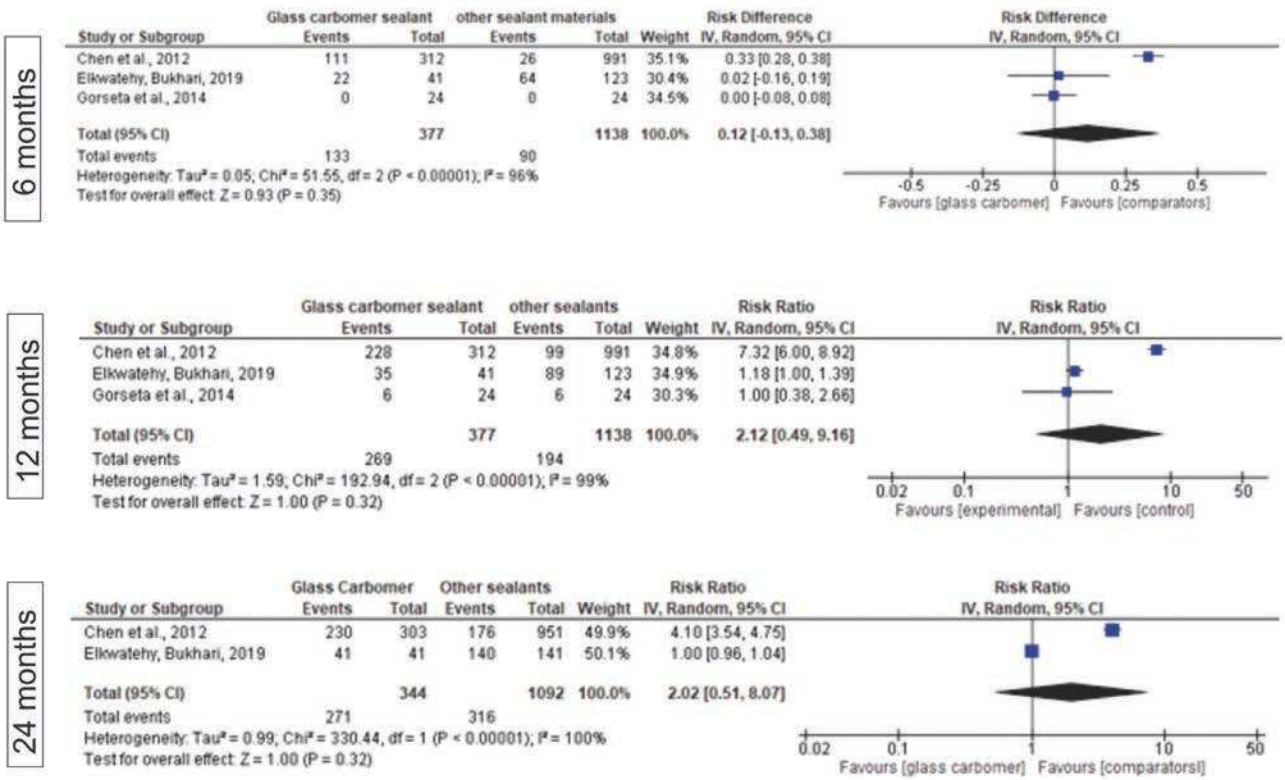

Figure 4*: Forest plots of sealant retention after 6, 12 and 24 months of follow-up.*

DISCUSSION

This systematic review and meta-analysis showed that glass carbomer sealants have a similar performance to other sealant materials when the prevalence of new caries lesions and sealant retention are considered. However, this finding must be taken carefully since the quality of the evidence is low or very low and these results may be modified by new clinical trials. An exception was found for the development of new carious lesions, which seems to achieve better results when other sealing materials are used after 24 months.

Glass carbomer is a restorative material that shares some characteristics with glass ionomer cements, such as the setting process based on an acid-base reaction[15] and the adhesion to mineralized dental substrate based on ion exchange between the material and the tooth.[34] But the interest in studying glass carbomer cement relies on some differences in the cement composition such as the presence of nanocrystals of calcium fluorapatite and much finer particle size. As a result, this material should show enhanced mechanical properties,[15] with bioactivity and probably, good survival rates. Therefore, when using this restorative material as a pit and fissure sealant, it would be expected better than or at least similar clinical behavior as GIC sealants would be expected, even without complete sealant retention.

This assumption was confirmed regarding the development of new carious lesions until 12 months of follow-up, and glass carbomer sealants showed similar performance as the other sealing materials. However, for the 24 months evaluation, HVGIC, HIGIC activated with light and resin-based sealants performed better. This finding is important, but must be interpreted carefully, since the quality of the evidence is moderate.

This finding should be emphasized, considering that the retention of pit and fissure sealants are commonly the main outcome used in clinical trials to evaluate the efficacy of sealants in preventing caries[14] and its ability to remain intact and bonded to the enamel surface for a lifetime is the main goal. [35]

This may be true for resin-based sealants, but not for glass ionomer sealants. The logic behind the use of retention as a measure of sealant efficacy was investigated and has been contradicted by the current evidence.[36,32] A recent systematic review could not find evidence associating the loss of the GIC sealants and the development of carious lesions[37] and therefore considered the prevention of carious lesions as a surrogate endpoint for sealant retention. An update from a Cochrane systematic review also considered the prevention of occlusal carious lesions as the primary outcome.[10] After all, the final objective when a clinician indicates such procedure is to prevent the development of carious lesions in susceptible teeth. That is the reason why this systematic review considered both factors as outcomes for the meta-analysis: the prevention of carious lesions in a more contemporary approach and the sealant retention as the usual outcome.

Regarding retention rates, glass carbomer sealants showed similar clinical performance as other sealing materials, but the quality of the evidence regarding this outcome was considered low or very low. The included studies [18,19,32] exhibited several differences in treatment settings and procedures. These differences may have affected the estimate effects and could explain the high heterogeneity, which makes the estimated pool effect of retention rates not reliable. Additionally, this pooled effect estimate suffers from inaccuracy and we cannot exclude a clinically important benefit or harm when using glass carbomer sealants.

Among the differences between studies, some factors may have some influence on the performance of the sealants. Higher rate retention of GIC sealants can be obtained when the sealant is placed under the finger press technique. The cleaning method is also important. For resin-based sealants, authors showed that occlusal surfaces cleaned with pumice slurry provided significantly higher retention than brushing and no cleaning.[38]

There are also inherent differences related to the comparators used against glass carbomer sealant. Resin-based sealants protocol includes acid-etching techniques, which provide higher bond strength to the enamel;[24] these sealants also show lower viscosity[39] when compared to GIC ones, which may affect the material penetration into the fissures.[40]

Regardless of the described factors, sealants deteriorate over time and the enamel surface may be exposed to the oral environment and the cariogenic challenge again. It is the current assumption that GIC sealants fracture cohesively and remnants of the sealant are left behind in the deeper parts of the fissures.[22] Notwithstanding, it was showed that this may be true also for resin and glass carbomer sealants.[22] The analysis of colored pictures and SEM images revealed that the remnants of GIC, glass carbomer and resin-based sealants are similar after 2 and 3 years.[22] This remaining material modifies the anatomy of the fissures and facilitates the removal of dental plaque by tooth brushing from fissures that otherwise would be inaccessible [22], it also promotes some release of fluoride to the adjacent enamel.[41,42] Both processes seem to explain the lack of caries progression even after total or partial loss of the sealant.

Finally, we should not deny that the present systematic review and meta-analysis was based on only three available studies regarding the clinical performance of glass carbomer as a sealant in permanent molars. Further high-quality RCTs are needed to

improve the quality of the evidence regarding this subject. Therefore, considering the clinical performance and the costs of the glass carbomer cement, we still can not suggest the use of glass carbomer sealants over other sealing materials

CONCLUSIONS

Glass carbomer sealants have a similar performance to other sealant materials when sealant retention is considered. For the development of new carious lesions, other sealant materials performed better over time. However, new clinical trials are needed to corroborate these findings since it still lacks quality to the evidence obtained.

ACKNOWLEDGMENTS

This study was partially supported by the National Council for Scientific and Technological Development from the Brazilian Government, under grants 304105/2013-9 and 305588/2014-1 and the Coordination of Improvement of Higher Level Personnel (CAPES) from the Brazilian Ministry of Education.

REFERENCES

1. Carvalho J. Caries process on occlusal surfaces: evolving evidence and understanding. Caries Res 2014;48(4):339-346.
2. Wright JT, Crall JJ, Fontana M, Gillette EJ, Nový BB, Dhar V, et al. Evidence-based clinical practice guideline for the use of pit-and-fissure sealants: a report of the American Dental Association and the American Academy of Pediatric Dentistry. J Am Dent Assoc 2016;147(8):672-682. e612.
3. Wright JT, Tampi MP, Graham L, Estrich C, Crall JJ, Fontana M, et al. Sealants for preventing and arresting pit-and-fissure occlusal caries in primary and permanent molars: A systematic review of randomized controlled trials—A report of the American Dental Association and the American Academy of Pediatric Dentistry. J Am Dent Assoc 2016;147(8):631-645. e618.
4. Hou J, Gu Y, Zhu L, Hu Y, Sun M, Xue H. Systemic review of the prevention of pit and fissure caries of permanent molars by resin sealants in children in China. J Investig Clin Dent 2017;8(1).
5. AhovuoSaloranta A, Forss H, Walsh T, Hiiri A, Nordblad A, Mäkelä M, et al. Sealants for preventing dental decay in the permanent teeth. Cochrane Database Syst Rev 2013.
6. Yengopal V, Mickenautsch S, Bezerra AC, Leal SC. Caries-preventive effect of glass ionomer and resin-based fissure sealants on permanent teeth: a meta analysis. J Oral Sci 2009;51(3):373-382.
7. Mickenautsch S, Yengopal V. Caries-preventive effect of high-viscosity glass ionomer and resin-based fissure sealants on permanent teeth: a systematic review of clinical trials. PloS One 2016;11(1):e0146512.
8. Yengopal V, Mickenautsch S. Resin-modified glass-ionomer cements versus resin-based materials as fissure sealants: a meta-analysis of clinical trials. Eur Arch Paediatr Dent 2010;11(1):18-25.
9. Mickenautsch S. GIC versus RM-GIC as fissure sealant [October 18, 2016]. J Min Interv Dent 2017;10(3):39-41.
10. AhovuoSaloranta A, Forss H, Walsh T, Nordblad A, Mäkelä M, Worthington HV. Pit and fissure sealants for preventing dental decay in permanent teeth. Cochrane Database Syst Rev 2017.
11. Kühnisch J, Mansmann U, Heinrich-Weltzien R, Hickel R. Longevity of materials for pit and fissure sealing—results from a meta-analysis. Dental Materials 2012;28(3):298-303.
12. Mickenautsch S. Survival rate of ART restorations with high-viscosity GIC versus conventional RM-GIC [October 12, 2015]. J Min Interv Dent 2016;9(2):37-38.
13. Sidhu SK, Nicholson JW. A review of glass-ionomer cements for clinical dentistry. J Funct Biomater 2016;7(3):16.
14. Reddy VR, Chowdhary N, Mukunda K, Kiran N, Kavyarani B, Pradeep M. Retention of resin-based filled and unfilled pit and fissure sealants: A comparative clinical study. Contemp Clin Dent 2015;6(Suppl 1):S18.
15. Zainuddin N, Karpukhina N, Law RV, Hill RG. Characterisation of a remineralising Glass Carbomer® ionomer cement by MAS-NMR spectroscopy. Dent Mat 2012;28(10):1051-1058.
16. Tolidis K, Boutsiouki C, Gerasimou P. Comparative evaluation of microleakage of a carbomer/fluoroapatite-enhanced glass-ionomer cement on primary teeth restorations. Eur J Paediatr Dent 2016;17(3):227-233.
17. GCP. GCP Glass Fill GD: Carbomer and fluorapatite enhanced glass ionomer restorative cement in capsules. In: GCP, ed, 2011.
18. Gorseta K, Glavina D, Borzabadi-Farahani A, Van Duinen R, Skrinjaric I, Hill R, et al. One-year clinical evaluation of a Glass Carbomer fissure sealant, a preliminary study. Eur J Prosthodont Restor Dent 2014;22(2):67-71.
19. Chen X, Du M, Fan M, Mulder J, Huysmans M, Frencken J. Caries-preventive effect of sealants produced with altered glass-ionomer materials, after 2 years. Dent Mat 2012;28(5):554-560.
20. Chen X, Du M, Fan M, Mulder J, Huysmans M-C, Frencken JE. Effectiveness of two new types of sealants: retention after 2 years. Clin Oral Investig 2012;16(5):1443-1450.
21. Zhang W, Chen X, Fan M-W, Mulder J, Huysmans M-CC, Frencken JE. Do light cured ART conventional high-viscosity glass-ionomer sealants perform better than resin-composite sealants: A 4-year randomized clinical trial. Dent Mat 2014;30(5):487-492.
22. Hu X, Zhang W, Fan M, Mulder J, Frencken JE. Frequency of remnants of sealants left behind in pits and fissures of occlusal surfaces after 2 and 3 years. Clin Oral Investig 2017;21(1):143-149.
23. Higgins JP, Altman DG, Gotzsche PC, Juni P, Moher D, Oxman AD, et al. The Cochrane Collaboration's tool for assessing risk of bias in randomised trials. BMJ 2011;343:d5928.

24. Subramaniam P, Jayasurya S, Babu KG. Evaluation of glass carbomer sealant and a moisture tolerant resin sealant–A comparative study. Int J Dent Sci Res 2015;2(2):41-48.
25. Bekmezoðlu ZE, Güngör ÖE, Karayilmaz H. Comparison of glass carbomer, giomer, glass ionomer and resin fissure sealants on permanent molar teeth. Journal of Dentistry Indonesia 2019;26(1):10-18.
26. Hassan AM, Mohammed SG. Effectiveness of Seven Types of Sealants: Retention after One Year. Int J Clin Pediatr Dent 2019;12(2):96-100.
27. Goldman AS, Chen X, Fan M, Frencken JE. Methods and preliminary findings of a costeffectiveness study of glassionomerbased and composite resin sealant materials after 2 yr. European journal of oral sciences 2014;122(3):230-237.
28. Goldman AS, Chen X, Fan M, Frencken JE. Costeffectiveness, in a randomized trial, of glassionomerbased and resin sealant materials after 4 yr. Eur J Oral Sci 2016;124(5):472-479.
29. Zhang W, Mulder J, Frencken JE. Is preventing micro-cavities in dentine from progressing with a sealant successful? Br Dent J 2019;226(8):590-594.
30. Zhang W, Chen X, Fan M, Mulder J, Frencken JE. Retention Rate of Four Different Sealant Materials after Four Years. Oral Health Prev Dent 2017;15(4):307-314.
31. Hu X, Chen X, Ye L, Fan MW, Huysmans MC, Frencken JE. Comparison between visual clinical examination and the replica method for assessments of sealant retention over a 2-year period. Int J Oral Sci 2014;6(2):111-115.
32. Elkwatehy WMA, Bukhari OM. The Efficacy of Different Sealant Modalities for Prevention of Pits and Fissures Caries: A Randomized Clinical Trial. J Int Soc Prev Community Dent 2019;9(2):119-128.
33. Kilpatrick N, Murray J, McCabe J. A clinical comparison of a light cured glass ionomer sealant restoration with a composite sealant restoration. J Dent 1996;24(6):399-405.
34. Olegário IC, Malagrana APVFP, Kim SSH, Hesse D, Tedesco TK, Calvo AFB, et al. Mechanical properties of high-viscosity glass ionomer cement and nanoparticle glass carbomer. J Nanomater 2015;2015:37.
35. Simonsen RJ. Pit and fissure sealant: review of the literature. Ped Dent 2002;24(5):393-414.
36. Mickenautsch S. The logic behind the use of fissure sealant retention as a proxy outcome measure for dental caries prevention. J Oral Sci 2017;59(2):263-272.
37. Mickenautsch S, Yengopal V. Validity of sealant retention as surrogate for caries prevention–a systematic review. PLoS One 2013;8(10):e77103.
38. Hegde RJ, Coutinho RC. Comparison of different methods of cleaning and preparing occlusal fissure surface before placement of pit and fissure sealants: An in vivo study. Journal of Indian Society of Pedodontics and Preventive Dentistry 2016;34(2):111.
39. Irinoda Y, Matsumura Y, Kito H, Nakano T, Toyama T, Nakagaki H, et al. Effect of sealant viscosity on the penetration of resin into etched human enamel. Oper Dent 2000;25(4):274-282.
40. Subramaniam P. Effect of tooth preparation on sealant success—an in vitro study. J Clin Pediatr Dent 2009;33(4):325-331.
41. Kumaran P. Clinical evaluation of the retention of different pit and fissure sealants: a 1-year study. Int J Clin Ped Dent 2013;6(3):183.
42. Ei TZ, Shimada Y, Nakashima S, Romero MJRH, Sumi Y, Tagami J. Comparison of resin-based and glass ionomer sealants with regard to fluoridereleasе and anti-demineralization efficacy on adjacent unsealed enamel. Dent Mater J 2017:2016-2407.

REMNANT ADHESIVE FLASH IN ORTHODONTIC BONDING SYSTEMS WITH DIFFERENT CHARACTERISTICS.

Erika Machado **Caldeira**[1], Paola Estefan **Sass**[2], Vicente **Telles**[3], Nathalia Lima Freze **Fernandes**[4], Claudia Trindade **Mattos**[2], Carlos Nelson **Elias**[5], Ana Maria **Bolognese**[2*], Matilde da Cunha Gonçalves **Nojima**[2]

[1]Department of Orthodontics, School of Dentistry, Universidade Federal Fluminense, Niterói, RJ, Brazil.
[2]Department of Orthodontics and Pediatric Dentistry, School of Dentistry, Universidade Federal do Rio de Janeiro, Rio de Janeiro, RJ, Brazil.
[3]University of Pittsburgh School of Dental Medicine, Pittsburgh, PA, USA.
[4]Private practice.
[5]Biomaterials Laboratory, Instituto Militar de Engenharia, Rio de Janeiro, RJ, Brazil.

Palavras-chave: Colagem Dentária. Adesivo Ortodôntico. Materiais Dentários.

RESUMO:
Introdução: O excesso de material de colagem que permanece ao redor dos bráquetes impacta negativamente a saúde bucal dos pacientes ortodônticos. **Objetivo:** Avaliar a influência dos sistemas de colagem ortodônticos na remoção de excesso de adesivo ao redor de bráquetes. **Métodos:** Baseado em suas características, quatro sistemas de colagem ortodônticos foram selecionados: adesivo fotopolimerizável (G1 – Transbond™ XT); adesivo fotopolimerizável com pigmentação rosa (G2 - Transbond™ Plus Color Change); cimento de ionômero de vidro reforçado com resina (G3 - FujiOrtho™ LC); e adesivo autopolimerizável (G4 - Concise™). Para cada grupo (n=10), um único operador posicionou os bráquetes em dentes bovinos (n=40) e utilizou uma sonda exploradora para remoção visual do excesso de material de colagem. Após a polimerização / tempo de cura, as amostras foram levadas ao estereomicroscópio e o software Axio Vision 4,4 foi utilizado para mensurar a área de excesso de adesivo remanescente ao redor de cada bráquete. Os dados quantitativos obtidos foram analisados pelos testes de Kruskal-Wallis e post-hoc de Dunn em significância de α= 0,05. **Resultados:** O cimento de ionômero de vidro reforçado por resina (G3) apresentou a maior área de remanescente de excesso. Não houve diferença estatisticamente significativa entre os demais grupos (G1, G2 e G4), independente da pigmentação ou do método de polimerização. **Conclusão:** O uso de cimento de ionômero de vidro reforçado por resina resulta em maior área de excesso remanescente, o que pode impactar negativamente a saúde bucal. A pigmentação e o método de polimerização não influenciaram no excesso de material remanescente.

Keywords: Dental Bonding. Orthodontic Adhesive. Dental Materials.

ABSTRACT
Introduction: Excess of adhesive around brackets negatively impact oral health of orthodontic patients. **Objective**: Evaluate the influence of orthodontic bonding system in removal of adhesive flash around orthodontic brackets. **Methods:** Based on their characteristics, four orthodontic bonding systems were selected: light-curing adhesive (G1 - Transbond™ XT); pink pigmented light-curing adhesive (G2 - Transbond™ Plus Color Change); resin-modified glass ionomer cement (G3 - FujiOrtho™ LC); and auto-curing adhesive (G4 - Concise™). For each group (n=10), a single operator placed metal brackets on bovine teeth (n=40) and used an explorer tip to visually remove flash excess. After curing / setting, the samples were taken to a stereomicroscope and the Axio Vision 4.4 software was used to measure the area of remnant adhesive flash around each bracket. The quantitative data obtained was analyzed by the Kruskal-Wallis and Dunn's post hoc test at α= 0.05. **Results**: The results show that the resin-modified glass ionomer cement (G3) had a larger area of remnant material than the other groups. There was no statistical difference between the other groups (G1, G2, and G4), independently of pigmentation or curing technique. **Conclusion**: It was concluded that the use of a resin-modified glass ionomer cement results in a larger area of remnant flash excess, which can negatively impact oral health. Pigmentation and curing technique did not influence on remnant flash excess.

Submitted: July 28, 2020
Modification: Jan 18, 2021
Accepted: Mar 2, 2021

***Correspondence too:**
Ana Maria Bolognese
Address: Rua Professor Rodolpho Paulo Rocco, nº 325 – Ilha do Fundão
Rio de Janeiro – RJ, Brasil
Zip Code: 21941-617
Telephone number: +55 21 2590-2727
Fax: +55 21 2590-9771
E-mail: anabolognes@gmail.com

INTRODUCTION

Since the introduction of orthodontic bonding systems, some new materials have been developed to improve clinical results.[1] Many studies focused on adhesive bond strength[2] and properties such as: stiffness,[3] color stability,[4] fluoride release,[5] inhibition of microbiological growth,[5] cytotoxicity,[6] amongst others. The goals of new adhesives are oral health maintenance, patient and professional satisfaction, and enhancing treatment. Dental literature is rich in articles that analyze residual orthodontic adhesive after bracket debonding, as well as enamel surface characteristics, which must be smooth and polished after treatment to inhibit biofilm aggregation. Many factors are involved in these procedures, such as the instruments used to clean dental surfaces, adhesive removal protocols, the orthodontic bonding system used and the operator's ability.[7]

However, the concern for changes in oral health caused by orthodontic appliances should be present since the beginning of the treatment. The choice of accessories and bonding systems to be used should consider potential for biofilm aggregation, ease of oral hygiene practice, aesthetics, and possibility for staining. Regarding accessories, the industry concentrates effort in enhancing surface roughness, polish and size. For orthodontic bonding systems, it is well-known that, during the bonding step, orthodontists must carefully remove adhesive excess around brackets before curing / setting. The goal of this step is to avoid that flash remnants harm oral health, due to plaque accumulation, leading to teeth staining and decay. Nevertheless, there is a lack of literature that analyze the techniques of bonding the brackets and removing excess adhesive. There is also a lack of studies that analyze if different bonding materials result in more flash excess around brackets.[8,9] Focusing on obtaining a "flash-free" enamel surface should be considered a step as important as bracket positioning for the overall treatment outcome.

The objective of the present work is to quantify the amount of remnant material on tooth surface around brackets after visual flash removal with an explorer tip, comparing four widely-used orthodontic bonding systems: Transbond™ XT Light Cure Adhesive (3M Unitek, Minnesota, USA); Transbond™ Plus Color Change Adhesive (3M Unitek, Minnesota, USA); GC Fuji ORTHO™ Light-cured Orthodontic Cement (GC America Inc., Illinois, USA), and Concise™ Orthodontic Bonding System (3M Unitek, Minnesota, USA). These systems were selected to include materials with different colors, properties and curing techniques, respectively. This study hypothesizes that different bonding material characteristics can influence easiness of flash removal. The null hypothesis is that similar amount of flash remains around the brackets regardless of the bonding material used, suggesting easiness of flash removal is not related to the material chosen.

MATERIALS AND METHODS

Sample preparation

For sample size calculation, a pilot study was performed with 4 samples per group. Considering the data obtained of variance of 26.11 between-groups and error variance of 30.87, it was determined a large effect size of 0.9196. Considering an alpha of 0.05 and a power of 80%, these data indicated the need for 5 specimens in each group. However, we decided to increase sample size to 10 specimens per group, based in previous similar studies.[8,9]

Forty bovine incisors without cracks or color changes were selected and stored in timol 0.1% solution. The crowns were separated from the roots using a diamond metal disc and were positioned on a glass surface, so that that the most plane area of the facial surface was leaning against the glass. Then, a 3/4 inches PVC cylindrical tube was positioned surrounding each crown and acrylic resin (JET Clássico, São Paulo, Brazil) was poured. The samples were grounded with wood sandpaper number 180 and water sandpaper number 600 and 1200 using a polishing machine to standardize smoothness and size of the plane area to a diameter of 6 mm. An insulating tape mask with 6 mm of diameter was positioned over the smooth surface, to expose only the enamel surface for evaluation.[10,11]

Bonding step

Edgewise slim mandibular incisor metal brackets (Morelli Ortodontia, São Paulo, Brazil) were selected due to their smaller size and flatter base, in order to minimize the possibility of gaps between the bovine teeth's flat surface and the bracket base. To simulate the clinical situation, prophylaxis with rubber cup, pumice stone and water was carried out for 10 seconds and, at every 5 samples, a new rubber cup was used. Then, the samples were rinsed for 10 seconds with air and water spray and dried with air spray for 10 seconds. Phosphoric acid 37% (CONDAC 37, FGM Produtos Odontológicos, Santa Catarina, Brazil) was used to condition the enamel surface for 20 seconds, followed by water rinsing and drying as previously described[12].

The samples were randomly distributed amongst the groups (n=10):

- Group 1 - Transbond™ XT Light Cure Adhesive (G1);
- Group 2 - Transbond™ Plus Color Change Adhesive (G2);
- Group 3 - GC Fuji ORTHO™ Light-cured Orthodontic Cement (G3), and
- Group 4 - Concise™ Orthodontic Bonding System (G4).

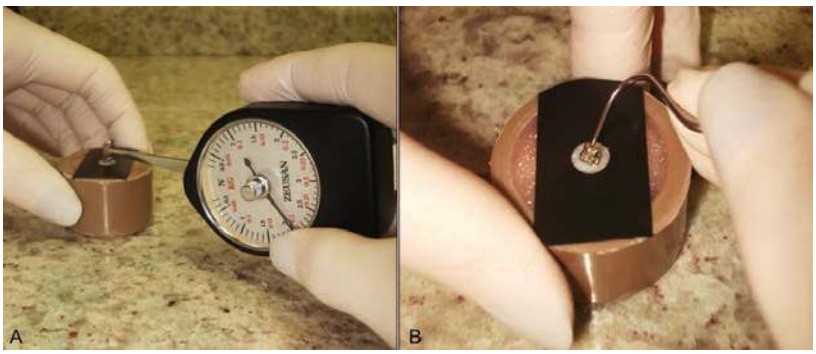

***Figure 1**: A) Illustration of the measurement of the application of a load of 2 N on the bracket. B) Visual flash excess clean-up using an explorer number 5 tip.*

The bonding step was standardized to provide consistent and reliable results. Each material was stored in proper conditions, according to manufacturers' instructions and were left in room temperature for 24 hours before the study. A single operator, a 2nd year orthodontic resident, performed all the procedures, on the same day and under the same conditions. A precision scale was calibrated with the weight of the spatula used to apply the adhesive to the bracket base. Then, the amount of desired material was scooped with the spatula and a new weighting step took place. This procedure was carried out 5 times, and the mean weight of the material was 0.0114 g, varying from 0.0112 g to 0.0124 g.

A tensiometer (Zeusan Exporting Ltda., São Paulo, Brazil) was used to measure the application of a 2 N load at the time of bracket placement (Figure 1A). Then, the tip of an explorer number 5 was used to remove flash excess (Figure 1B) until the operator considered that, visually, all the excess material had been removed, simulating a clinical situation of a "flash-free bonding". G1, G2 and G3 were light-cured, while the G4 was left to auto-cure. Due to the different characteristics of each material making them easily recognizable, the operator was not blinded when performing the bonding step. The samples were kept in 100% humidity for 24 hours, until surface analysis was performed.



***Figure 2**: Stereo microscope Zeiss and AxioVision software showing the 20x magnification to determine the area of remnant material.*

Surface analysis

Analysis of dental surface was performed by a different operator, also a 2nd year orthodontic resident, using a stereo microscope (Carl Zeiss, Göttingen, Germany) with 20x magnification (Figure 2). The outer area of remnant flash around each bracket was delineated and quantified using the software AxioVision v. 4.4 (Carl Zeiss, Göttingen, Germany) (Figure 3). To find only the area of flash excess, the bracket area was calculated and subtracted from the total area. The operator performing the surface analysis was not blinded. To check for any bias, after seven days, a new measurement step was carried out in 5 randomly selected samples and the intraclass correlation coefficient was 0.974, confirming operator reliability.

Statistical analysis

The software program SPSS v. 13.0 (SPSS Inc., Chicago, IL, USA) was used to analyze the data. The Shapiro-Wilk test and histograms were used to analyze sample distribution. Due to irregular distribution, the Kruskal-Wallis test followed by Dunn's post-hoc was used to compare the groups to a level of 5% significance.

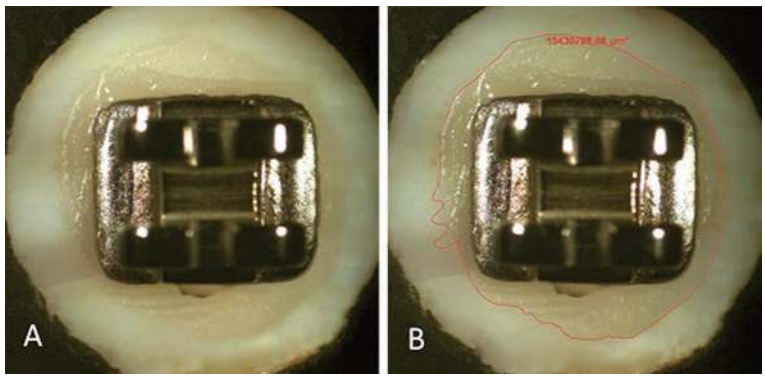

***Figure 3**: A) Visualization of the area of remnant material using stereo microscope with a 20x magnification. B) Determining the area of remnant material around the bracket with the software AxioVision, v. 4.4.*

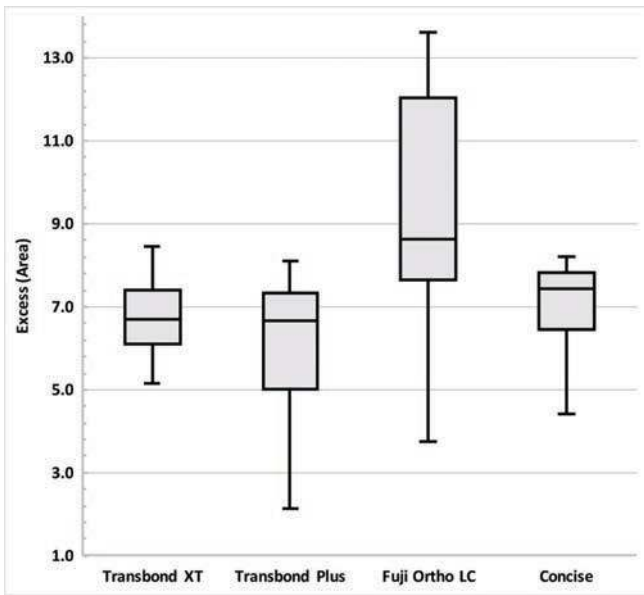

***Figure 4**: Box-Plot comparing the excess areas measured: Transbond™ XT (G1, Md = 6.68 mm²), Transbond™ Plus Color Change (G2, Md = 6.65 mm²), Fuji ORTHO™ LC (G3, Md = 8.60 mm²) e Concise™ (G4, Md = 7.40 mm²), respectively.*

RESULTS

The results are relayed in the box-plot (Figure 4). Statistically significant difference ($p<0.05$) in the remnant material area was observed between G3 (Median (Md) = 8.60 mm², Minimum (Min) = 3.72 mm², Maximum (Max) = 13.61 mm²) and the other groups: G1 (Md = 6.68 mm², Min = 5.15 mm², Max = 8.43 mm²), G2 (Md = 6.65 mm², Min = 2.11 mm², Max = 8.09 mm²), and G4 (Md = 7.40 mm², Min = 4.93 mm², Max = 8.18 mm²). There was no statistically significant difference between G1, G2, and G4.

DISCUSSION

The present study assessed if orthodontic bonding systems characteristics such as pigmentations, properties and curing could influence in obtaining a "flash-free" bonding. The null hypothesis would be the similarity in remnant flash excess in all the materials used, suggesting that the remnant excess is independent of particular characteristics of each systems. The results showed that, when bonding with resin composites, the pigmentation or curing technique does not influence on remnant flash area after excess removal with an explorer tip. However, the use of resin-modified glass ionomer cement results in a larger area of remnant flash, which might have clinical implications.

It is still common to observe in clinical practice some excess of bonding material around brackets. Some orthodontists do not take the necessary time and attention needed to remove excess adhesive after bracket bonding, which might lead to carious lesions, gingival hyperplasia, compromised aesthetics, and enamel staining. Considering that there is an effort to enhance brackets' and accessories'

industrial quality and size to market better appliances, investment in these aspects seems contradictory if the chosen bonding system leaves more remnant flash excess, which might jeopardize plaque control and favor biofilm aggregation.[5,8,13] According to Lee et al., orthodontics adhesives have a higher microbial retaining capacity than brackets.[14] Therefore, focusing on obtaining a "flash-free" enamel surface should be considered a step as important as bracket positioning for the overall treatment outcome.

The analyzed materials in this research were chosen because they include a range of different orthodontic bonding system characteristics. Transbond™ XT (G1) is a light-curing adhesive considered to be the gold-standard in research and clinical practice in Orthodontics.[8] Transbond™ Plus Color Change (G2) also is a light-curing adhesive and, according to the manufacturer, has the advantage of fluoride release and moisture tolerance, besides being a pink paste before light-curing, which enhances brackets positioning and flash clean-up. GC Fuji ORTHO™ Light-Cured Orthodontic Cement (G3) is a glass ionomer light-curing cement well-known for its fluoride release and bonding strength[5]. And lastly, Concise™ Orthodontic Bonding System (G4) is an auto-curing resin with satisfactory mechanical properties that does not require a light-curing stage.

In orthodontic bonding procedure with light-curing adhesives, usually 3 steps are carried out consecutively: enamel etching, dental adhesive spread, and bonding the bracket[12]. However, many studies have shown that there is no statistically significant difference in regard to bonding strength and the use of dental adhesive when there is humidity control.[15,16] Therefore, in this research the dental adhesive step was excluded to limit possible interferences in visual assessment of flash excess and also because there is no comparative dental adhesive step for Concise™ Orthodontic Bonding System (G4).

According to the manufacturer, Transbond™ Plus Color Change (G2) is similar to Transbond™ XT (G1) in regard to bonding strength, with added advantages such as the pink color before light-curing and fluoride release. The manufacturer's premise is that the pink color provides visual contrast between the enamel surface and the bonding material, making flash more visible and easier to remove, without altering characteristics such as tolerance to moisture and bond strength.[17]

However, this research showed that G2 was not statistically significantly different in concern to flash removal from the other resin groups, G1 and G4, which have a color similar to enamel surface, contradicting the manufacturer's premise. This result confirms the previous findings of Alencar et al.[8] and Armstrong et al.[9] that suggested that the addition of a coloring agent to assist in visualization did not reduce the amount of flash around the brackets.

Among the tested materials, Fuji ORTHO™ LC (G3) is the most distinct because it is a resin-modified glass ionomer cement. Its biggest advantage described in the literature is the fluoride release property.[5] Other advantages found in the literature and indicated by the manufacturer are: better working time, because it is light-cured; satisfactory mechanical strength; moisture tolerance; bonding durability; and easy clinical removal after end of treatment.[11,18] However, in concern to remnant flash excess after clean-up, G3 presented a statistically significant difference to the other groups. This finding might be explained by the material's low viscosity compared to the other adhesives, making it harder to remove and more attached to the etched enamel surface.[19]

As flash excess around brackets must be avoided due to aforementioned reasons, one must consider that the fluoride release advantage of Fuji ORTHO™ LC can be overcome by the amount of biofilm aggregated to the material excess. Literature also shows that microorganisms adhere more firmly to resin materials and components present in the adhesive matrix might favor bacterial growth.[5,20] Caldeira et al. assessed the surface of bonding materials submitted to biofilm of *S. mutans*, *L. casei*, and *C. albicans*, and found that Fuji ORTHO™ LC presented the highest microorganism adherence and fixation[5].

Concise™ Orthodontic Bonding System (G4) is an auto-curing paste-paste resin, with its working time restricted by its setting time. Regarding their mechanical properties, both auto-curing and light-curing resins present good debonding strength and bonding adhesive failure rates.[21,22] The setting time of auto-curing resins may reduce the available time for flash removal. Hence, one might expect that light-curing materials would have an advantage in that matter, since their working time is controlled by the operator. However, this hypothesis was not confirmed in this research, as there is no statistically significant difference between G4, and G1 and G2. In this study, the operator removed the excess until visually considering that the sample was "flash-free" and setting time was not considered a limiting factor. However, in clinical practice, the orthodontist takes some time properly positioning the bracket and only then proceeds to flash removal. The time spent in correctly positioning the bracket might limit the time for flash excess removal before the material sets. This situation was not reproduced in this *in vitro* evaluation.

It is important to emphasize that, in this study, bovine teeth were used to prepare the samples, based on several studies that prove that these animals' mandibular incisors are excellent substitutes to human teeth in Dentistry-related

research for their microstructural characteristics, surface roughness, bonding strength, and size[23-26]. However, studies that compare the color of human and bovine teeth have shown that bovine enamel has a darker shade.[27,28]

We hypothesize that adhesives that are similar in color to human enamel might have a higher contrast against bovine enamel. Therefore, visualization might have been easier even for these adhesives than it would have been in human teeth, eliminating the advantage of the pink colored resin Transbond™ Plus Color Change (G2). This bias might also have occurred in Armstrong et al.[9] research, due to the use of typodont teeth, which also differ in color from human teeth.

Continuing the rationale, the contrast would also have benefitted the resin-modified glass ionomer GC Fuji ORTHO™ LC (G3), due to its whiter color, which did not occur, favoring the hypothesis that the nature of the adhesive and its adherence to etched enamel had higher influence in remnant excess than color itself. Possibly, G1 and G2 showed similar results due to their similar structures.

The results and conclusion of this study suggest validation of the hypothesis that materials' properties influence in flash excess removal. Limitations of this study to be pointed out are: (1) the *in vitro* experiment, which does not fully represent the clinical situation, with its particularities; (2) using only one operator to standardize the excess removal technique and limit the variable to the orthodontic bonding system; and (3) results limited to the materials tested. These limitations, however, do not jeopardize the findings. On the contrary, it stimulates new studies on this scarcely researched topic. It is suggested that more research on this subject is carried out with *in situ* or *in vivo* methodology, with more than one operator, and including other materials, such as the flash-free orthodontic adhesive systems. One must consider other reasons for remnant flash on the enamel surface after clean-up, such as: the chosen material, operators ability and visual accuracy, difficulty in identifying the flash excess, type of instrument used for clean-up procedure, time available for bonding, and quantity of material applied to the bracket base. Obtaining a "flash-free" bonding is of major importance when starting an orthodontic treatment and this subject must be given the proper importance, such as debonding techniques do.

CONCLUSION

Based on experimental tests of the present work, the following results were found:

1. The orthodontic bonding system properties can influence in flash excess removal.
2. Bonding with a resin-modified glass ionomer cement resulted in a larger area of remnant adhesive material, even after flash excess removal with an explorer tip, demanding higher attention when this is the material of choice.
3. The curing technique and the addition of pigment to the bonding adhesive do not influence on remnant flash excess.

ACKNOWLEDGEMENTS

The authors sincerely thank Joseph D. Myers for proofreading the article.

REFERENCES

1. Ulusoy Ç. Comparison of finishing and polishing systems for residual resin removal after debonding. J. Appl. Oral Sci. 2009 May-Jun 17(3):209-15. doi:10.1590/s1678-77572009000300015.
2.Passalini P, Fidalgo TKS, Caldeira EM, Gleiser R, Nojima MCG, Maia LC. Mechanical properties of one and two-step fluoridated orthodontic resins submitted to different pH cycling regimes. Braz. Oral. Res. 2010 Apr-Jun 24(2):197-203. doi: 10.1590/s1806-83242010000200012.
3. Caldeira EM, Izquierdo AM, Giacomet F, Sant'Anna EF e Ruellas ACO. The influence of protective varnish on the integrity of orthodontic cements. Dental Press J. Orthod. 2013 Nov-Dec 18(6):45-50. doi: 10.1590/s2176-94512013000600008.
4. Eliades T, Gioka C, Heim M, Eliades G, Makou M. Color stability of orthodontic adhesive resins. Angle Orthod. 2004 June 74(3):391-3. doi: 10.1043/0003-3219(2004)074<0391:CSOOAR>2.0.CO;2.
5. Caldeira EM, Osório A, Oberosler ELC, Vaitsman DS, Alviano DS, Nojima MCG. Antimicrobial and fluoride release capacity of orthodontic bonding materials. J. Appl. Oral Sci. 2013 Jul-Aug 21(4):327-34. doi: 10.1590/1678-775720130010.
6. Bationo R, Jordana F, Boileau MJ, Colat-Parros J. Release of monomers from orthodontic adhesives. Am. J. Orthod. Dentofacial Orthop. 2016 Sep 150(3):491-8. doi: 10.1016/j.ajodo.2016.02.027.
7. Zarrinnia K, Eid NM, Kehoe MJ. The effect of different debonding techniques on the enamel surface: an in vitro qualitative study. Am. J. Orthod. Dentofacial Orthop. 1995 Sep 108(3):284-93. doi: 10.1016/s0889-5406(95)70023-4.
8. Alencar EQ, Nobrega ML, Dametto FR, Santos PB, Pinheiro FH. Comparison of two methods of visual magnification for removal of adhesive flash during bracket placement using two types of orthodontic bonding agents. Dental Press J. Orthod. 2016 Nov-Dec 21(6):43-50. doi: 10.1590/2177-6709.21.6.043-050.oar.
9. Armstrong D, Shen G, Petocz P, Darendeliler MA. Excessive adhesive flash upon bracket placement: a typodont study comparing APC plus and Transbond XT. Angle Orthod. 2007 Nov 77(6):1101-8. doi: 10.2319/081506-334.1.
10. Pereira FL, Iwaki Filho L, Camarini ET, Pavan AJ. [Laboratorial study to test traction resistance of Fill Magic® light-cured resin intended for orthodontic traction of unerupted teeth]. R Dental Press Ortodon. Ortop. Facial 2006 Jan-Fev 11(1):77-83. Portuguese.
11. Pithon MM, Oliveira MV, Ruellas ACO. [A comparative study about shear bond strength of metallic brackets boned with resin-reinforced glass ionomer cements]. Rev. Saude Com. 2006 2(1):127-34. Portuguese.
12. Graber L, Vanarsdall R, Vig K. Orthodontics – Current principles and techniques. 5th ed. St Louis: Mosby; 2011.

13. Pellegrini P, Sauerwien R, Finlayson T, McLeod J, Covelli Jr DA, Maier T, et al. Plaque retention by self-ligating vs elastomeric orthodontic brackets: quantitative comparison of oral bacteria and detection with adenosine triphosphate-driven bioluminescence. Am. J. Orthod. Dentofacial Orthop. 2009 Apr 135(4):426.e1-9. doi: 10.1016/j.ajodo.2008.12.002.
14. Lee SP, Lee SJ, Lim BS, Ahn SJ. Surface characteristics of orthodontic materials and their effects on adhesion of mutans streptococci. Angle Orthod. 2009 Mar;79(2):353-60. doi: 10.2319/021308-88.1.
15. Tang AT, Björkman L, Isaksson L, Lindbäck KF, Andlin-Sobocki A, Ekstrand J. Retrospective study of orthodontic bonding without liquid resin. Am. J. Orthod. Dentofacial Orthop. 2000 Sep 118(3):300-6. doi: 10.1067/mod.2000.103772.
16. Rosa CB, Pinto RAC, Habib FAL. Colagem ortodôntica em esmalte com presença ou ausência de contaminação salivar: é necessário o uso de adesivo auto-condicionante ou de adesivo hidrofílico?. R. Dental Press Ortodon. Ortop. Facial 2008 May-Jun 13(3):34-42. Portuguese.
17. 3M Unitek data on file, 3M Unitek Clai DB Centre [Internet]. THe APC(TM) PLUS Adhesive Coated Appliance System features a pink adhesive, making flash more visible and easier to remove. Available from: http://solutions.3m.co.uk/wps/portal/3M/en_GB/orthodontics_EU/Unitek/Sol utionsCategory/KlebeSystems/Direct/APCPlus/
18. Summers A, Kao E, Gilmore J, Gunel E, Ngan P. Comparison of bond strength between a conventional resin adhesive and a resin-modified glass ionomer adhesive: an in vitro and in vivo study. Am. J. Orthod. Dentofacial Orthop. 2004 Aug 126(2):200-6. doi: 10.1016/j.ajodo.2003.06.013.
19. Knox J, Jones ML, Hubsch P, Middleton J. The influence of orthodontic adhesive properties on the quality of orthodontic attachment. Angle Orthod. 2000 Jun 70(3):241-6. doi: 10.1043/0003-3219(2000)070<0241:TIOOAP>2.0.CO;2.
20. Beyth N, Bahir R, Matalon S, Domb AJ, Weiss EI. Streptococcus mutans biofilm changes surface-topography of resin composites. Dental Mater. 2008 Jun 24(6):732-6. doi: 10.1016/j.dental.2007.08.003.
21. Souza C, Francisconi P, Araujo P. Resistência de união de cinco cimentos usados em Ortodontia. Rev. Faculdade de Odontol. de Bauru 1999 7:15-21. Portuguese.
22.Trimpeneers LM, Dermaut LR. A clinical trial comparing the failure rates of two orthodontic bonding systems. Am. J. Orthod. Dentofacial Orthop. 1996 Nov 110(5):547-50. doi: 10.1016/s0889-5406(96)70064-1.
23. Saleh F, Taymour N. Validity of using bovine teeth as a substitute for human counterparts in adhesive tests. East Mediterr. Health J. 2003 Jan-Mar 9(1-2):201-7.
24. Reis AF, Giannini M, Kavaguchi A, Soares CJ, Line SR. Comparison of microtensile bond strength to enamel and dentin of human, bovine, and porcine teeth. J. Adhes. Dent. 2004 Summer 6(2):117-21.
25. Campos MIC, Campos CN, Vitral RWF. [The use of bovine teeth as a substitute for human teeth in dentistry research: a review of literature.] Pesquisa Brasileira em Odontopediatria e Clínica Integrada 2008 8(1):127-32. Portuguese.
26. Fonseca RB, Haiter-Neto F, Fernandes-Neto AJ, Barbosa GA, Soares CJ. Radiodensity of enamel and dentin of human, bovine and swine teeth. Arch. Oral Biol. 2004 Nov 49(11):919-22.
27. Spitzer D, Bosch JT. The absorption and scattering of light in bovine and human dental enamel. Calcif. Tiss. Res. 1975 17(2):129-37. doi: 10.1016/j.archoralbio.2004.05.006.
28. Spitzer D, Bosch JJ. The total luminescence of bovine and human dental enamel. Calcif. Tiss. Res. 1976 Apr 20(2):201-8. doi: 10.1007/BF02546408.

IMPACT OF ORAL HEALTH ON THE QUALITY OF LIFE AND PERSONAL SATISFACTION OF ADOLESCENTS FROM URBAN AND RURAL AREAS FROM A CITY IN BRAZIL: A CROSS-SECTIONAL STUDY

Hiorran Coelho Almeida **Matos**[1], Gabrielle **Carrozzino**[1], Andréa Vaz Braga **Pintor**[1], Ivete Pomarico Ribeiro de **Souza**[1], Michelle Mikhael Ammari[2], Luciana **Pomarico**[1*]

[1]Department of Pediatric Dentistry and Orthodontics, School of Dentistry, Universidade Federal do Rio de Janeiro, UFRJ, Rio de Janeiro, RJ, Brazil. [2]Department of Specific Formation, Institute of Health, Universidade Federal Fluminense, UFF, Nova Friburgo, RJ, Brazil.

Palavras-chave: Cárie Dentária. Qualidade de Vida. Saúde Pública. Índices de Cárie.

RESUMO

Objetivo: Avaliar o impacto do estado de saúde bucal na qualidade de vida e na satisfação pessoal de adolescentes das áreas urbana e rural de Nova Friburgo, Brasil. **Métodos**: Adolescentes entre 11 e 14 anos, matriculados nas escolas participantes do Programa Saúde na Escola (PSE) da zona rural e urbana desta cidade (n = 509), receberam o Termo de Consentimento Livre e Esclarecido para a participação neste estudo, juntamente ao questionário econômico a ser entregue para o responsável. O estado de saúde bucal do adolescente foi avaliado clinicamente, por meio dos índices Cariados, Perdidos e Obturados (CPOD); critérios de envolvimento pulpar, ulceração, fístula e abscesso (PUFA); e Índice de Necessidades de Tratamento Odontológico (INTO). A qualidade de vida foi mensurada por meio do *Child Perception Questionnaire* (CPQ11-14), enquanto a avaliação da satisfação pessoal, por meio da *Subjective Happiness Scale* (SHS), ambos na forma de entrevista. Foram realizados testes estatísticos (Qui-Quadrado; Exato de Fisher; Mann-Whitney) com nível de significância de 5%. **Resultados**: A amostra final foi de 161 adolescentes. O impacto do estado de saúde bucal na qualidade de vida dos adolescentes de ambas as áreas não foi significativamente diferente, embora o agravamento da condição bucal tenha apresentado tendência a piorar a qualidade de vida. Da mesma forma, não houve relação da condição oral com a satisfação pessoal, sem diferenças entre os grupos. Observou-se que os adolescentes rurais apresentaram melhor qualidade de vida (p<0,010), enquanto os urbanos apresentaram maior grau de satisfação pessoal (p <0,001). **Conclusão**: O estado de saúde bucal teve impacto negativo na qualidade de vida, mas não teve relação com a satisfação pessoal, independente da área demográfica.

Keywords: Dental Caries. Quality of Life. Public Health. Caries Index.

ABSTRACT

Objective: Evaluate the impact of oral health status on the quality of life and personal satisfaction among adolescents from urban and rural areas, in Nova Friburgo, Brazil. **Methods**: Adolescents between 11 and 14 years, enrolled in the schools participating in the Health in School Program (HSP) of rural and urban of this city (n = 509), received the consent form for the participation in this study, along with the economic questionnaire to be handed to the responsible. Adolescent´s oral health status was evaluated clinically, through the Decayed, Missing and Filled Teeth (DMFT); pulpal involvement, ulceration, fistula and abscess criteria (PUFA); and Dental Treatment Needs Index (DTNI). The quality of life was measured through the Child Perception Questionnaire (CPQ11-14), while personal satisfaction´s evaluation, through the Subjective Happiness Scale (SHS), both as interview. Statistical tests were performed (Chi-Square; Fisher's exact; Mann-Whitney) with level of significance of 5%. **Results**: The final sample comprised 161 adolescents. The impact of oral health status on the quality of life of adolescents from both areas was not significantly different, although the aggravation of the oral condition showed a tendency to worse the quality of life. Similarly, there was no relation of the oral status with personal satisfaction, without differences between the groups. It was observed that rural adolescents presented better quality of life (p<0.010), while the urban ones had higher degree of personal satisfaction (p<0.001). **Conclusion**: Oral health status had a negative impact on the quality of life, but had no relation to personal satisfaction, regardless of the demographic area.

Submitted: February 19, 2020
Modification: March 13, 2021
Accepted: March 18, 2021

***Correspondence to**:
Luciana Pomarico
Address: Rua Professor Rodolpho Paulo Rocco, 325 – Cidade Universitária
Zip code: 21941-971 - Rio de Janeiro – RJ –Brazil
Telephone number/Fax: +55 (21) 3938-2101
E-mail: lupomarico@gmail.com

INTRODUCTION

Dental caries is a relevant public health problem worldwide.[1-5] Although some studies showed a significant reduction of the disease, even among adolescents,[6,7] in Brazil, the last national survey showed that caries index continued to be high in this age group.[8,9] In addition, the rate of caries lesions progression was reported as higher at adolescents, when compared to young adults participants.[10] It is also worth noting that dental caries in advanced stages can have a negative impact on the quality of life, due to pain, discomfort and infection.[11-16]

Regarding the oral-health-related quality of life (OHRQoL), it is defined as a multidimensional concept, which is a subjective about all the individual domains complementing clinical health, in the assessment of physical well-being and not just the absence of diseases.[17,18] It reflects among other issues, the comfort of the individual when feeding, during sleep, engaging in social interaction, self-esteem and satisfaction with his/her oral health.[19] Aiming to measure the self-perception of adolescents regarding their OHRQoL, the Child Perceptions Questionnaire (CPQ11-14) is widely used,[20,21] which short version was validated.[22,23] As a complement to the quality of life, the evaluation of personal satisfaction, through the Subjective Scale of Happiness (SHS),[24] characterizes the individual both in absolute and relative forms, according to specific domains, as more or less happy / unhappy.[24,25]

Although studies have reported an association between quality of life and oral health condition[26-30], the correlation of the oral health status with the impact on personal satisfaction was scarcely investigated.[30] Considering that in Brazil, some studies showed rural residents presented worse oral health conditions compared to urban residents,[31,32] the present study aimed to evaluate the impact of oral health status on the quality of life and personal satisfaction among adolescents from urban and rural areas, in Nova Friburgo, Brazil.

MATERIAL AND METHODS

This cross-sectional study was reported according to the Strengthening the Reporting of Observational Studies in Epidemiology (STROBE) Statement.[33]

Ethical issues

Ethical approval was granted (2.015.179). Parents/guardians and the adolescents were informed about the research. Signed Informed consents were obtained from all individual participants included in the study.

Study design, setting and participants

This cross-sectional study was done as a census, with all the adolescents, between 11 and 14 years, enrolled in the schools participating in the HSP (Health in School Program) of Nova Friburgo, Rio de Janeiro, Brazil, at the year 2018. In addition to the informed consent to allow the participation of the adolescents in the study, guardians also received social economical questionnaires (ABEP and IBGE). The inclusion criteria corresponded to healthy adolescents, with complete permanent dentition, with or without the permanent third molars. Adolescents in orthodontic treatment using a fixed appliance or with special needs or in the mixed dentition period or whose clinical examination could not be performed were excluded. Moreover, adolescents that did not sign the informed consent form or whose guardians did not signed it, were also excluded.

Nova Friburgo is a Brazilian city in the state of Rio de Janeiro, Southeastern Brazil. Its estimated population in 2018 was 190,084 inhabitants. It is located in the north-central part of the state, 136 km from the capital.[34] In this municipality the Health in School Program (HSP) aims to contribute to the integral formation of students through actions of promotion, prevention and health care, addressing the vulnerabilities that compromise the full development of children and adolescents. At the present study, the rural schools were located far from downtown Nova Friburgo, in rural areas; in contrast, the urban schools, were at the center. According to the HSP coordination, a total of six schools presented schoolchildren with the focused age range, from 11 to 14 years old. Four schools were located in the urban area, and two in the rural area. The included schools represented all schools in the city for this age group.

Variables, measurements

First phase: epidemiological survey of oral health

The DMFT index is recommended to record the experience of caries in each population[35] and is the most used index for epidemiological surveys.[36] However it does not allow the detection of the clinical consequences of untreated carious lesions.[35-39] Thus, the PUFA index,[40] which evaluates the presence of pulpal involvement (P), ulceration caused by dislocation fragments (U), fistula (F), and abscess (A), was also used at the present study with the objective of determining the prevalence and recording the severity of the consequences of untreated caries lesions, as a complement to the DMFT.

The epidemiological survey of adolescent´s oral health, was performed by a single trained and calibrated examiner (HMC) with excellent values (Kappa intra and inter equal 1) for both DMFT and PUFA indexes. Initially, the examiner (HMC) participated in a training and discussion

session with an experienced researcher (MMA) and the calibration process was carried out with three adolescents presenting several scores for DMFT index. Then, the calibration process was conducted with five adolescents also presenting several scores for DMFT index, in two distinct periods with a week interval. After the signature of the consent terms of adolescents and collection of personal data, the visual clinical examination was performed in school desks, using only natural light, with tongue depressor and following the recommendation of the indexes: DMFT[35] and PUFA[40], and the biosafety standards. Based on the evaluation of the DMTF and PUFA indexes, the following categorization of the sample was done in relation to the oral health condition of each individual, so the groups were denominated: Group 1 (G1) – DMFT and PUFA with score 0 for both, Group 2 (G2) – score e" 1 of the DMTF index and PUFA = 0 and Group 3 (G3) – DMTF and PUFA with score e" 1 for both. Besides this, the Dental Treatment Needs Index (DTNI)[41], was also applied in the same conditions, allowing an evaluation of the oral status. The codes were grouped, forming 2 groups: without need for treatment (WNT) and need for treatment (NT).

Second phase: Quality of life and personal satisfaction assessments

Short and validated version CPQ[11-14] questionnaire[22,23] was applied as an interview to all participants. This instrument contains 16 questions corresponding to four domains: oral symptoms (04 questions), function limitation (04 questions); emotion well being (04 questions) and social well being (04 questions). Each question has five alternatives of answer; each presented a certain score, ranging from 0 to 4 points. In the overall sum the score of the instrument could vary from 0 to 64. Higher scores revealing higher negative impact of the oral conditions in the adolescent's quality of life. The instrument also contains global classifications of the oral health and how this condition can affect her/his general well being.

For the personal satisfaction evaluation, the instrument adopted was the Subjective Happiness Scale (SHS) Lyubomirsky, Lepper (1999)[24], translated by Rodrigues, Silva (2010)[25], which can globally measure the subjective happiness by the two components: affective (degree in which pleasant affective experiences weigh more than unpleasant, in a general way) and cognitive (degree in which the individual realizes the understanding of their needs). The count can range from 1 to 7, with higher values corresponding to better personal satisfaction. Both instruments were applied by a single examiner (HMC) in the form of an interview, directly to the adolescents, in a reserved room in the school environment.

Data analysis, statistical methods

The data were categorized and evaluated using the statistical software SPSS® (Statistical Package for the Social Sciences®, Version 21.0, Chicago, USA). Statistical tests were performed to compare nominal variables (Chi-Square and Fisher's exact test), to compare independent samples and their numerical variables (Mann-Whitney) and to compare two or more independent samples with the same or different sizes (Kruskal Wallis). The level of significance adopted was 5% (p<0.05).

RESULTS

Participants

At all the six schools of the HSP program of the city, 509 informed consent terms and social economical questionnaires, corresponding to the eligible participants considering the universe of students of the required age group, were sent to those guardians, by the schools. During a period of 30 days, 194 (38%) signed and filled terms and questionnaires were obtained. Thirty-three adolescents were excluded because they were in the mixed dentition period. The final sample comprised 161 adolescents, 104 from urban area and 57 from rural area that fitted the inclusion criteria. The distribution and characterization of the sample was described in table 1.

Outcome data and main results

Comparing oral health status and economic condition it was observed that the majority of the families were in the medium economical class (levels C and D) and the majority in the G1 (with score 0 for both DMFT and PUFA), but without significant statistical difference (p<0.151). When the adolescents were divided in relation to their oral health condition, and comparing them by rural and urban areas, it was observed that the majority were in the G1, in both areas: 57 (54.8%) in urban and 39 (68.4%) in rural area (Table 2), without statistical significant differences between the distribution by areas and the oral health condition (p<0.233).

Comparing quality of life and personal satisfaction between areas, both evaluations obtained significant results. The mean value of quality of life in relation to oral health conditions disclosed for the urban adolescents (11.88) were higher than those from the rural (8.91), indicating a lower impact of the oral conditions on the quality of life for the last population (p<0,010). On the other hand, in relation to personal satisfaction, the urban adolescents had more personal satisfaction (mean = 4.58), compared to rural adolescents (mean = 4.14) (p<0.001), considering that higher values mean better personal satisfaction. Crossing quality of life with and oral health status (G1, G2, G3) between demographic areas, there was no statistically significant difference, regardless of the area. However, it was observed

***Table 1**: Distribution and characterization of the sample.*

Variables		Urban area n=104 (%)	Rural area n=57 (%)	Total n=161 (%)
Sex	Male	38 (36.5%)	26 (45.6%)	64 (39.8%)
	Female	66 (63.5%)	31 (54.4%)	97 (60.2%)
Age (years)	11	9 (8.7%)	8 (14.0%)	17 (10.6%)
	12	32 (30.8%)	17 (29.8%)	49 (30.4%)
	13	38 (36.5%)	17 (29.8%)	55 (34.2%)
	14	25 (24.0%)	15 (26.3%)	40 (24.8%)
Skin color	White	54 (51.9%)	42 (73.7%)	96 (59.6%)
	Black	20 (19.2%)	5 (19.2%)	25 (15.5%)
	Brown	21 (20.2%)	7 (12.3%)	28 (17.4%)
	Others	9 (8.7%)	3 (5.3%)	12 (7.5%)
Economic class	A	–	–	–
	B	9 (8.7%)	2 (3.5%)	11 (6.8%)
	C	81 (77.9%)	36 (63.2%)	117 (72.7%)
	D	12 (11.5%)	18 (31.6%)	30 (18.6%)
	E	2 (1.9%)	1 (1.8%)	3 (1.9%)

***Table 2**: Adolescent's distribution in relation to the oral health condition and areas of Nova Friburgo city (RJ).*

Oral health condition		G1	G2	G3	*P value*
Area	Urban (n=104)	57(54.8%)	33(31.7%)	14(13.5%)	<0.233*
	Rural (n=57)	39(68.4%)	12(21.1%)	6(10.5%)	
Total (N=161)		96(59.6%)	45(28.0%)	20(12.4%)	

*Note: (G1) – DMFT and PUFA with score 0 for both, (G2) – score ≥ 1 of the DMTF index and PUFA = 0, (G3) – DMTF and PUFA with score ≥ 1 for both *Chi-square test.*

***Table 3**: Mean values of quality of life in relation to oral health condition between urban and rural areas of Nova Friburgo city (RJ).*

Instrument	Gravity	Urban	Rural
CPQ [11-14]	G1	10.19	7.82
	G2	13.64	7.25
	G3	14.64	19.33
	P value	<0.110*	<0.113*

*Note: (G1) – DMFT and PUFA with score 0 for both, (G2) – score ≥ 1 of the DMTF index and PUFA = 0, (G3) – DMTF and PUFA with score ≥ 1 for both * Kruskal Wallis test.*

***Table 4**: Mean values of personal satisfaction in relation to oral health condition between areas of Nova Friburgo city (RJ).*

Instrument	Gravity	Urban	Rural
SHS	G1	4.55	4.13
	G2	4.53	3.85
	G3	4.85	4.79
	P value	<0.151*	<0.070*

*Note: (G1) – DMFT and PUFA with score 0 for both, (G2) – score ≥ 1 of the DMTF index and PUFA = 0, (G3) – DMTF and PUFA with score ≥ 1 for both * Kruskal Wallis test.*

a trend for worsening the quality of life as an effect of unfavorable oral health conditions, in both areas, especially in rural (Table 3).

The Dental Treatment Needs Index (DTNI) and the variables of quality of life and personal satisfaction were also crossed, regardless of where they live. In relation to quality of life, the adolescents from the group WNT had better values (9.21) than the other group (15.59), being this difference statistically significant (p<0.001). In addition, regarding personal satisfaction, there was no statistically significant difference among adolescents that needed (4.71) or not treatment (4.82), also in both areas (p<0.404). When the impact on oral health status (G1, G2, G3) was analyzed on the personal satisfaction between urban and rural areas, the difference was not significant, as well as there was no relation between this variable and the grievance on the oral health condition (Table 4).

DISCUSSION

The majority of the sample comprised females and with white color, a result different from that found in a systematic review conducted in Brazil, where browns/blacks were the most observed in studies related to oral health[36]. This sample characteristic can be justified by the predominantly European colonization of the Nova Friburgo city, located in the mountain region. About the economic aspects, most families belonged to the medium class, which was also observed when the sample was divided by demographic area. Regarding the oral health condition, most of them did not present dental caries, and in this sense, the phenomenon of dental caries polarization[6] was observed, possibly due to preventive strategies implemented by the Health in School Program. In addition, comparing the two variables, oral health conditions and economic aspects, there was no direct relationship, corroborating with studies that point out a higher occurrence of dental caries among lower income groups, since children from areas lacking financial resources were more likely to have dental caries.[36,42,43]

One of the purposes of the present study was to search for a possible association between demographic area and oral health condition. It was observed that most of the sample was in the G1 group in both regions, showing good oral health conditions. Therefore, dental caries and its consequences were observed in 40.4% of the sample, being lower than the last national survey, which showed that 56.5% of Brazilian adolescents with caries experience. When comparing the areas of the southeast region, where the city is located, those with caries experience were found mostly in the urban area, similarly with this survey.[8]

Interestingly, in other countries, some studies revealed that the overall experience of caries was similar both in rural and urban areas, however higher in rural areas.[44,45,46] According to the aforementioned literature, the greatest involvement by the disease is in rural areas. Conversely, the results in the present study revealed that the urban area had worse oral health status. However, there was no statistical difference between areas, since most of the students did not present dental caries. As the HSP program performs health actions in these schools, it can be assumed that this fact may have influenced the results obtained.

Regarding the focused population, studies are usually conducted on a school environment, which reinforces the need for written authorizations of those responsible, as an ethical prerequisite. Nevertheless, some studies have already pointed the difficulty of obtaining such authorizations in studies conducted on adolescents.[47,48] In this sense, at the present study, a low rate of returning of the terms/questionnaires (38%) was observed, which could be considered a research limitation. Moreover, no studies with the same methodology used, were retrieved in the literature, which hindered a comparison across studies. In any case, more studies with larger samples are needed, especially in relation to personal satisfaction or subjective well being, since it is a new measure of evaluation. Taken together the limitations, the results of the presented study should not be extrapolated to other populations.

Studies have shown a direct relationship between the oral health status and the quality of life.[26-28] Similar results were observed in the present study. On the other hand, a relationship between the oral health status and the personal satisfaction was not disclosed. It is worth mentioning that this issue has still been scarcely reported, although some studies demonstrated that oral conditions and quality of life affect happiness,[30,49] and could be considered important predictors of happiness.[49] Nonetheless, a correlation was disclosed between the scores on the subjective happiness scale and the general CPQ11-14 scores,[30] and a similar association was disclosed by Yoon *et al.*, (2013)[49] with an elderly population, which do not corroborate with the present study results.

Regarding the Dental Treatment Needs Index (DTNI) and the variables of quality of life and personal satisfaction, it was observed that the adolescents from the group without treatment needs showed better quality of life; while, curiously, no difference was disclosed in relation to personal satisfaction. In addition, comparing quality of life and personal satisfaction between areas, rural adolescents showed better quality of life, while urban adolescents showed slightly higher personal satisfaction. Nevertheless, aiming to contribute to the oral health and quality of life of those with treatment needs, the

clinical and epidemiological data collected were presented to the responsible and participants were referred to dental treatment, at the local School of Dentistry.

CONCLUSION

According to the results of the present study, the adolescent´s oral health condition tended to have a negative impact on the quality of life, while it did not present a relation with the personal satisfaction, independent of the demographic area (urban or rural) of the adolescents of the Nova Friburgo city.

REFERENCES

1. Petersen PE, Bourgeois D, Ogawa H, Estupinan-Day S, Ndiaye C. The global burden of oral diseases and risks to oral health. Bulletin of the World Health Organization. 2005 83(9):661-669.
2. Baelum V, Helderman WH, Hugoson A, Yee R, Fejerskov O. A global perspective on changes in the burden of caries and periodontitis: implications for dentistry. J. Oral Rehabil. 2007 34(12):872- 906. doi: 10.1111/j.1365-2842.2007.01799.x.
3. Petersen PE: World Health Organization global policy for improvement of oral health – World Health Assembly 2007. Int. Dent. J. 2008 58(3):115-121. doi: 10.1111/j.1875-595x.2008.tb00185.x.
4. Kassebaum NJ, Bernabé E, Dahiya M, Bhandari B, Murray CJ, Marcenes W. Global burden of untreated caries: a systematic review and metaregression. J. Dent. Res. 2015 94(5):650-658. doi: 10.1177/0022034515573272.
5. Kazemina M, Abdi A, Shohaimi S, Jalali R, Vaisi-Raygani A, Salari N, Mohmmadi M. Dental caries in primary and permanent teeth in children's worldwide, 1995 to 2019: a systematic review and meta-analysis. Head Face Med. 2020 16:22. doi: 10.1186/s13005-020-00237-z.
6. Narvai PC, Frazão P, Roncalli AG, Antunes JLF. Cárie dentária no Brasil: declínio, polarização, iniquidade e exclusão social. Pan Am J Public Health. 2006 19(6):385–393.
7. Beaglehole R, Benzian H, Crail J, Mackay J. The oral health Atlas. Mapping a neglect global health issue Brighton, UK: Myriad Editions for FDI World Dental Federation, 2009.
8. Brasil. Ministério da Saúde. Secretaria de Atenção à saúde. Secretaria de Vigilância em Saúde. SB Brasil 2010: Pesquisa Nacional de Saúde Bucal: resultados principais. Brasília: Ministério da Saúde 2012:116.
9. Saintrain MV, Correa CRS, Saintrain SV, Nuto S, Vieira-Meyer APGF. Brazilian adolescents' oral health trends since 1986: an epidemiological observational study. BMC Research Notes. 2015 8:554. doi: 10.1186/s13104-015-1538-5.
10. Mejàre I, Stenlund H, Zelezny-Holmlund C. Caries incidence and lesion progression from adolescence to young adulthood: a prospective 15-year cohort study in Sweden. Caries Res. 2004 38(2):130-141.
11. Miller J, Vaughan-Williams E, Furlong R, Harrison L. Dental caries and children's weights. J Epidemiol Community Health. 1982 6(1):49- 52. doi: 10.1159/000075937.
12. Ayhan H, Suskan E, Yildirim S. The effect of nursing or rampant caries on height, body weight and head circumference. J Clin Pediatr Dent. 1996 20(3):209-212.
13. Sheller B, Williams BJ, Lombardi SM. Diagnosis and treatment of dental caries-related emergencies in a children's hospital. Pediatr Dent. 1997 19(8):470-475.
14. Gradella CMF, Oliveira LB, Ardenghi TM, Bönecker M. Epidemiologia da cárie dentária em crianças de 5 a 59 meses de idade no município de Macapá, AP. RGO (Porto Alegre). 2007 55(4):329-334.
15. Moura-Leite FR, Ramos-Jorge ML, Bonanato K, Paiva SM, Vale MP, Pordeus IA. Prevalence, intensity and impact of dental pain in 5-year-old preschool children. Oral Health Prev Dent. 2008 6(4):295-301.
16. Pourat N, Nicholson G. Unaffordable dental care is linked to frequent school absences. Los Angeles, CA: UCLA Center for Health Policy Research, 2009.
17. WHO (1948). World Health Organization Constitution. Geneva, Switzerland: World Health Organization; Available at: http://www.who.int/governance/eb/who_constitution_en.pdf
18. Bonomi AE, Patrick DL, Bushnell DM, Martin M. Validation of the United States version of the World Health Organization Quality of Life (WHOQOL) instrument. J Clin Epidemiol 2000 53:1-12. doi: 10.1016/s0895-4356(99)00123-7.
19. DHHS Department of Health and Human Services. Oral health in America: a report of the Surgeon General. US Department of Health and Human Services and National Institute of Dental and Craniofacial Research Rockville, MD: National Institutes of Health, 2000.
20. Jokovic A, Locker D, Stephens M, Kenny D, Tompson B, Guyatt G. Validity and reliability of a questionnaire for measuring child oral- health-related quality of life. J Dent Res. 2002 81(7):459–463. doi: 10.1177/154405910208100705.
21. Jokovic A, Locker D, Tompson B, Guyatt G. Development and evaluation of a questionnaire for measuring oral-health-related quality of life in 8–10-year-old children. Pediatr Dent. 2004 26(6):512-518.
22. Jokovic A, Locker D, Guyatt G. Short forms of the Child Perceptions Questionnaire for 11-14-year-old children (CPQ11-14): development and initial evaluation. Health Qual Life Outcomes. 2006 4:4. doi: 10.1186/1477-7525-4-4.
23. Torres CS, Paiva SM, Vale MP, Pordeus IA, Ramos-Jorge ML, Oliveira AC, Allison PJ. Psychometric properties of the brazilian version of the Child Perceptions Questionnaire (CPQ11–14) – Short Forms. Health Qual Life Outcomes 2009 7:43-49.
24. Lyubomirsky S, Lepper HS. A measure of subjective happiness: Preliminary reliability and construct validation. Social Indicators Research. 1999 46(2)137-155. doi.org/10.1023/A:1006824100041
25. Rodrigues A, Silva J A. O papel das características sociodemográficas na felicidade. Psico-USF. 2010 15(1):113-123. doi.org/10.1590/S1413-82712010000100012.
26. Low W, Tan S, Schwartz S. The effect of severe caries on the quality of life in young children. Pediatr Dent. 1999 1(6):325-326.
27. Piovesan C, Antunes JL, Guedes RS, Ardenghi TM. Impact of socioeconomic and clinical factors on child oral health-related quality of life (cohrqol). Qual Life Res. 2010 19(9):1359-1366. doi: 10.1007/s11136-010-9692-7.
28. Scapini A, Feldens CA, Ardenghi TM, Kramer PF. Malocclusion impacts adolescents' oral health-related quality of life. Angle Orthod. 2013 83(3):512-518. doi: 10.2319/062012-509.1.
29. Praveen BH, Prathibha B, Reddy PP, Monica M, Samba A, Rajesh R. Co Relation between PUFA Index and Oral Health Related Quality of Life of a Rural Population in India: A Cross-Sectional Study. J Clin Diagn Res. 2015 9(1):ZC39-ZC42.
30. Tuchtenhagen S, Bresolin CR, Tomazoni F, da Rosa GN, del Fabro JP, Mendes FM, Antunes JL, Ardenghi TM. The influence of normative and subjective oral health status on schoolchildren's happiness. BMC Oral Health. 2015 15:15. doi.org/10.1186/1472-6831-15-15.

31. Antunes JLF, Peres MA, Mello TRD, Waldman EA. Multilevel assessment of determinants of dental caries experience in Brazil. Community Dent and Oral Epidemiol. 2006 34(2):146-152.
32. Mello TRD, Antunes JLF, Waldman EA. Prevalence of untreated caries in deciduous teeth in urban and rural areas in the state of Sao Paulo, Brazil. Pan American Journal of Public Health. 2008 23:78-84.
33. von Elm E, Altman DG, Egger M, Pocock SJ, Gotzsche PC, Vandenbroucke JP. Strengthening the Reporting of Observational Studies in Epidemiology (STROBE) Statement: guidelines for reporting observational studies. BMJ. 2007 20(335):806-808. doi.org/10.1136/bmj.39335.541782.AD
34. IBGE, Área territorial brasileira. Rio de Janeiro: IBGE, 2018.
35. World Health Organization (WHO). Oral health survey: basic methods, Geneva, 4th ed., 1997.
36. Boing AF, Bastos JJ, Peres KG, Antunes JLF, Peres M.A. Social determinants of health and dental caries in Brazil: a systematic review of the literature between 1999 and 2010. Rev Bras Epidemiol Suppl D.S.S. 2014 102-115. doi.org/10.1590/1809-4503201400060009
37. Fejerskov O, Kidd E. Cárie Dentária – A Doença e seu Tratamento Clínico. São Paulo: Santos; 2005.
38. Manji F, Fejerskov O, Baelum V, Luan W-M, Chen X. The epidemiological features of dental caries in African and Chinese populations: implication for risk assessment. In: Johnson NW editor. Risk markers for oral diseases, Dental caries markers for high and low risk groups and individuals. Cambridge: Cambridge University Press. 1991 62-100.
39. Pine C, Harris VR, Burnside G, Merrett MCE. An investigation of the relationship between untreated decayed teeth and sepsis in 5-year-old children. British Dent J 2006 200:45-47. doi: 10.1038/sj.bdj.4813124.
40. Monse B, Heinrich-Weltzien R, Benzian H, Holmgren C, Helderman W. PUFA – An index of clinical consequences of untreated dental caries. Community Dent Oral Epidemiol. 2010 38(1):77-82.
41. Dumont AFS, Salla JT, Vilela MBL, Morais PC, Lucas SD. Índice de necessidade de tratamento odontológico: o caso dos índios Xakriabá. Ciência & Saúde Coletiva. 2008 13(3):1017-1022. doi.org/10.1590/S1413-81232008000300024.
42. Sweeney PC, Gelbier S. The dental health of pre-school children in a deprived urban community in Glasgow. Community Dent Health. 1999 16(1): 22-25.
43. Tapias MA, De-Miguel G, Jiménez-Garcia R, Gonzalez A, Domínguez V. Incidence of caries in an infant population in Mostoles, Madrid. Evaluation of a preventive program after 7.5 years of follow-up. Int J Paediatr Dent. 2011 11(6):440-446. doi: 10.1046/j.0960-7439.2001.00307.x.
44. Gorbatova MA, GOrbatova LN, GrjibovskI AM. Dental caries experience among 15-year-old adolescents in north-west Russia. Int J Circumpolar Health. 2011 70(3):232-235.
45. Gorbatova MA, Gorbatova LN, Pastbin MU, Grjibovski AM. Urban-rural differences in dental caries experience among 6-year-old children in the Russian north. Rural Remote Health. 1999 12:2012. doi: 10.3402/ijch.v70i3.17824
46. Giacaman RA, Bustos IP, Bravo-león V, Mariño RJ. Impact of rurality on the oral health status of 6-year-old children from central Chile: the EpiMaule study. Rural Remote Health. 2015 15(2):3135,.
47. Pereira A, Williams L, Bem F. Consentimento dos Pais em Pesquisas com Escolares e a Legislação Brasileira. Interação Psicol. 2012 16(1):51-61.
48. Borges J, Dell'aglio D. Desafios éticos na pesquisa com adolescentes: implicações da exigência do consentimento parental. Rev. SPAGESP. 2017 18(2):43-57.
49. Yoon HS, Kim HY, Patton LL, Chun JH, Bae KH, Lee MO. Happiness, subjective and objective oral health status, and oral health behaviors among Korean elders. Community Dent Oral Epidemiol. 2013 41(5):459-465. doi: 10.1111/cdoe.12041.

INFLUENCE OF CIGARETTE SMOKE ON ENAMEL COLOR STABILITY AFTER ORTHODONTIC DEBONDING: AN IN VITRO STUDY

Flávio de Mendonça **Copello**[1], André Ramos **Losso**[1], Kelly Galisteu **Luiz**[1], Larine Ferreira **Lira**[1], Amanda Cunha Regal de **Castro**[1], Mônica Tirre de Souza **Araujo**[1*]

[1]Department of Pediatric Dentistry and Orthodontics, School of Dentistry, Universidade Federal do Rio de Janeiro, Rio de Janeiro, RJ, Brazil.

Palavras-chave: Descolagem Dentária. Estética Dentária. Fumar Cigarros. Ortodontia.

RESUMO

Objetivo: O objetivo deste estudo foi avaliar a estabilidade da cor do esmalte dentário exposto à fumaça de cigarro após a descolagem ortodôntica. **Métodos**: Trinta e dois incisivos bovinos foram alocados nos grupos controle (C_1 and C_2) e experimental (n = 8) de acordo com protocolos de colagem ortodôntica distintos: com adesivo (B_1) e sem adesivo (B_2) e expostos à fumaça de cigarro. Amostras do B_1, B_2 e C_2 foram expostas a dez ciclos de fumaça em uma câmara específica e hermética, enquanto o C_1 permaneceu armazenado em saliva artificial. A análise da estabilidade de cor foi realizada com um espectrofotômetro de acordo com o sistema L* a* b*. As comparações intergrupos e o efeito do tempo foram verificados com ANOVA / Tukey e testes t de Student, respectivamente (a=0,05). **Resultados:** Não foram observadas alterações de cor estatisticamente significativas no C_1 (L*: -0,69 ± 0,80; a*: 0,36 ± 0,23; b*: 0,17 ± 0.50) e sem adesivo (B_2) (L*: -3,74 ± 2,85; a*: 0,93 ± 0,73; b *: 1,13 ± 1,16) durante o tempo de estudo (p>0,05). No entanto, o grupo com adesivo (B_1) apresentou alterações significativas de cor em L*: - 5,55 ± 2,28, a*: 2,33 ± 0,77 eb*: 3,30 ± 1,37, o que significa, mais escuro, mais verde e mais amarelo, respectivamente (p<0,05) e o grupo controle exposto à fumaça de cigarro (C_2) apresentou alterações significativas de cor em L*: -1,72 ± 0,28 e b*: 1, 82 ± 0,22, o que significa, mais escuro e mais amarelo, respectivamente. **Conclusão**: A estabilidade da cor do esmalte foi afetada pela exposição à fumaça de cigarro após a descolagem ortodôntica, principalmente quando o protocolo de colagem incluía a aplicação de adesivo.

Keywords: Dental Debonding. Dental Esthetics. Cigarette Smoking. Orthodontics.

ABSTRACT

Objective: The aim of this study was to evaluate the color stability of dental enamel exposed to cigarette smoke after orthodontic debonding. **Methods**: Thirty-two bovine incisors were allocated into control (C_1 and C_2) and experimental groups (n=8) according to distinct bonding protocols: with adhesive (B_1) and without adhesive (B_2) and exposure to cigarette smoke. Samples from B_1, B_2 and C_2 were exposed to ten cycles of smoke in a specific and hermetic chamber while the C_1 remained stored in artificial saliva. Color analysis was performed with a spectrophotometer according to the L*a*b* system. Intergroup comparisons and effect of time were estimated with ANOVA/Tukey and paired Student t tests, respectively (a=0.05). **Results**: Statistically significant color changes have not been observed in C_1 (L*: -0.69 ± 0.80; a*: 0.36 ± 0.23; b*: 0.17 ± 0.50) and without adhesive (B_2) (L*: -3.74 ± 2.85; a*: 0.93 ± 0,73; b*: 1.13 ± 1.16) through the study time (p>0,05). However, the group with adhesive (B_1) presented significant color changes in L*:-5.55 ± 2.28, a*: 2.33 ± 0.77 and b*: 3.30 ± 1.37, what means, darker, greener and more yellow, respectively (p<0,05) and the control group that was exposed to the cigarette smoke (C_2) presented significant color changes in L*: -1.72 ± 0.28 e b*: 1.82 ± 0.22, what means, darker and more yellow, respectively. **Conclusion**: Enamel color stability was affected by exposure to cigarette smoke after orthodontic debonding, especially when bonding protocol comprised the application of primer adhesive.

Submitted: Jul 17, 2020
Modification: Sep 14, 2020
Accepted: Oct 14, 2020

***Correspondence to:**
Mônica Tirre de Souza Araujo
Address: Department of Pedodontics and Orthodontics, Universidade Federal do Rio de Janeiro, (UFRJ). Avenida Professor Rodolpho Paulo Rocco, 325, Ilha do Fundão, Rio de Janeiro, RJ, Brazil. Zip Code: 21941-617
Telephone Number: +55 21 3938-2015
E-mail: monicatirre@uol.com.br

INTRODUCTION

The introduction of the acid etching technique in Orthodontic field improved the evolution of orthodontic brackets bonding. In this perspective, one of the main concerns is that at the end of the orthodontic therapy, the enamel surface presents similar conditions as before treatment.[1]

After orthodontic debonding, composite residues remain on enamel surface and some studies have shown that irreversible penetration of resin tags in the enamel structure occurs during brackets bonding protocol. The composite material can infiltrate dental structure from 11.8 µm to 18.9 µm, sometimes reaching up to 100 µm.[2-4] Residual adhesive can remain on the tooth even if an enamel layer is removed during debonding protocol.[5]

Despite composite resins are the first choice when dental aesthetics is required, these materials present limitations such as surface roughness and porosity, associated to staining[6] and infiltration of food dyes and cigarette residues, reducing the longevity of aesthetic treatments.[7]

It is known that there are about 1 billion of smokers all over the world, of which high consumption rates are related to teenagers. And it is associated with oral cancer and enamel staining[8]. There some studies reporting the influence of cigarette smoke as a staining agent for aesthetic biomaterials,[9-11] study by Omar et al. 2020[12] investigated the influence of cigarette smoke on shear bond strength regarding to brackets, but there are no studies relating cigarette smoke with orthodontic bonding materials and the effects on aesthetic after debonding procedures.

It is hypothesized that patients undergoing orthodontic treatments with fixed appliances, and, who are also cigarette users may have a higher chance of enamel staining after orthodontic brackets debonding. Thus, the aim of this study was to evaluate, in vitro, the color stability of dental enamel exposed to cigarette smoke after orthodontic brackets debonding.

MATERIAL AND METHODS

Sample

This study was approved by the Animal Ethics Committee of the Center of Health Sciences of the Universidade Federal do Rio de Janeiro under protocol number 01200.001568/2013-87.

According to a prior pilot study, a power sample analysis based on the formula described by Pandis[13] considered a minimum of eight samples per group for detecting difference between means of 5 (for parameter L of color stability from the CIL*a*b* system) with standard deviation of 2.1 (a=5% and study power = 80%).

Thirty-two bovine incisors, obtained from a certified slaughterhouse, were selected for this study. Dental crowns were separated from the root using a diamond disc (KG Sorensen, Cotia, São Paulo, Brazil), inserted in a PVC cylindrical fragment (25 mm x 20 mm - Lusafilm- Dispafilm do Brasil Ltda, São Paulo, Brazil) so that the buccal crown surface was perpendicular to the PVC matrix; and fixed with a self-curing acrylic resin (JET, Classic Dental Articles LTDA, Campo Limpo Paulista, São Paulo, Brazil). Then the buccal surface was sanded with sandpapers No. 400, 600 and 1200 (3M, Sumaré, São Paulo, Brazil) under water irrigation (30 seconds each) on a Politriz machine (Ecomet II, Buehler, Illinois, USA) so that flat, smooth and polished surfaces were obtained. The samples were stored in distilled water at 37°C. The entire procedure was performed by the same operator (A.R.S.).

Samples were allocated into control and experimental groups (n = 8) according to orthodontic bonding protocol and cigarette smoke exposure (Table 1). Edgewise brackets (0.022-in) (Morelli, Sorocaba, SP, Brazil) were bonded to experimental groups, under the following protocols: B_1 - phosphoric acid 37% (Nova DFL, Rio de Janeiro, RJ, Brazil), primer adhesive (Transbond XT Light Cure Adhesive Primer, 3M Unitek, Monrovia, CA, USA) and Transbond XT Light Cure Adhesive Paste composite (3M Unitek, Monrovia, CA, USA); and B_2 - phosphoric acid 37% (Nova DFL, Rio de Janeiro, RJ, Brazil) and Transbond XT Light Cure Adhesive Paste composite (3M Unitek, Monrovia, CA, USA) (Figure 1). Control groups were not submitted to orthodontic bonding, and allocated into C_1 and C_2 according to non-exposure and exposure to cigarette smoke, respectively.

***Table 1**: Groups division according to bonding protocol and exposure to cigarette smoke.*

GROUPS	BONDING PROTOCOL	SMOKE EXPOSURE
B_1	Bonding protocol with primer adhesive	Yes
B_2	Bonding protocol without primer adhesive	Yes
C_1	No bonding protocol	No
C_2	No bonding protocol	Yes

Note: B_1, Bonding protocol with primer adhesive exposed to cigarette smoke; B_2, Bonding protocol without primer adhesive exposed to cigarette smoke; C_1, No bonding protocol without smoke exposure; C_2, No bonding protocol with smoke exposure.

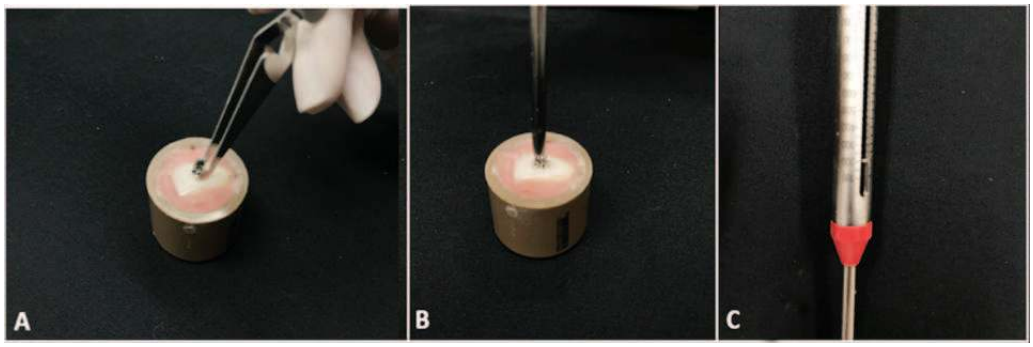

***Figure 1**: Photographs illustrationg bonding brackets procedure: A) Bracket positioning with bracket holder tweezers. B) Standardization of bonding pressure by using a tensiometer with 200gF. C) Tensiometer scale set at 200gF.*

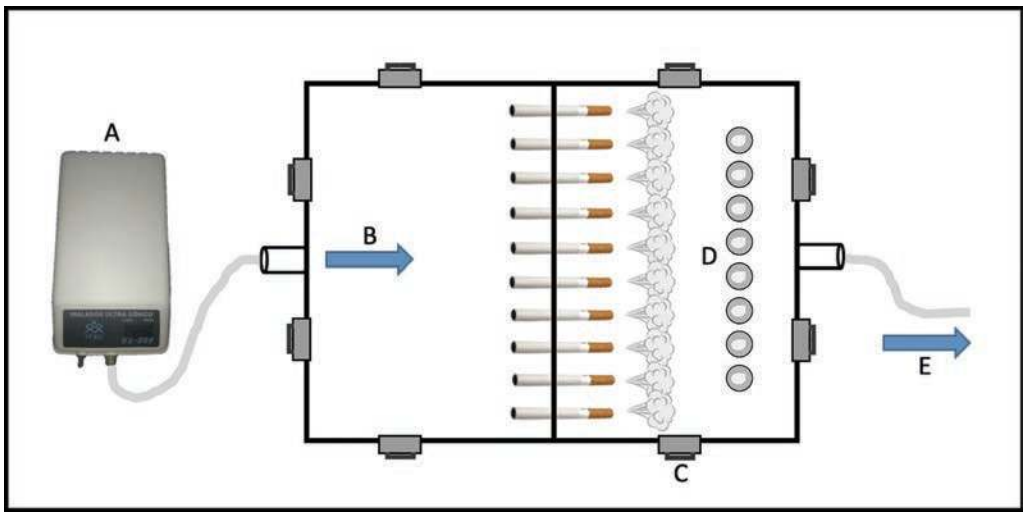

***Figure 2**: Illustrative drawing of the hermetic chamber used for cigarette smoke exposure. A) Nebulizer used to oxygen injection into the chamber. B) Entrance of oxygen enabling cigarettes to remain lit. C) Clamps for keeping hermetic environment inside the camera. D) Samples positioned in front of the cigarettes smoke. E) Cigarettes suction system.*



***Figure 3**: Photographs illustrating colorimetric analysis. A) Previous device calibration. B) Equipment positioning on the dental surface. C) Device holder enabling a standardized position during the analysis. D) Results displayed in spectrophotometer display.*

***Table 2**: Descriptive statistics as mean and standard deviation for the parameters L*, a*, b* and its conversion to NBS units.*

Groups		L *		
	T0	**T1**	**T1-T0**	***p-value* (T1-T0)**
C_1	89.01 ± 1.56[a]	88.32 ± 1.67[c]	-0.69 ± 0.80	0.195
C_2	88.28 ± 1.27[a]	86.56 ± 0.28[b]	-1.72 ± 0.28*	0.001
B_1	87.77 ± 2.26[a]	82.21 ± 1.21[a]	-5.55 ± 2.28*	0.000
B_2	87.32 ± 1.66[a]	84.96 ± 2.15[b]	-3.74 ± 2.85	0.892
		a *		
	T0	**T1**	**T1-T0**	
C_1	3.13 ± 0.51[a]	3.80 ± 0.68[a]	0.36 ± 0.23	0.977
C_2	2.98 ± 0.26[a]	3.04 ± 0.33[a]	0.69 ± 0.82	0.248
B_1	2.68 ± 0.94[a]	4.27 ± 0.88[b]	2.33 ± 0.77*	0.001
B_2	2.86 ± 0.63[a]	3.49 ± 0.50[a]	0.93 ± 0.73	0.806
		b *		
	T0	**T1**	**T1-T0**	
C_1	35.11 ± 1.16[a]	35.29 ± 1.03[a]	0.17 ± 0.50	0.432
C_2	34.12 ± 0.98[a]	36.28 ± 1.29[b]	1.82 ± 0.22*	0.000
B_1	35.54 ± 0.89[a]	38.85 ± 1.23[b]	3.30 ± 1.37*	0.002
B_2	35.19 ± 0.87[a]	36.83 ± 0.83[b]	1.13 ± 1.16	0.345
		NBS		
C_1		0.99 ± 0.55[a]		
C_2		2.98 ± 1.23[a]		
B_1		6.49 ± 1.98[b]		
B_2		3.07 ± 2.31[b]		

*Note: Different letters indicate significant intergroup differences (ANOVA/Tukey) (a= 0.05). *Indicates significant differences between study timepoints within each group (RM ANOVA) (a= 0.05). B_1, Bonding protocol with primer adhesive exposed to cigarette smoke; B_2, Bonding protocol without primer adhesive exposed to cigarette smoke; C_1, No bonding protocol without smoke exposure; C_2, No bonding protocol with smoke exposure.*

Exposure to cigarette smoke

An airtight chamber, designed specifically for this study purpose, was used to samples exposure to cigarette smoke. The chamber was divided into two compartments: one side where bovine teeth was positioned, and the opposite side, containing ten holes where the cigarettes were inserted with its filters facing the compartment in which the sample was positioned. Cigarette suction process was performed with a conventional suction cannula that was inserted into one of the compartments. Oxygen was injected in order to keep the cigarettes lit during the experiment. Five cigarette boxes (Rothmans cigarette, Souza Cruz, Rio de Janeiro, Brazil) were used in the study, as the samples went through ten cycles of exposure to cigarette smoke, and therefore comprising a total of 100 cigarettes (Figure 2).

Color Stability Analysis

The spectrophotometer Vita EasyShade Compactâ (Bad Säckingen Germany) was used to determine the initial color and detect possible color changes between the study timepoints. For this purpose, the spectrophotometer tip was positioned perpendicular to the buccal surface of the teeth (Figure 3). Color data were registered using the L* a* b* system, which comprises variation in the three-dimensional color axes: L* (luminosity), a* (red-green axis) and b* (yellow-blue axis). Color changes (ÄE) after exposure to smoke were calculated by the following equation: $ÄE^*ab=[(ÄL)^2 + (Äa)^2 + (Äb)2]^{1/2}$, where ÄL, Äa and Äb correspond to the differences between L*, a* and b* values assessed before and after the smoke exposure.

Clinical perception of color changes was calculated using the National Bureau of Standards (NBS) by the equation, NBS = ÄE* x 0.92, in which critical observations of color differences were expressed in NBS units. The higher the NBS, the greater was the clinical perception of color change.

Statistical Analysis

Statistical analysis was performed with the SPSS software (version 22, SPSS Inc, Chicago, IL, USA). Normality

of the sample was verified with the Shapiro-Wilk test. Intergroup comparisons and effect of time were performed with one-way ANOVA/Tukey and RM ANOVA tests. The level of significance of 5% was adopted for all analyses.

RESULTS

Color stability results are presented in Table 2. In T0 there was no statistical difference between the groups. Significant color changes were observed in B_1 (bonding protocol with primer adhesive) parameters: L* (T1-T0: -5.55 ± 2.28), a* (T1-T0: 2.33 ± 0.77) and b*(T1-T0: 3.30 ± 1.37) (P = 0.000), whereas no significant color changes were noticed in B_2 samples (bonding protocol without primer adhesive) (T1-T0: L*: -3.74 ± 2.85; a*: 0.93 ± 0.73; b*: 1.13 ± 1.16) (P>0.05). Regarding control groups, no statistically significant color changes were observed in C_1 (T1-T0: L*: -0.69 ± 0.80; a*: 0.36 ± 0.23; b *: 0.17 ± 0.50), which was stored in artificial saliva. However, C_2, that did not undergo orthodontic bonding protocol but was exposed to cigarette smoke had a statistically significant color change in parameters L * and b * (T1-T0: L *: -1.72 ± 0.28; b *: 1.82 ± 0.22) (P = 0.001 and 0.000, respectively).

Both B_1 and B_2 presented higher NBS values compared to C_1 and C_2 (B_1: 6.49 ± 1.98; B_2: 3.07 ± 2.31; C_1: 0, 99 ± 0.55; C_2: 2.98 ± 1.23) (P<0.05).

DISCUSSION

In this perspective, enamel and restorations staining resulting from smoking is the most immediate perceived clinical manifestation in smokers.[14] Once adolescents and young adults represent a large part of patients undergoing orthodontic treatment, this study is important because it is related to smile aesthetics.

Since color perception is subjective it requires quantitative parameters to be measured. Such parameters can be provided by spectrophotometry. Vita Easyshade Compact spectrophotometer is widely used for color evaluation of some materials, including aesthetic orthodontic wires.[15-17]

The literature agrees that resin residues can change tooth color through internal and external reactions, and that external discoloration may be associated to food-derived pigments absorption.[18,19] Furthermore, in addition to food, other pigments may be responsible for teeth extrinsic staining, such as cigarette smoke.[20] Probably the complex composition of cigarette smoke, comprising thousands of substances such as nicotine, carbon monoxide, tar, among others,[21] when in contact and subsequently deposited in the composite resin surface, would be responsible for the color and luminosity change. The greatest color and brightness change in B_1 could be attributed to the application of a primer adhesive during orthodontic brackets bonding protocol.

A study by Omar et al.[12], showed that cigarette consumption may influence the orthodontic brackets shear bond strength, and this is probably associated with the contact of the smoke with the bonding material exposed to the oral cavity. This shows that the cigarette can modify these bonding materials, and the present study shows that after debonding procedures, the residual material can also be modified, changing the color stability.

According to Manuja[21], the bonding interface between tooth and restoration remains the most susceptible area when exposed to the oral environment. This interface, known as the hybrid area, consists of a network of adhesive microleakages, which after polymerization become rigid, providing the micromechanical retention of the restoration. The difference of results between B_1 and B_2 seems to be related to the addition of the primer adhesive layer in bracket bonding protocol, since after light curing, the adhesive tags becomes rigid and difficult to be completely removed even after orthodontic debonding. Also, the porous surface inherent to resinous materials, might contributed to increased staining in B_1 than in B_2. Therefore, it may be suggested not to use the primer in smoker patients, since the contraindication for all patients may not be the best choice since the primer is associated with the success of the adhesive system, depending on the commercial brand.

Samples from control group exposed to cigarette smoke (C_2) also showed color changes, indicating that despite dental enamel is the most mineralized and, therefore, the hardest tissue in the human body, it has a certain degree of permeability.[22]

Evidences provided by this study are relevant for clinical practice, once it contributes to patients awareness of the influence of cigarette smoke on teeth staining during and after orthodontic treatment. Therefore, this information also contributes to cigarette use reduction, due to its aesthetic appeal, which is highly regarded by patients undergoing orthodontic treatment. Due to inherent limitations of in vitro studies, future studies using clinical controlled design are encouraged to confirm present study results.

CONCLUSION

Enamel color stability was affected by exposure to cigarette smoke after orthodontic debonding, especially when bonding protocol comprised the application of primer adhesive.

REFERENCES

1. Trakyali G, Özdemir FI, Arun T. Enamel colour changes at debonding and after finishing procedures using five different adhesives. The European Journal of Orthodontics, v. 31, n. 4, p. 397-401, 2009.
2. Diedrich P. Enamel alterations from bracket bonding and debonding: a study with the scanning electron microscope. American journal of orthodontics, v. 79, n. 5, p. 500-522, 1981.
3. Soares MLF, Chevitarese O. Sealant and resin viscosity and their influence on the formation of resin tags. The Angle Orthodontist, v. 64, n. 5, p. 383-388, 1994.
4. Silverstone LM, Saxton CA, Dogon IL, Fejerskov O. Variation in the pattern of acid etching of human dental enamel examined by scanning electron microscopy. Caries research, v. 9, n. 5, p. 373-387, 1975.
5. Zachrisson BU, Årthun J. Enamel surface appearance after various debonding techniques. American journal of orthodontics, v. 75, n. 2, p. 121-137, 1979.
6 .Costa GFD, Casemiro LA, Villela VR, Marangoni S. Manchamento de compósitos por alimentos. Investigação, v. 11, n. 1, 2011.
7. Domingues LA, Sakamoto FFO, Toma MH, Pegoraro CN. Selamentos superficiais influenciam no manchamento das resinas? Rev. Assoc. Paul. Cir. Dent, p. 321-325, 2001.
8. Vanka A, Roshan NM, Ravi KS, Shashikiran ND. A review of tobacco cessation services for youth in the dental clinic. Journal of Indian Society of Pedodontics and Preventive Dentistry, v. 27, n. 2, p. 78, 2009.
9. Zanetti F, Zhao X, Pan J, Peitsch MC, Hoeng J, Ren Y. Effects of cigarette smoke and tobacco heating aerosol on color stability of dental enamel, dentin and composite resin restorations. Quintessence Int, v. 50, n. 2, p. 156-166, 2019.
10. de Geus JL, Beltrame FL, Wang M, Avula B, Khan IA, Loguercio AD, Kossatz S, Reis A. Determination of nicotine content in teeth submitted to prophylaxis and in-office bleaching by gas chromatography–mass spectrometry (GC-MS). Clinical Oral Investigations, v. 22, n. 9, p. 3043-3051, 2018.
11. Copello FM, Nojima LI, Souza MMG, Pithon MM, Ruellas ACO, Castro ACR, et al. The influence of cigarette smoke on colour stability and friction property of aesthetic orthodontic wires—In vitro study. International Orthodontics, 2020.
12. Omar H, Haggag S, Ghoneima A. The effect of cigarette smoke on the shear bond strength of metallic and ceramic orthodontic brackets: An in vitro study. International Orthodontics, v. 18, n. 1, p. 121-126, 2020.
13. Pandis N. Sample calculations for comparison of 2 means. American journal of orthodontics and dentofacial orthopedics, v. 141, n. 4, p. 519-521, 2012.
14. Vogel, R. Intrinsic and extrinsic discoloration of the dentition.(A literature review). Journal of oral medicine, v. 30, n. 4, p. 99-104, 1975.
15. Lopes Filho H, Maia LEG, Araújo MVA, Ruellas ACO. Influence of optical properties of esthetic brackets (color, translucence, and fluorescence) on visual perception. American Journal of Orthodontics and Dentofacial Orthopedics, v. 141, n. 4, p. 460-467, 2012.
16. da Silva DL, Mattos CT, de Araújo MVA, de Oliveira Ruellas AC. Color stability and fluorescence of different orthodontic esthetic archwires. The Angle Orthodontist, v. 83, n. 1, p. 127-132, 2012.
17. Inami T, Tanimoto Y, Minami N, Yamaguchi M, Kasai K. Color stability of laboratory glass-fiber-reinforced plastics for esthetic orthodontic wires. The Korean Journal of Orthodontics, v. 45, n. 3, p. 130-135, 2015.
18. Faltermeier A, Behr M, Müßig D. In vitro colour stability of aesthetic brackets. The European Journal of Orthodontics, v. 29, n. 4, p. 354-358, 2007.
19. Faltermeier A, Rosentritt M, Reicheneder C, Behr M. Discolouration of orthodontic adhesives caused by food dyes and ultraviolet light. The European Journal of Orthodontics, v. 30, n. 1, p. 89-93, 2007.
20. Mccann D. Tobacco use and oral health. Journal of the American Dental Association (1939), v. 118, n. 1, p. 18, 1989.
21. Manuja N, Nagpal R, Pandit IK. Dental adhesion: mechanism, techniques and durability. Journal of Clinical Pediatric Dentistry, v. 36, n. 3, p. 223-234, 2012.
22. Fejerskov O, Thylstrup A. Embriologia e histologia oral humana. Barcelona: Salvat, 1989.

DENTAL MANAGEMENT FOR A CHILD WITH SMITH-MAGENIS SYNDROME UNDER GENERAL ANESTHESIA: CASE REPORT

Sara Kelly Gurjão **Farias**[1], Desirée de Jesus **Portelinha**[2], Mônica Almeida **Tostes**[2], Viviane de Andrade Cancio **de Paula**[2*]

[1]School of Dentistry, Universidade Salgado de Oliveira, Niterói, RJ, Brazil.
[2]Department of Pediatric Dentistry, School of Dentistry, Universidade Federal Fluminense, Niterói, RJ, Brazil.

Palavras-chave: Transtorno do Espectro Autista, Cárie Dentária, Genética, Síndrome de Smith-Magenis

RESUMO

Introdução: A síndrome de Smith-Magenis (SMS) é uma doença genética caracterizada por uma deficiência neuro-comportamental causada por mutações ou deleções no locus 17p11.2 compreendendo o gene 1 induzido por ácido retinóico (RAI1). O diagnóstico é feito por meio de análises clínicas em busca de características e para comprovar essa suspeita, é necessária a técnica denominada Hibridização In Situ por Fluorescência (FISH). **Objetivo**: O objetivo deste relato de caso é o primeiro a descrever o planejamento e execução do tratamento odontológico para uma paciente do sexo feminino de 5 anos de idade com SMS sob anestesia geral. **Relato do caso**: O paciente deu entrada no ambulatório da Universidade Federal Fluminense, com possível dor dentária, na anamnese observou-se a necessidade de tratamento invasivo em diversos elementos dentais e devido ao padrão de comportamento do paciente optou-se pelo tratamento sob anestesia geral. **Resultados**: Os procedimentos foram realizados (restaurações e extrações) no hospital na mesma etapa. O acompanhamento da criança após a intervenção foi a cada seis meses. **Conclusão**: A SMS é uma síndrome rara que requer amplo conhecimento do dentista e uma anamnese detalhada para a escolha da melhor opção para a solução do caso.

Keywords: Autism Spectrum Disorder. Dental Caries. Genetic. Smith-Magenis Syndrome.

ABSTRACT

Introduction: Smith-Magenis Syndrome (SMS) is a genetic disease characterized by a neuro-behavioral deficiency caused by mutations or deletions at the 17p11.2 locus comprising the retinoic acid-induced 1 (RAI1) gene. The diagnosis is made through clinical analysis looking for characteristics and to prove this suspicion, a technique called Fluorescence In Situ Hybridization (FISH) is required. **Objective**: The aim of this case report is to be the first to describe the planning and execution of dental treatment for a 5yearold female patient with SMS under general anesthesia. **Case report**: The patient was admitted to the clinic of the Universidade Federal Fluminense, with possible dental pain, in the anamnesis the need for invasive treatment was observed in many dental elements and due to the patient's behavioral pattern, treatment under general anesthesia was chosen. **Results**: Procedures were performed (restorations and extractions) in the hospital in the same step. The child follow-up after the intervention every six month. **Conclusion**: SMS is a rare syndrome that requires extensive knowledge of the dentist and a detailed anamnesis to choose the best option to solve the case.

Submitted: January 7, 2020
Modification: March 30, 2020
Accepted: May 14, 2020

***Correspondence to:**
Dr Viviane Andrade Cancio de Paula
Address: Universidade Federal Fluminense - Faculdade de Odontologia, Rua Mário Santos Braga, no 30 - Campus Valonguinho, Centro, Niterói, RJ, Brazil, Zip Code: 24040-140
Telephone number: +55 (21) 2629-9829

INTRODUCTION

The Smith-Magenis Syndrome (SMS) was first portrayed in the early 1980s.[1,2] It is considered a sporadic syndrome, showing a prevalence of approximately 1: 25,000 live births.[1,2] However, it is believed that this number is underestimated, many cases are not related due to lack of clinical knowledge for diagnosis.[3-7] The features of the syndrome begin to emerge from the 18th to the 36th month of life. Between the 2nd and 3rd year, behaviors typical of Autistic Spectrum Disorder (ASD) begin to emerge. Individuals with SMS usually have restricted interests, tendency to isolation and repetitive activities, characteristics that are similar to those of ASD. Although SMS is a differential diagnosis, the measures that are relevant for a child with ASD also benefit children with SMS.[5,8]

SMS is a neurological development disorder characterized by a well-defined pattern of abnormalities, including a distinct craniofacial dysmorphic model, abnormalities in the circadian rhythm of sleep-surveillance and cognitive impairment with behaviors and psychiatric disorders.[9] Craniofacial manifestations include brachycephaly; wide square face; synophrys; exaggerated eyelid lesions; low nasal bridge with a wide nasal base; everted upper lip and mandibular prognathism.[5] Some behavioral manifestations, such as self-injurious and angry outbursts, are common. In addition, most syndromes have mental retardation, ranging from mild to moderate.[9] Individuals with SMS demonstrate severe communication delays, which interfere with social interaction and learning.[10-13]

Craniofacial dysmorphisms can be observed, as well as an enlarged and prominent forehead, hypoplasia of the midline of the face, a prominent upper lip with the appearance of an arch and prognathism. In the oral cavity, some oral deficiencies are reported, such as lingual weakness, weak bilabial seal and abnormal palate. Although cleft lip and palate occur, they are less frequent in these individuals.[5,10]

Dental anomalies are usually found and can help in the diagnosis of SMS. Agenesis of one or more teeth, mainly of the lower second premolars, taurodontism and lacerations are the most frequently related. In intraoral examination, it is also possible to observe macroglossia and some oral habits.[10] Patients diagnosed with SMS with advancing age, commonly present tooth decay with the need for restoration procedures and gingivitis. This can be explained by the behavioral profile and the particularities of the SMS, which makes preventive care challenging.[10, 14,15]

Depending on the physical, emotional and behavioral characteristics of the patients, outpatient dental care becomes unviable. In this situation, alternative methods are necessary, such as conscious sedation and general anesthesia, which is the option chosen in the present case.[16] This case report is the first to describe the planning and execution of dental treatment in a female patient which is a 5yearold child with SMS under general anesthesia.

CASE REPORT

Female patient, M.L.O.G., 5 years old, leukoderma, was taken to the patient with deficiency clinic of the Faculty of Dentistry of Universidade Federal Fluminense by the mother for the first dental treatment, with the main complaint that the daughter was possibly in pain and with large carious lesions, since she is not a verbal patient.

In the anamnesis, the mother reported that the daughter was diagnosed with Smith-Magenis Syndrome, Autism Spectrum Disorder and mental retardation. In Figure 1 the syndrome physical characteristics is observed frontal bossing, nasal and malar bone depression, and increased size of the bony chin. It was also reported that the patient is accompanied by a neurologist, psychologist, physiotherapist and speech therapist and regularly used medications such as Melatonin, Risperidone and Topiramate. During the interview, the mother commented that the daughter's diet included a bottle with sugary milk, twice a day. The mother also reported the difficulty of performing her daughter's oral hygiene.

At the clinical examination, it was observed that the child had a difficult behavior and was quite agitated for a thorough oral examination. However, it was possible to observe that the following dental elements had extensive caries lesions: 55, 54, 52, 51, 61, 62, 63, 64, 65, 75, 74, 84 and 85, and this can be observed in the panoramic radiography (Figure 2). For the panoramic radiography, the patient was medicated and cooperated. In view of the mother's complaint and the impossibility of treatment in the dental chair, the patient was scheduled to receive complete oral rehabilitation under general anesthesia. All preoperative exams were requested and thoroughly examined by the dental medical team, with special attention to the heart and renal disorders.

Extra and intra-oral hygiene was performed with 0.12% chlorhexidine and an pharyngeal pack was introduced. It was placed a lip retractor to better visualization. It was performed nasotracheal intubation and while the patient was sedated (Figure 3), dental prophylaxis was also performed with a low-speed handpiece and dental polishing brush. Subsequently, a restoration was carried out with composite resin A2 of the Z300 brand (A1 and B2 color, Resina Filtek Universal - 3M, São Paulo, Brazil) in the following elements: 55, 64, 65, 74, 84 and 85, with finishing and final polishing in the restorations. Due to severe caries and the

presence of an odontogenic abscess, seven teeth were extracted after administration of 3 tubes of 2% lidocaine with epinephrine 1: 100,000: 51, 52, 61, 62, 63, 54 and 75, with local suture Vicryl colorless (Ethicon, Johnson & Johnson, São Paulo, Brazil) thread (Figure 4). In the end, the pharyngeal pack was removed, the patient was extubated and sent to the room. The patient was discharged from the hospital on the same day. All guidance regarding the reduction of the cariogenic diet was given and oral hygiene instructions were given. The patient is followed up every six months. The patient has already attended two return visits. With integral restorations. Without presenting new caries lesions.



***Figure 1**: Facial and body (arms) characterization corresponding to SMS.*

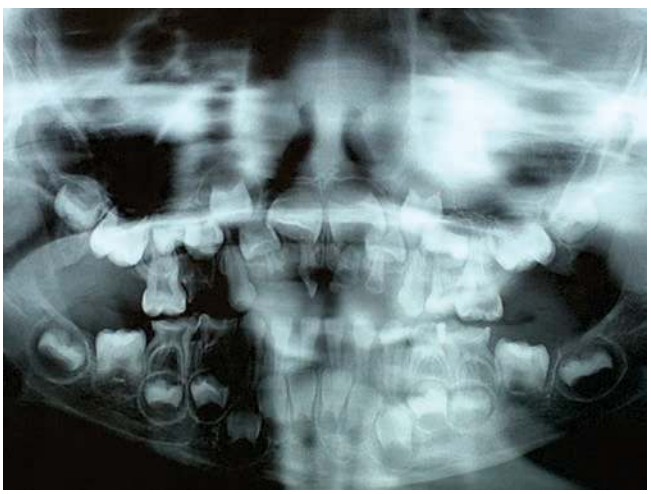

***Figure 2**: Dental anomalies observed in SMS. Taurodont pulps are present in upper and lower first permanent molars.*



***Figure 3**: Intubated patient. Intraoral preoperative photograph of the maxillary and mandibular arch showing tooth destruction, mainly upper lip.*

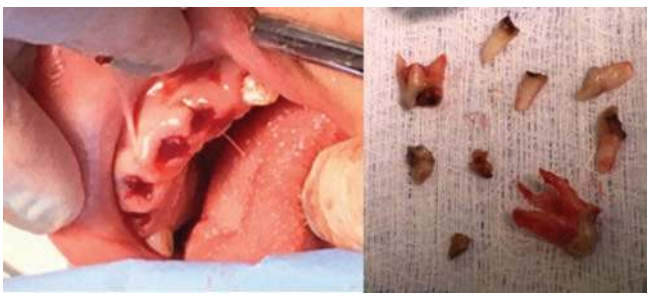

***Figure 4**: Intraoral postoperative photograph of the maxillary arch and teeth extracted. Observe the dental destruction of the elements.*

DISCUSSION

Smith-Magenis syndrome was first recorded by Smith et al. in 1982, and in 1986[1], it was further developed by Smith et al.[1] and Stratton et al.[2] Thus, it was characterized as a genetic disease that has the cognitive deficit caused by the deletion of the chromosomal region 17p11.2 or mutations of the RAI1 gene point.[1,2,7,17] However, there is little literature on the disease and reports of medical cases.[18] Reports of dental treatment and management of patients with SMS were not found in the literature.

This is the first work that reports the management and dental treatment of a child with SMS under general anesthesia. Report on the oral condition and its characteristics have little information and only one article was found.[10] The

consistent nding of anterior mandibular tooth position, frontal bossing, nasal and malar bone depression, and increased size of the bony chin was observed in this case (Figure 1 and 2), as well as Tomona and collaborators.[10] Another difficulty encountered was that the patient in this report was very young, with great difficulty in cooperating for outpatient care and in great need of dental treatment.

In the anamnesis, the mother reported that the patient was diagnosed as having the SMS and that she is monitored by a multidisciplinary team, using various medications. The diagnosis presented and the interaction with other professionals (doctors, nurses, speech therapists) brought an understanding of the clinical condition of this patient, making it possible to understand that due to the number of procedures to be performed, treatment in multiple sessions would not be indicated.[10,19]

Given the impossibility of effective behavior control within the dental clinic and the need for several applications and a large amount of dental procedures to be performed, with a lot of restorations and tooth extractions, the most accessible alternative was treatment using general anesthesia, thus performing all procedures in a safe and single session.

Dental treatment under general anesthesia should be done only when other methods of behavioral management are unsatisfactory, correctly adopting the previous measures and knowing the limitations of the technique.[20-22] Usually, it is indicated for patient with deficiency who have physical and mental restrictions, that is, unable to collaborate in cases of major interventions, making service in the office difficult.[23-26] For this, all necessary procedures were performed, such as: preoperative exams, surgical risk, scheduling of the surgical center at the hospital and request of an anesthesiologist for the application of general anesthesia.[22]

Currently known behavioral managements allow children and patients with deficiency to be facilitated, and a large portion of these patients can be seen on an outpatient basis using the different forms of non-pharmacological and pharmacological behavioral approach.[25-27] However, in extreme cases, the use of general anesthesia in the operating room becomes the most viable option for carrying out therapeutic strategies that favor the development of these individuals.[22] Education about oral hygiene should be intensive and should be given to the child and caregivers, as the child has involuntary movements and lacks the motor coordination necessary to brush properly independently. Special emphasis should be placed on the brushing technique; parental cooperation is extremely valuable in motivating and rewarding the child to brush properly. Constant and frequent compliments, when appropriate, is helpful. If parents are not motivated to become conscientious and compliant, and they do not maintain good home care, it is very difficult to keep the child free of caries, despite frequent dental consultations.

Future studies with groups of patients with SMS should be encouraged so that it is possible to know more deeply the oral characteristics and the management of these patients in view of the need for dental treatment. In addition, the multidisciplinary approach is important in order to allow patients to lead a better quality of life.

CONCLUSION

Smith-Magenis Syndrome stands out for being a rare syndrome and patients usually have difficult control during dental treatment. Thus, the need for a detailed treatment plan for choosing the most appropriate procedure is emphasized, aiming at a faster and more efficient intervention, preferably done in a single session.

REFERENCES

1. Smith ACM, McGavran L, Waldstein G. Deletion of the 17 short arm in two patients with facial clefts. Am. J. Hum. Genet. 1982 34:410.

2. Stratton RF, Dobyns WB, Greenberg F, De Sana JB, Moore C, Fidone G, et al. Report of six additional patients with a new chromosome deletion syndrome. Am J Med Genet. 1986 24:421.32. doi: 10.1002/ajmg.1320240305.

3. Shelley BP, Robertson MM, Turk J. An individual with Gilles de la Tourette syndrome and Smith–Magenis microdeletion syndrome: is chromosome 17p11. 2 a candidate region for Tourette syndrome putative susceptibility genes? J Intellect Disabil Res. 2007 51(8), 620.624. doi: 10.1111/j.1365.2788.2006.00943.x

4. Lamônica D, Silva G, Furlan R, Abramides D, Vieira G, Moretti.Ferreira D, Giacheti C. Características clínicas, comportamentais, cognitivas e comunicativa na síndrome Smith.Magenis. Rev. CEFAC. 2012 14(6), 1226.1233.

5. Smith AC, Magenis RE, Elsea SH. Overview of Smith.Magenis syndrome. J Assoc Genet Technol. 2005 31(4), 163.167.

6. Juyal RC, Figuera LE, Hauge X, Elsea SH, Lupski JR., Greenberg F, et al. Molecular analyses of 17p11. 2 deletions in 62 Smith.Magenis syndrome patients. Am J Hum Genet. 1996 58(5), 998.

7. Edelman EA, Girirajan S, Finucane B, Patel PI, Lupski J R, Smith ACM, Elsea SH. Gender, genotype, and phenotype differences in Smith.Magenis syndrome: a meta.analysis of 105 cases. Clin Genet 2007 71: 540–550. doi: 10.1111/j.1399.0004.2007.00815.x.

8. Laje G, Morse R, Richter W, Ball J, Pao M, Smith, ACM. Autism spectrum features in Smith.Magenis syndrome. Am. J. Med. Genet. C. 2010 154C(4), 456–462. doi : 10.1002/ajmg.c.30275.

9. Elsea SH, Girirajan S. Smith–Magenis syndrome. Eur J Hum

Genet. 2008; 16(4), 412.421. doi : 10.1038/sj.ejhg.5202009.
10 .Tomona N, Smith A, Guadagnini JP, Hart TC. Craniofacial and dental phenotype of Smith–Magenis syndrome. Am J Med Genet A. 2006 140A(23), 2556–2561. doi: 10.1002/ajmg.a.31371.
11. Girirajan S, Vlangos CN, Szomju BB, Edelman E, Trevors CD, Dupuis L, et al. Genotype–phenotype correlation in Smith.Magenis syndrome: evidence that multiple genes in 17p11. 2 contribute to the clinical spectrum. Genet Med. 2006 8(7), 417.427.
12. Juyal RC, Greenberg F, Mengden GA, Lupski JR, Trask BJ, van den Engh, G, et al. SmithMagenis syndrome deletion: A case with equivocal cytogenetic findings resolved by fluorescence in situ hybridization. Am J Med Genet. 1995 58(3), 286.291. doi: 10.1002/ajmg.1320580317.
13. Potocki L, Glaze D, Tan D X, Park SS, Kashork CD, Shaffer LG, et al. Circadian rhythm abnormalities of melatonin in Smith.Magenis syndrome. J. Med. Genet. 2000 37(6), 428.433. doi: 10.1136/jmg.37.6.428.
14. Lakshmi K, Kumar PM, Das H. Design considerations for a dental health care for patients with special needs. J. Access. Des. All: JACCES. 2018 8(1), 80.101. doi: 10.17411/jacces.v8i1.168
15. Delli K, Reichart PA, Bornstein MM, Livas C. Management of children with autism spectrum disorder in the dental setting: concerns, behavioural approaches and recommendations. Med Oral Patol Oral Cir Bucal. 2013 18(6), e862. doi: 10.4317/medoral.19084.
16. Silva CC, Lavado C, Areias C, Mourão J, Andrade DD. Conscious sedation vs general anesthesia in pediatric dentistry–a review. MedicalExpress. 2015 2(1).
17. Smith AC, McGavran L, Robinson J, Waldstein G, Macfarlane J, Zonona J, et al. Interstitial deletion of (17) (pll.2pll.2) in nine patients. Am J Med Genet 1986 24:393.414. doi: 10.1002/ajmg.1320240303.
18. Khan SS, Pradhan T. Case of Smith.Magenis Syndrome. J. Clin. Psychopharmacol. 2019 39(5), 525.527. doi: 10.1097/JCP.0000000000001099.
19. Wang YC, Lin IH, Huang CH, Fan SZ. Dental anesthesia for patients with special needs. Acta Anaesthesiol Taiwan. 2012 50(3), 122–125. doi: 10.1016/j.aat.2012.08.009
20. Hennequin M, Faulks D, Roux D. Accuracy of estimation of dental treatment need in special care patients. J Dent. 2000 28(2), 131.136. doi: 10.1016/s0300.5712(99)00052.4.
21. Bouras N, Dykens EM, Smith ACM. Distinctiveness and correlates of maladaptive behaviour in children and adolescents with Smith–Magenis syndrome. J Intellect Disabil Res. 1998 42(6), 481.489. doi: 10.1046/j.1365.2788.1998.4260481.x
22. Lim M, Borromeo G. The use of general anesthesia to facilitate dental treatment in adult patients with special needs. J Dent Anesth Pain Med. 201717(2), 91.103. doi: 10.17245/jdapm.2017.17.2.91.
23. Bengtson C, Bengtson N, Bengtson A, Pinheiro S, Mendes F. The use of general anesthesia in pedodontics. Rev Inst Ciênc Saúde. 2006 24(4), 319.25.
24. Chen YP, Hsieh CY, Hsu WT, Wu FY, Shih WY. A 10.year trend of dental treatments under general anesthesia of children in Taipei Veterans General Hospital. J CHIN MED ASSOC. 2017 80(4), 262.268.doi: 10.1016/j.jcma.2016.11.001.
25. Stokes TF, Kennedy SH. Reducing child uncooperative behavior during dental treatment through modeling and reinforcement. J Appl Behav Anal . 1980 13(1), 41–49. doi; 10.1901/jaba.1980.13.41.
26. Dantas LP, de Oliveira.Ribeiro A, de Almeida.Souza, LM, Groppo, FC. Effects of passiflora incarnata and midazolam for control of anxiety in patients undergoing dental extraction. Med Oral Patol Oral Cir Bucal. 2017 22(1), e95. doi: 10.4317/medoral.21140.

IMPACTION OF MANDIBULAR CANINE ASSOCIATED WITH A DENTIGEROUS CYST: A 2.5-YEAR FOLLOW-UP REPORT

Thiago Isidro **Vieira**[1,2], Thais Rodrigues Campos **Soares**[1], Priscila Assunção de **Almeida**[1], Fernanda Blaudt Carvalho **Marques**[1], Monica Tirre de Souza **Araujo**[1], Gloria Fernanda Barbosa de Araújo **Castro**[1*]

[1]Department of Paediatric Dentistry and Orthodontics, School of Dentistry, Universidade Federal do Rio de Janeiro, Rio de Janeiro, RJ, Brazil.
[2]Postgraduate program, School of Dentistry, Universidade Federal da Paraíba, João Pessoa, Paraíba, PB, Brazil.

Palavras-chave: Cisto Dentígero. Dente Impactado. Mandíbula.

RESUMO

Introdução: O cisto dentígero é uma lesão odontogênica ao redor da coroa de um dente não irrompido ou impactado na mandíbula. **Objetivo**: O objetivo deste relato de caso é descrever o plano do tratamento e o acompanhamento de um cisto dentígero associado à impactação do canino permanente inferior direito em uma criança do gênero feminino de 11 anos de idade. **Relato do caso**: A avaliação radiográfica revelou lesão unilocular radiolúcida de forma arredondada, localizada na sínfise mandibular. A enucleação foi realizada e o dente afetado foi removido sob anestesia geral. A paciente encontra-se em acompanhamento devido o tratamento ortodôntico. A área afetada curou sem complicações. **Conclusão**: Dois anos e meio após a enucleação, o cisto desapareceu totalmente e não houve recidivas. Remodelação óssea e neoformação foram observadas.

Keywords: Dentigerous Cyst. Tooth Impacted. Mandible.

ABSTRACT

Introduction: Dentigerous cyst is an odontogenic cyst lesion surrounding the crown of an unerupted or impacted tooth in the jaw. **Objective**: The aim of this case report is to describe the treatment planning and follow-up of a dentigerous cyst associated with the impaction of the permanent mandibular right canine tooth in an 11-year-old female. **Case report**: Radiographic assessment revealed a radiolucent unilocular round-shaped lesion localized in the mandibular symphysis. Enucleation was performed and the affected tooth was removed under general anesthesia. The patient is under follow-up due to orthodontic treatment. The affected area healed without complications. **Conclusion**: Two and a half years after the enucleation, the cyst had totally disappeared, and no recurrences were observed. Bone remodeling and neoformation were noticed.

INTRODUCTION

Dentigerous cyst is an odontogenic cyst lesion surrounding the crown of an unerupted or impacted tooth in the jaw. It is commonly asymptomatic and may appear as a painless swelling of the affected region and because of its specific feature it may be detected in routine radiograph examinations. Usually, it is a unilocular and radiolucent area associated with a well-defined sclerotic border.[1]

The prevalence of dentigerous cyst shows that the male to female ratio ranges from 1.8:1 to 3:2.[1,2] In large sample studies, permanent mandibular canine is not the most commonly affected. The most frequent is third molar, followed by supernumerary teeth, second premolar and first molar / first premolar.[3] Other study indicates third molar as the most prevalent followed by supernumerary teeth.[4] An unerupted permanent tooth that has been affected may erupt or not in the oral cavity. Orthodontic correction can be employed for this purpose. Thus, the

Submitted: July 10, 2020
Modification: Sept 08, 2020
Accepted: Oct 14, 2020

***Correspondence too**:
Glória Fernanda Barbosa de Araújo Castro
Address: Caixa Postal: 68066 – Cidade Universitária - CCS
Zip Code: 21941-971 - Rio de Janeiro – RJ – Brazil
Telephone number/FAX: +55 (21) 3938-2101
E-mail: gfbacastro@yahoo.com.br

aim of this report is to describe a case of a dentigerous cyst associated with the impaction of the permanent mandibular right canine tooth in an 11-year-old female child. This report was carried out according to the CARE Statement.[5]

CASE REPORT

An 11-year-old female child and her guardian came to the Department of Pediatric Dentistry and Orthodontics of Universidade Federal do Rio de Janeiro seeking for dental treatment. A term of free and informed consent signed by the participant and/or her legal guardian was obtained. According to the anamnesis, she was born by Caesarean section at 38 weeks with normal weight; she is not allergic to any drug and has never been hospitalized. Past medical history evidenced no illnesses. The subject was not taking any medication at her initial appointment.

Clinical examination showed primary mandibular right canine tooth had a temporary filling in the cervical third. Oral hygiene was satisfactory. No changes in gingival color or purulent discharge were noticed in the region related to primary mandibular right canine tooth. The permanent mandibular right canine had not erupted while its homologous tooth had already been satisfactorily erupted in oral cavity. The occlusal (Figure 1A) and periapical (Figure 1B) radiographs and the multi-slice images from the computed tomography (Figure 1C and Figure 1D) scan examination showed the presence of impacted tooth (permanent mandibular canine) with an oblique arrangement in the right mandibular symphysis, inferior to the roots of the incisors and the lower right primary canine. A radiolucent round-shaped lesion was observed involving the crown of the impacted tooth measuring about 16 x 11 mm. The presumptive diagnosis was a dentigerous cyst at the time.

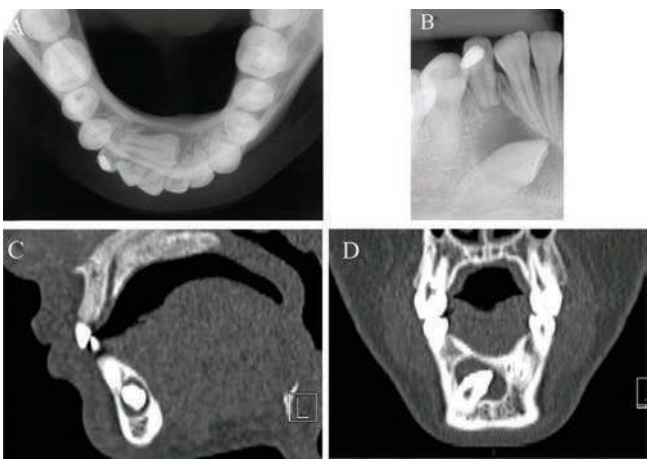

***Figure 1**: A) Occlusal radiograph. B) Periapical radiograph. C) Computed tomography sagittal scan showing a large hypodense lesion with intact lingual and buccal cortices. D) Computed tomography coronal scan.*

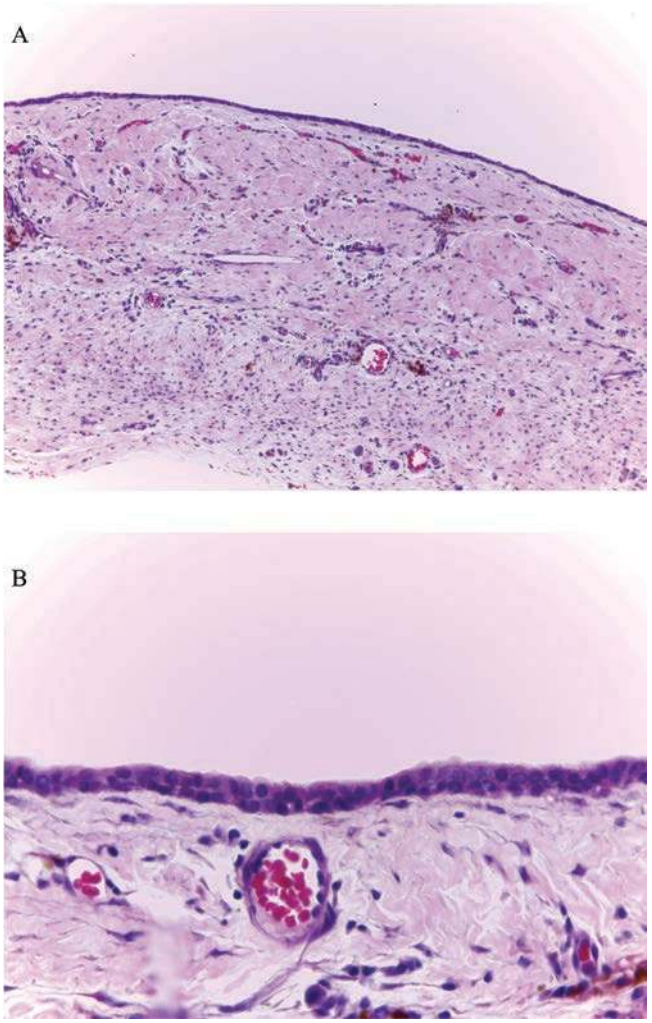

***Figure 2**: A) H&E stained slide scan showing histological feature of the mandibular dentigerous cyst presenting non-keratinized squamous epithelium with cholesterol clefts (x10 magnification). B) Blood vessels (x40 magnification).*

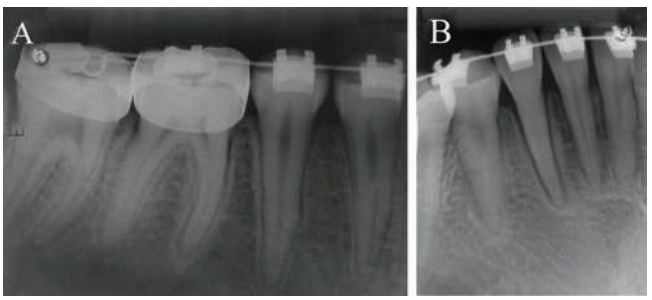

***Figure 3**: A) and B) Two and a half years follow-up. A post-treatment periapical radiograph showing complete bone formation.*

The treatment plan consisted of extraction of primary mandibular right canine and permanent mandibular right canine, surgical removal of the lesion under general anesthesia, and oral hygiene instructions. This approach was conducted by the age of 11.33 years old. The patient was referred to orthodontics service. The histopathological results

confirmed the initial diagnosis of a dentigerous cyst. Microscopic findings showed cystic lesion with non-keratinised stratified squamous epithelium and a connective tissue with cholesterol clefts (Figure 2A) and blood vessels (Figure 2B).

Follow-up radiographs were taken by the age of 13.83 years old and the affected area healed without complications, complete bone formation was observed and there were no recurrences during this 2.5-year follow-up (Figure 3A and Figure 3B). A suggestive image of pulp calcium metamorphosis related to the permanent mandibular right lateral incisor was observed as well as an increase in its periodontal ligament space.

DISCUSSION

Maxillary canine impaction is a relatively common dental problem observed in dental practice. Regarding lower teeth the occurrence of mandibular canine impaction ranges from 0.92 to 5.1%. The etiology of this condition is not solidified in pertinent literature but cysts and others pathological disorders may interact in this context.[6] According to gender predilection regarding tooth impaction, females are more affected than males with percentage frequencies ranging from 50.76 to 64.28%.[7-9] As reported herein the current study describes the case of a monolateral canine impaction in an 11-year-old female patient.

Regarding the radiographic analysis, additional exposure due to repeated evaluations should be avoided according to the European Academy of Paediatric Dentistry policy document.[10] The imaging characterization was possible because the patient is a cooperative child and was able to collaborate during the x-ray exposure. Cone-beam computed tomography was employed because cross-sectional slices were required for the current treatment planning.[10]

The treatment of young patients with large dentigerous cysts may vary according to morbidity; maintenance or not of affected permanent tooth and age of the patient.[11] Cyst enucleation and marsupialization are surgical options for dentigerous cyst treatment. The treatment employed in our case consisted of cyst enucleation and extraction of the impacted canine. This treatment plan is indicated for a single impaction such as in the current case as well as the cyst size not being so extensive. For an extensive cyst it is contraindicated because it would lead to the loss of some teeth. Cyst decompression is adequate conservative treatment for children because they regenerate bone faster than do adults.[12] This approach was not conducted due to location of the lesion and the impossibility of orthodontic realignment of the canine. Additionally, tooth associated with a dentigerous cyst can be maintained if it may erupt spontaneously or with the aid of orthodontics techniques. Marsupialization surgical treatment may be employed in such cases and a successful outcome is expected.[13]

Regarding the histopathological assessment, the current case describes a cystic lesion with non-keratinised stratified squamous epithelium and a connective tissue with cholesterol clefts and blood vessels. These features are in accordance with pertinent literature. Stratified squamous lining epithelium and cholesterol clefts were frequently observed[3,14,15] as well as blood vessels.[16] The differential diagnoses include glandular odontogenic cyst; odontogenic keratocyst; unicystic ameloblastoma[1] and may be associated with adenomatoid odontogenic tumour.[17]

Previous literature has already assessed a 2-year follow-up period to observe lesion regression in children and adolescents.[(16)] The prevalence of recurrence is 13.43% (9/67) and the prevalence of neoplastic change is 1.49% (1/67).[18] Two and a half years after the enucleation, the cyst had totally disappeared and no recurrences were observed. Bone remodeling and neoformation were noticed. During follow-up the patient presented pulp obliteration of the permanent mandibular right lateral incisor, this calcification is caused by the deposition of diffuse hard tissue in the coronary pulp and may extend to the root canal space. Orthodontic treatment is considered one of the main etiological factors, however the exact mechanism of action is still unknown. Endodontic intervention is not necessary, as the tooth is asymptomatic and has no clinical or radiographic signs of caries or periapical disease.[19-22]

The current case reinforces the importance of the histopathological examination of all excised lesions from the jaws and vigilant follow-up appointments in order to observe any complication or recurrence after the surgical treatment. It should be emphasized that although dentigerous cyst is a common and benign lesion, careful anamneses, accurate diagnosis and good interpretation of clinical and radiographic findings is recommended.

ACKNOWLEDGEMENTS

Marcello Roter Marins for surgical management of the case. This study was financed in part by the Coordenação de Aperfeiçoamento de Pessoal de Nível Superior – Brasil (CAPES) – Finance Code 001 and CNPq (159961/2018-1).

REFERENCES

1.Thompson LD. Dentigerous Cyst. Ear Nose Throat J. 2018; 97(3):57. doi: 10.1177/014556131809700317.

2.Tamiolakis P, Thermos G, Tosios KI, Sklavounou-Andrikopoulou A. Demographic and Clinical Characteristics of 5294 Jaw Cysts: A Retrospective Study of 38 Years. Head Neck Pathol. 2019; 13(4):587-596. doi: 10.1007/s12105-019-01011-7.

3.Lin HP, Wang YP, Chen HM, Cheng SJ, Sun A, Chiang CP. A clinicopathological study of 338 dentigerous cysts. J Oral Pathol Med. 2013; 42:462–467. doi: 10.1111/jop.12042.

4.Mourshed F. A roentgenographic study of dentigerous cysts. III. Analysis of 180 cases. Oral Surg Oral Med Oral Pathol. 1964; 18:466–73. doi: 10.1016/0030-4220(64)90392-5.

5.Gagnier JJ, Kienle G, Altman DG, Moher D, Sox H, Riley D, et. al. The CARE Guidelines: Consensus-based Clinical Case Reporting Guideline Development. Glob Adv Health Med. 2013 Sep;2(5):38-43. doi: 10.7453/gahmj.2013.008.

6.Dalessandri D, Parrini S, Rubiano R, Gallone D, Migliorati M. Impacted and transmigrant mandibular canines incidence, aetiology, and treatment: a systematic review. Eur J Orthod. 2017; 39(2):161-169. doi: 10.1093/ejo/cjw027.

7.Yavuz MS, Aras MH, Büyükkurt MC, Tozoglu S. Impacted mandibular canines. J Contemp Dent Pract. 2007; 8(7):78–85.

8.Kara MI, Ay S, Aktan AM, Sener I, Bereket C, Ezirganli S, et al. Analysis of different type of transmigrant mandibular teeth. Med Oral Patol Oral Cir Bucal. 2011; 16(3):e335-40. doi: 10.4317/medoral.16.e335.

9.Jain S, Shetty KS, Prakash AT, Agrawal M, Jain S. Permanent mandibular canine(s) impaction: expansion of our understanding. Aust Orthod J. 2014; 30(1):39–44.

10.Kühnisch J, Anttonen V, Duggal MS, Loizides Spyridonos M, Rajasekharan S, Sobczak M, et. al. Best clinical practice guidance for prescribing dental radiographs in children and adolescents: an EAPD policy document. Eur Arch Paediatr Dent. 2020 Aug;21(4):375-386. doi: 10.1007/s40368-019-00493-x

11.Santos TS, Sehn FP, Dias RR, Xavier SP. Volume Increase of Dentigerous Cyst After Decompression. J Craniofac Surg. 2014; 25(6):2254-5. doi: 10.1097/SCS.0000000000000979.

12.Motamedi MHK, Talesh KT. Management of extensive dentigerous cysts. Br Dent J. 2005; 198:203–206. doi: 10.1038/sj.bdj.4812082.

13.Qian WT, Ma ZG, Xie QY, Cai XY, Zhang Y, Yang C. Marsupialization facilitates eruption of dentigerous cyst-associated mandibular premolars in preadolescent patients. J Oral Maxillofac Surg. 2013 Nov;71(11):1825-32. doi: 10.1016/j.joms.2013.06.223

14.Yeo JF, Rosnah BZ, Ti LS, Zhao YY, Ngeow WC. Clinicopathological study of dentigerous cysts in Singapore and Malaysia. Malays J Pathol. 2007; 29:41–7.

15.Chiang CP, Kwan HW. A clinicopathologic study of 70 cases of dentigerous cysts. J Formos Med Assoc. 1982; 81:686–91.

16.Marques NP, Marques NCT, Sakai VT, Hanemann JAC. Inflammatory Follicular Cysts Associated to Necrotic Primary Teeth. Eur Arch Paediatr Dent. 2017; 18(4):279-285. doi: 10.1007/s40368-017-0297-5.

17.Nonaka CF, de Souza LB, Quinderé LB. Adenomatoid odontogenic tumour associated with dentigerous cyst—unusual case report. Braz J Otorhinolaryngol. 2007; 73(1):129-31. doi: 10.1016/s1808-8694(15)31135-6.

18.Fickling BW. Cysts of the jaw: a long-term survey of types and treatment. Proc R Soc Med. 1965 Nov;58(11 Part 1):847-54.

19.Gomes CB, Treister NS, Miller B, Armand P, Friedland B. Pulp obliteration in a patient with sclerodermatous chronic graft-versus-host disease. J Endod. 2016; 42(4):678-680. doi: 10.1016/j.joen.2016.01.009.

20.McCabe PS, Dummer PM. Pulp canal obliteration: an endodontic diagnosis and treatment challenge. Int Endod J. 2012; 45:177–97. doi: 10.1111/j.1365-2591.2011.01963.x.

21.Goga R, Chandler NP, Oginni AO. Pulp stones: a review. Int Endod J. 2008; 41:457–68. doi: 10.1111/j.1365-2591.2008.01374.x.

22. Nayak M, Kumar J, Prasad LK. A radiographic correlation between systemic disorders and pulp stones. Indian J Dent Res. 2010; 21:369–73. doi: 10.4103/0970-9290.70806.

MIRROR IMAGE: A RARE CASE OF PROLONGED TOOTH RETENTION IN TWINS

Viviane Andrade Cancio de **Paula**[1], Maristela Barbosa **Portela**[1*], Roberta **Barcelos**[2], Laura Guimarães **Primo**[3]

[1]Department of Clinics and Pediatric Dentistry, School of Dentistry, Universidade Federal Fluminense (UFF), Niterói, RJ, Brazil.
[2]Health Institute of Nova Friburgo (ISNF), Universidade Federal Fluminense (UFF), Nova Friburgo, RJ, Brazil.
[3]Department of Pediatric Dentistry and Orthodontics, School of Dentistry, Universidade Federal do Rio de Janeiro (UFRJ), Rio de Janeiro, RJ, Brazil.

Palavras-chaves: Caso Clínico. Dente. Decíduo. Gêmeos.

RESUMO

Introdução: Estudos feitos em gêmeos são importantes porque fatores ambientais e genéticos parecem estar relacionados às alterações fenotípicas. **Objetivo**: Este artigo apresenta um caso raro de gêmeos monozigóticos apresentando imagem em espelho de retenção prolongada de incisivos centrais decíduos superiores homólogos. **Relato do caso**: Os irmãos gêmeos, com 9 anos de idade, não apresentavam história de trauma orofacial ou doença comum da infância. Após exames clínicos e radiográficos foram identificados a retenção do dente 51 no gêmeo 1 e do dente 61 no gêmeo 2. Em ambos os pacientes, os dentes 11 e o 21 estavam em erupção. O tratamento proposto foi a exodontia dos dentes decíduos com anestesia local e acompanhamento. **Conclusão**: Gêmeos podem apresentar semelhança no padrão de anomalias dentárias devido à influência de fatores genéticos. Adicionalmente, em gêmeos monozigóticos, a localização das anomalias diagnosticadas pode se apresentar invertidas ou imagem em espelho. Esse fato deve estimular o profissional a examinar o par de gêmeos para diagnosticar qualquer anomalia dentária que possa estar presente. O diagnóstico precoce e tratamento adequados devem ser realizados para evitar danos funcionais e estéticos em pacientes com retenções dentárias.

Keywords: Case Reports. Dental Care for Children. Tooth. Deciduous. Twins.

ABSTRACT

Introduction: Studies of twins are important because environmental and genetic factors seem to be related to the phenotypic alterations. **Objective**: This paper presents a unique case of monozygotic twins with mirror image of a retained primary central incisor. **Case report**: Twin male brothers, 9-years-old, presented prolonged retention of the primary central upper incisor. The over-retained teeth in one twin were a mirror image of those in the other twin. The first twin presented a prolonged retention of the tooth 51 whereas the other twin presented a prolonged retention of tooth 61. After radiographic exams the over-retained teeth were extracted. **Conclusion**: Twins may show similarity in pattern of dental anomalies supporting the influence of genetic factors. In identical twins the location of diagnosed anomalies can be mirror imaged. This fact should lead the professional to examine the pair of twins in order to diagnose any dental anomaly that may be present.

INTRODUCTION

Mirror-image is a phenomenon in which a given characteristic is expressed in reverse sides when monozygotic siblings are compared to each other.[1] Even though there is a relatively strong genetic basis to missing or extra teeth, the number or position of affected teeth can be influenced by epigenetic factors. The mechanism of mirror imaging is unwell understood.[2] Different forms of division may occur in the monozygotic embryo. The first one occurs in an early developmental phase resulting from two zygotic cells. The second one, is the result from zygotic splitting during early blastocystic stage. One explanation for mirror-image is the division in a later

Submitted: July 21, 2020
Modification: Sep 10, 2020
Accepted: Oct 14, 2020

***Correspondence to**:
Maristela Barbosa Portela
Rua Mario Santos Braga 28, Centro, Niterói, RJ, Brazil. - Zip Code: 24020-140
Telephone number: +55 21 2629- 9832 - Fax: +55 21 2622-5739
E-mail: mbportela@hotmail.com

embryonary stage.[3] Different forms of mirror-image anomalies in monozygotic twins were found in medical reports such as radial longitudinal hypoplasia and bifid spine,[1] myopia,[3] optic nerve hypoplasia[1], bone cysts,[5,6] arachnoid cysts[2] and carcinomas.[4] With respect to the mirror-image oral manifestations few different anomalies have been reported in the available literature (Table 1), but no case was found showing mirror image of over-retention of primary teeth. This paper presents a unique case of monozygotic twins aged 9 years, with mirror image retained primary central incisors.

***Table 1**: Mirror imaging dental findings in non-syndromic twins.*

Author (year)	Dental findings
Nik-Hussein and Salcedo, 1987[8]	Double teeth with hypodontia
Carton and Rees, 1987[9]	Conical supranumerary tooth
Beere, 1990[10]	Supranumerary tooth
Lauweryns et al, 1992[11]	Mesio lingual rotation tooth
Sperber et al, 1994[12]	Fused tooth
West, 1995[13]	Disto bucal rotation of the tooth / Deciduous tooth shed
Casseta et al, 2015[14]	Impacted teeth / Supernumerary teeth

CASE REPORT

The twin male patients, 9 years old, arrived for routine appointment at the Pediatric Dentistry Clinic of a Public School of Dentistry in Rio de Janeiro, Brazil, with chief complaint of non-exfoliation of primary teeth in both children. Their prenatal and natal histories were uneventful. No history of orofacial trauma or unusual childhood diseases was determined. The twins had identical features and their height and weight were within normal limits.

However, clinical examination showed that one of the twin (twin 1) presented a prolonged retention of the tooth 51, teeth 11 and 21 were erupting being that tooth 11 in a different position than its homolog (Figure 1). Regarding the twin 2, it was observed a prolonged retention of tooth 61 and presence of teeth 11 and 21 as well (Figure 2). In twin 1, both tooth 11 and 21 erupted in the correct position in the arch, unlike twin 2, where only tooth 21 erupted in the normal position. Dental caries and other oral pathologies were not observed in both brothers.

Periapical and panoramic radiographs confirmed the prolonged retention of deciduous teeth in both twins. The retention of deciduous contralateral teeth in these twins was diagnosed as a mirroring image phenomenon. No other alterations were observed in the radiographic exams.

The treatment plan included extraction of the retained teeth under local anesthesia (Figures 3 and 4). The procedure was performed following the mother's consent. Both patients were undergoing dental exchange and the incisors had an open apex, which did not recommend orthodontic movement at that time. Therefore, it was decided to refer patients for orthodontic evaluation.

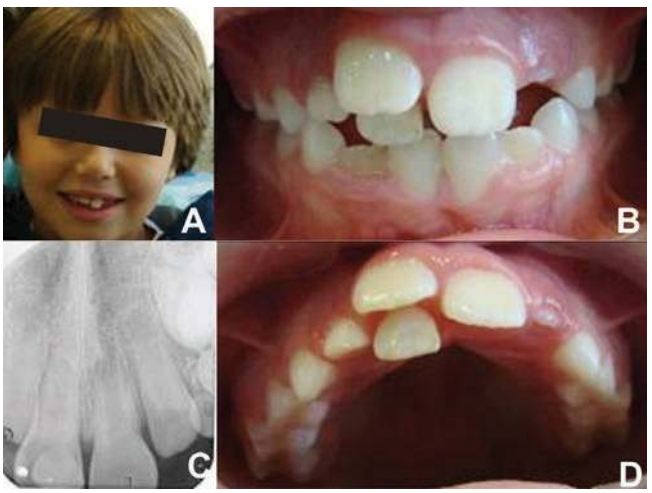

***Figure 1**: A) Frontal view of the patient's face - twin 01 B) Photography of frontal view of tooth 51. C) Periapical radiography of teeth 11, 21 and 51. D) Photography of oclusal view of teeth 51.*

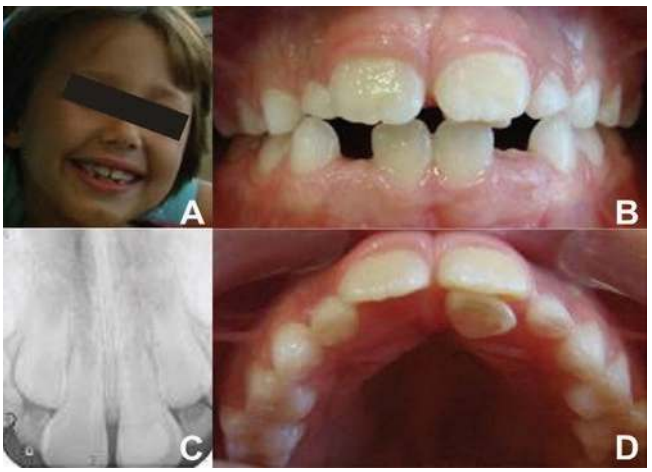

***Figure 2**: A) Frontal view of the patient's face - twin 02. B) Frontal view of tooth 61. C) Periapical radiography of teeth 11, 21 and 61. D) Oclusal view of teeth 61.*

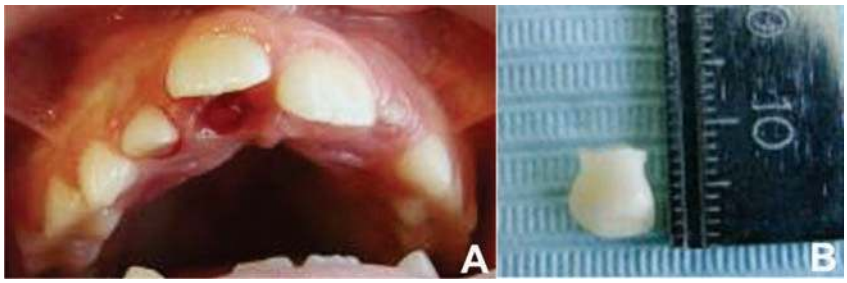

***Figure 3**: A) Photograpy of oclusal view of twin 1 after extraction of the teeth 51. B) Photograpy of the tooth 51 removed exhibiting physiological root resorption.*

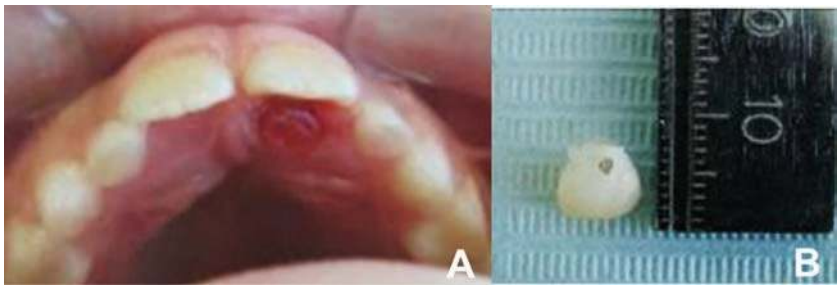

***Figure 4**: A) Photograpy of cclusal view of twin 2 after extraction of the tooth 61. B) Photograpy of the tooth 61 removed exhibiting physiological root resorption.*

DISCUSSION

The interesting aspect of the present case was the mirror image of the anomaly. In this pair of twins, the dental anomalies were identical but on contralateral sides. Mirror imaging has been demonstrated in the dental findings pertaining to normal twins, as well as those with facial dysmorphlogies such as cleft and/or palate.[11] Although, the supposition that monozygotic twins will always exhibit pathologies at homologue sides may not be entirely true, and for this reason the practitioner should pay attention to genetic and environmental factors[8,11,15,16] In addition, two or more concomitant developmental alterations are likely to be identified in monozygotic twins. Therefore, we ordered panoramic radiographs of each twin despite the normal clinical and developmental conditions, in order to diagnose any other anomaly that would be present.

The literature shows the prolonged retention of primary teeth in non-twin associated with trauma or endodontic treatment.[8,17,18] The percentage of prolonged retention of primary teeth with displacement of the permanent series is 4.2%.[19] Other dental situations associated with the mirror-image twins found were double teeth with hypodontia,[8] conical supernumerary tooth,[9] supernumerary tooth,10 rotating mesio lingual tooth[11] molten tooth. However, prolonged retention of primary teeth in mirror-twins has not been reported, making this report relevant.

In the present case, it was not possible to identify the exact cause of prolonged retention of deciduous teeth as no history of dental trauma[8,17] was reported during anamnesis. As few studies regarding mirror imaging in the oral cavity of monozygotic twins, this case can be considered an unusual condition in dentistry. There is no evidence in the literature that one side of one twin was more concordant with the opposite side of the co-twin.[12] It is possible that monozygotic twin pairs have exactly the same genotype, and that any phenotypic differences[8] between them must be caused by prenatal or postnatal environmental influences.[12] On the other hand, the present case suggests that when one twin presents an alteration of any kind, the other may also present the same alteration in a mirrored way, generating the need for more accurate exams. Panoramic radiographs were requested but no other alterations were observed.

Lingual development and eruption of the mandibular permanent incisors and the concomitant retention of mandibular primary teeth before 8 years old is considered physiological.[11] However, cases of prolonged retention of upper central incisors are seldom reported, since permanent teeth follow their precedent deciduous teeth through the roots.[8,9,12] These cases are considered relevant because the eruption of permanent teeth can be affected by such a delay in exfoliation. Despite the lack of tooth alignment, both patient and mother agreed on having the orthodontic correction postponed.

One limitation of the present case report could be a widely described fact, the memory bias, especially related to minor orofacial traumas that children can suffer at young age, causing a negative answer during anamnesis. In addition,

this case seems to be the first report of twins with prolonged retention of primary teeth, which could hinder other associations between cause and effect found in the literature. Thus, it can be concluded that in identical twins the location of diagnosed anomalies can be mirror imaged. This fact should lead the professional to examine the pair of twins in order to diagnose any dental anomaly that may be present. Acute diagnosis and proper treatment at the appropriate time should be instituted to avoid functional, esthetic, and also psychological consequences in patients with over-retained teeth.

REFERENCES

1. Leblebicioglu G, Balci S, Uzümcügil A. Variable expressivity of congenital longitudinal radial deficiency and spinal dysraphism in monozygotic twins. Turk J Pediatr. 2005 Oct-Dec;47(4):390-2.
2. Onyeaso CO. Permanent double teeth and hypodontia in a pair of monozygotic twins: case report. Odontostomatol Trop. 2004 Dec 27(108):33-6.
3. Babacan H, Öztürk F, Polat HB. Identical unerupted maxillary incisors in monozygotic twins. Am J Orthod Dentofacial Orthop. 2010 Oct 138(4):498-509. doi: 10.1016/j.ajodo.2008.08.043.
4. Zhou JY, Pu JL, Chen S, Hong Y, Ling CH, Zhang JM. Mirror-image arachnoid cysts in a pair of monozygotic twins: a case report and review of the literature. Int J Med Sci. 2011 8(5):402-5. doi: 10.7150/ijms.8.402.
5. Townsend G, Richards L. Twins and twinning, dentists and dentistry. Aust Dent J. 1990 Aug 35(4):317-27. doi: 10.1111/j.1834-7819.1990.tb00779.x.
6. Goto T, Nemoto T, Okuma T, Kobayashi H, Funata N. Mirror-image solitary bone cyst of the humerus in a pair of mirror-image monozygotic twins. Arch Orthop Trauma Surg. 2008 Dec 128(12):1403-6. doi: 10.1007/s00402-007-0542-1.
7. Lenze U, Stolberg-Stolberg J, Pohlig F, Lenze F, von Eisenhart-Rothe R, Rechl H, Toepfer A. Unicameral Bone Cyst in the Calcaneus of Mirror Image Twins. J Foot Ankle Surg. 2015 Jul-Aug 54(4):754-7. doi: 10.1053/j.jfas.2014.09.017.
8. Nik-Hussein NN, Salcedo AH. Double teeth with hypodontia in identical twins. ASDC J Dent Child. 1987 May-Jun 54(3):179-81.
9. Carton A, Rees RT. Mirror image dental anomalies in identical twins. Br Dent J. 1987 Mar 7;162(5):193-4. doi: 10.1038/sj.bdj.4806071.
10. Beere D, Hargreaves JA, Sperber GH, Cleaton-Jones P. Mirror image supplemental primary incisor teeth in twins: case report and review. Pediatr Dent. 1990 Nov-Dec 12(6):390-2.
11. Lauweryns I, De Loecker M, Carels C. Mirror image in aplasia of a premolar in a monochorial twin: Case report and review. J Clin Pediatr Dent. 1992 Fall 17(1):41-4.
12. Sperber GH, Machin GA, Bamforth FJ. Mirror-image dental fusion and discordance in monozygotic twins. Am J Med Genet. 1994 May 15;51(1):41-5. doi: 10.1002/ajmg.1320510110.
13. West VC. Case reports. Mirror image twins. Aust Orthod J. 1985 Oct;9(2):243.
14. Cassetta M, Altieri F, Giordano A. Mirror imaging of impacted and supernumerary teeth in dizygotic twins: A case report. J Clin Exp Dent. 2015 Feb 1;7(1):e167-9. doi: 10.4317/jced.51815.
15. Okamoto F, Nonoyama T, Hommura S. Mirror image myopic anisometropia in two pairs of monozygotic twins. Ophthalmologica. 2001;215(6):435-438. doi: 10.1159/000050904.
16. Mensing CA. Mirror-image twins. Northwest Dent. 1983 Nov-Dec 62(6):41-2.
17. Gellin ME, Haley JV. Managing cases of overretention of mandibular primary incisors where their permanent successors erupt lingually. ASDC J Dent Child. 1982 Mar-Apr;49(2):118-22.
18- Correa-Faria P, Alcantara CE, Mesquita AT, Marques LS, Ramos-Jorge ML. Clinical and SEM characterization of prolonged retention of a primary tooth with pulpectomy. Gen Dent. 2013 May-Jun 61(3):46-8.
19- Onyeaso CO, Oneyeaso AO. Occlusal/dental anomalies found in a random sample of Nigerian schoolchildren. Oral Health Prev Dent. 2006;4(3):181-6.

THE EFFECT OF A CHEMOMECHANICAL PROTOCOL TO ELIMINATE MICROORGANISMS FROM PULPECTOMIZED PRIMARY TEETH: THREE CASE REPORTS

Maysa Lannes **Duarte**[1], Daniele Vieira **Cassol**[1], Carolina Barbosa **Andrade**[1], Natalia Lopes Pontes **Iorio**[2], Andréa **Fonseca-Gonçalves**[1], Laura Guimarães **Primo**[1]

[1]Department of Pediatric Dentistry and Orthodontics, School of Dentistry, Universidade Federal do Rio de Janeiro, Rio de Janeiro, RJ, Brazil.
[2]Department of Basic Formation, School of Dentistry, Universidade Federal Fluminense, Nova Friburgo, RJ, Brazil.

Palavras-chave: Pulpectomia. Dente Decíduo. Microbiota. Camada de Esfregaço. Relatos de Casos.

RESUMO

Introdução: A descrição da comunidade bacteriana antes e após o preparo químico-mecânico (PQM) com remoção da *smear layer* (SL) em dentes decíduos pulpectomizados tem sido pouco relatada. **Objetivo**: Esses relatos de casos descrevem a presença de microrganismos totais e *Enterococcus faecalis* em canais radiculares de incisivos decíduos antes e após PQM com remoção de SL. **Relatos dos Casos**: Amostras microbiológicas foram coletadas do canal radicular de três crianças (3,66 ± 0,58 anos) com necrose (n = 2) e inflamação pulpar irreversível (n = 1) em incisivos decíduos superiores. Após o isolamento dos dentes com dique de borracha e antissepsia do campo operatório, as coletas das amostras foram realizadas com cones de papel absorvente estéril antes e após o PQM, que incluiu irrigação com hipoclorito de sódio 2,5% seguido de ácido cítrico 6% para retirada do SL. As amostras coletadas foram analisadas imediatamente ao final dos procedimentos clínicos. As placas foram incubadas em anaerobiose durante 48 horas a 37°C. Os resultados foram expressos em unidades formadoras de colônias (UFC)/mL. **Resultados**: Dois dos três dentes apresentaram microrganismos totais antes do PQM. Um incisivo não apresentava microrganismos na coleta inicial. Nenhuma UFC foi contada nas amostras coletadas após o PQM. Além disso, o *E. faecalis* não foi observado nenhum momento, nem antes, nem depois do PQM. **Conclusão**: Não foi detectado *E. faecalis* em nenhuma amostra, porém dois dos três canais radiculares apresentavam microrganismos antes do PQM. Nos casos em que foram encontrados microrganismos inicialmente, observou-se 100% de eliminação após o protocolo aplicado.

Keywords: Pulpectomy. Primary Teeth. Microbiota. Smear Layer. Case Reports.

ABSTRACT

Introduction: Description of the bacterial community before and after chemomechanical preparation (CP) with the removal of a smear layer (SL) in pulpectomized primary teeth has been little reported. **Objective**: These case reports describe the presence of total microorganisms and *Enterococcus faecalis* in root canals of primary incisors before and after CP with SL removal. **Case Reports**: Microbiological samples were collected from the root canals of three children (3.66±0.58 years old) with necrosis (n=2) and irreversible pulpal inflammation (n=1) in maxillary primary incisors. After teeth isolation with a rubber dam and antisepsis of the operative field, the sample collections were performed with sterile absorbent paper cones before and after the CP, which included irrigation with 2.5% sodium hypochlorite followed by 6% citric acid to remove the SL. The collected samples were analysed immediately at the end of the clinical procedures. The plates were incubated anaerobically for 48 hours at 37°C. The results were expressed as colony forming units (CFU)/mL. **Results**: Two of the three teeth showed total microorganisms before the CP. One incisor had no microorganisms in the initial collection. No CFU was counted in the samples collected after CP. Moreover, *E. faecalis* was not observed any time, either before or after the CP. **Conclusions**: *E. faecalis* was not detected in any sample, yet two of the three root canals had microorganisms before CP. In cases where microorganisms were initially found, 100% elimination was observed after the applied protocol.

Submitted: December 29, 2020
Modification: March 02, 2021
Accepted: March 18, 2021

***Correspondence to:**
Professor Dr. Laura Guimarães Primo
Disciplina de Odontopediatria da FO-UFRJ
Address: Av. Prof. Rodolpho Paulo Rocco, 325 – Cidade Universitária – CCS - CEP: 21941-913 - Rio de Janeiro – RJ –Brazil Fax/phone: +55 21 3938-2098
E-mail: lprimo@pobox.com

INTRODUCTION

Several irrigating solutions have been indicated to disinfection of root canal of primary teeth, with an emphasis on sodium hypochlorite (NaOCl) at different concentrations.[1,2] However, although NaOCl has good disinfection properties, it is ineffective in removing the smear layer (SL).[3] When the SL is not removed, it may have a detrimental effect on the outcome of pulpectomies.[4,5] Moreover, NaOCl has low ability to eliminate *Enterococcus faecalis*.[6] A sequence of NaOCl and citric acid has been recommended in this regard, since citric acid has appropriate effect on SL removal.[4,6,7]

Studies that have examined the bacterial community of infected root canals of primary teeth before and after chemomechanical preparation (CP) are scarce in the literature.[8-10] These studies show a reduction in microorganisms, however, unlike the present study, they did not associate the performance of pulpectomy with the presence of microorganisms before and after CP, especially after long-term monitoring. Therefore, the analysis of this long-term correlation becomes relevant.

Thus, the aim was to describe the presence of total microorganisms and *Enterococcus faecalis* in primary root canals before and after use a chemomechanical protocol for SL removal. In addition, perform long-term follow-up of these pulpectomies.

CASE REPORTS

Pulpectomies performed in primary maxillary incisors from three preschool children (3.66±0.58 years old) that attended the Pediatric Dental Clinic of the School of Dentistry at the Universidade Federal do Rio de Janeiro (UFRJ) were reported. After completing the Term of Free and Informed Consent, their medical histories were investigated and revealed no congenital or systemic health concerns. The patients had not undergone oral and/or systemic antibiotic therapy for at least three months prior to microbiological sample collection.[11] The baseline characteristics of the patients and tooth elements are described in Table 1.

Two teeth from two patients (Pa1 and Pa2) presented necrosis with the presence of fistula and periapical lesions. Thus, pulpectomy was performed during two visits. The third patient (Pa3) presented an element diagnosed with irreversible pulpal inflammation and the pulpectomy was performed in one appointment. Coronary restoration was performed with composite resin after root canal obturation.

Two operators performed the pulpectomies based on the protocol proposed by Barcelos et al.[4], with smear layer (SL) removal from primary teeth. The protocol includes manual instrumentation and irrigation with 2.5% sodium hypochlorite followed by 10 ml of 6% citric acid to SL removal and final irrigation with 10 ml of 0.9% saline solution.

To obtain the microbiological samples, the teeth were isolated from saliva contact with a rubber dam after local anaesthesia. A field antisepsis was performed after the teeth were isolated, with 2% chlorhexidine digluconate twice for 1 minute each. Samples were obtained using sterile absorbent paper cones, at the following times (C): C1 – before accessing the pulp chamber, a cone was wiped for 10 seconds on the dental crown. The cone was immediately inserted into a sterilized tube containing thioglycolate (Difco, Sparks, USA); C2 – immediately after accessing the pulp chamber with diamond bur mounted on a high-speed hand piece, a sample was collected rubbing the paper cone perpendicularly to the coronary opening for 10s. Subsequently, the cone was inserted into a sterilized tube also containing thioglycolate; C3 – with the completion of access before the introduction of the first file, a third cone was inserted into the root canal, and left for 60 seconds. It was then inserted into an eppendorf containing 450 µl of 0.9% saline solution; and C4 – after the chemomechanical preparation, the last cone was inserted into the canal for 60 seconds. Then, this cone was inserted into another eppendorf also containing 450 µl of 0.9% saline solution. All samples were collected with absorbent number 60 paper cones inserted up to the working length in C3 and C4. The samples were collected in duplicate.

At the end of the clinical procedures, the cones were immediately taken to the Multidisciplinary Laboratory of Dental Research at UFRJ. Tubes containing paper cones embedded in thioglycolate (C1 and C2) were incubated aerobically for 14 days at 37°C. The aim of this incubation was to confirm the absence of bacterial colonies, for sterility control.

The contents of eppendorfs with samples from C3 and C4 were homogenized in a vortex mixer for 30 seconds. Aliquots (50 µl) of the suspension collected at C3 and C4, as well as their serial dilutions (up to 10^{-3}) were seeded in duplicate in appropriate culture media: BHI (Difco, Sparks, USA) for total microorganisms and Enterococcosel Agar (Difco, Sparks, USA) for *Enterococcus faecalis*. The plates were incubated anaerobically for 48 hours at 37°C. The results were expressed as colony forming units (CFU)/mL.

Samples collected from Pa1 and Pa3 demonstrated complete elimination of all microorganisms after the chemomechanical preparation. There was no growth of *E. faecalis* from any of the samples collected before or after the CP. The material collected from Pa2 showed no growth of total microorganisms or *E. faecalis* in any of the samples (Table 2).

The patients were followed-up to evaluate the clinical and radiographic success of the pulpectomies performed. Patient Pa1 did not attend the root canal filling appointment and thus follow-up of the tooth was not possible. Pa2 had been under follow-up for 29 months, and the pulpectomy could be considered successful, since the tooth exfoliated naturally, and the permanent tooth did not show any sequels (Figure 1). Pa3 had been under follow-up for 17 months, and the pulpectomy could be considered successful since there was not pain, gingival abscess, fistula or edema, and any periapical radiolucency (Figures 2).

***Table 1**: Baseline characteristics of patients (Pa) and their teeth.*

	Pa1	Pa2	Pa3
Gender	Female	Male	Male
Age	04	04	03
Tooth	61	52	62
Cause of pulp pathology	Trauma	Trauma	Dental caries
Pulpal diagnosis	Pulp necrosis	Pulp necrosis	Irreversible pulpitis
Clinical aspects	Oblique enamel fracture	Concussion	Deep caries on all faces
Clinical signs and symptoms	Absence of clinical signs and symptoms	Presence of fistula between tooth 51 and 52 and absence of pulp tissue after root canal access	Pain
Radiographic changes	Presence of periapical lesion	No radiographic changes	Coronary destruction with pulp involvement and small external root resorption

***Table 2**: Average number of microorganisms collected at different times, before (C3) and immediately after the chemomechanical preparation (C4).*

	Pa1		Pa2		Pa3	
Collect	**C3**	**C4**	**C3**	**C4**	**C3**	**C4**
Total Microorganisms (CFU/mL)	9900	ND	ND	ND	60	ND
Enterococcus faecalis (CFU/mL)	ND	ND	ND	ND	ND	ND

Note: Pa – patient. ND – not detected.

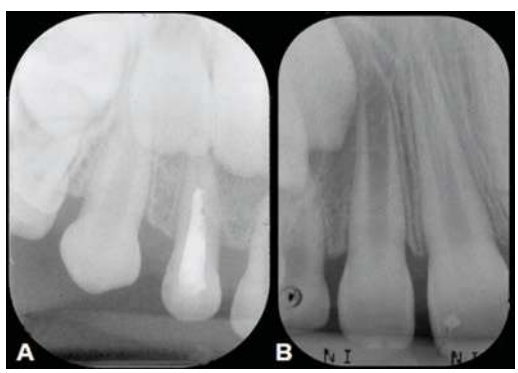

***Figure 1**: Radiographic performance of Pa2. A) Radiography performed immediately after root canal obturation and coronary restoration of primary maxillary right lateral incisor. B) After 29 months of treatment of primary maxillary right lateral incisor radiograph monitoring of the eruption of permanent maxillary right lateral incisor.*

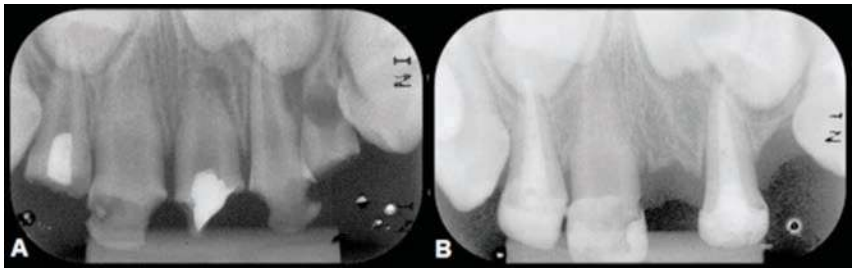

***Figure 2**: Radiographic performance of Pa3. A) Initial periapical radiograph evidencing primary maxillary left lateral incisor. B) Radiograph monitoring of primary maxillary left lateral incisor after 17 months of treatment.*

DISCUSSION

Irrigating solutions are used during pulpectomy in order to reduce intraradicular microorganisms and neutralize endotoxins, to perform vital or necrotic cell tissue dissolution, to lubricate the walls of the canal and to remove dentin particles.[12] None of the currently used irrigation solutions is ideal. Therefore, combinations of more than one solution are recommended.[4,7] In the present case reports case reports, the irrigation solutions used were 2.5% sodium hypochlorite followed by 6% citric acid. According to some authors,[8-10] sodium hypochlorite is efficient at decreasing the bacterial load when used during the chemomechanical preparation. However, this irrigant is not effective at removing the smear layer (SL), which has an important role in the success of pulpectomy.[4,5] The use of citric acid as an auxiliary irrigating solution is recommended since it removes the SL without altering normal dentinal structures,[13] being easily found in Brazil[4] and abroad.[13]

Our results showed 100% removal of bacteria from the root canals. This result may be unlikely to happen. However, we emphasize that the technique of microbial detection by bacterial colony counting was used. Molecular techniques, such as PCR-DGGE, may be more sensitive and useful for evaluating the microbiota of primary root canals.[11]

Most prevalence studies and assessments of bacterial load before and after chemomechanical preparations have investigated teeth with pulp necrosis.[8-11,14,15] Only one study described the prevalence of microorganisms in teeth with irreversible pulp inflammation, demonstrating a statistically significant difference between the numbers of bacterial cells found in teeth with irreversible pulpitis compared to necrotic teeth.[14] We observed that the tooth diagnosed with pulp necrosis and a periapical lesion had a higher number of microorganisms than those with irreversible pulp inflammation.

In addition, with regard to the pulp condition, microorganisms were found both in the tooth with dental trauma and with caries. It is worth mentioning that a greater number of total microorganisms was found before the CP in the root canal of the tooth that had suffered dental trauma since the tooth in question had pulp necrosis, while the other one with caries presented irreversible pulp inflammation.[14] This observation has clinical implications, since pulp necrosis or irreversible pulp inflammation can be caused by trauma or dental caries, and both situations leads to pulpectomy.[1]

Comparison of the performance of pulpectomy carried out on primary teeth due to caries or trauma, is scarce and its results are controversial. Randomized controlled clinical studies have shown no difference in treatment performance[4,16]. However, a prospective university-based study reported a lower frequency of survival of teeth treated endodontically by caries compared to those treated by trauma[17], suggesting perhaps less bacterial involvement in these cases. Therefore, the failure to treat traumatized teeth has a positive association with the preoperative condition of the tooth, such as the presence of periapical injury[18], reinforcing the importance of the pulp condition regardless the reason for treatment.

Among the anaerobic microorganisms, the prevalence of Enterococcus spp. in primary teeth with pulp necrosis is 50%.[15] However, in the reported cases, *E. faecalis* was not found in two teeth classified as pulp necrosis. This fact can be explained by the findings of Fabris et al.[15] that reported *E. faecalis* only in cases of necrotic teeth due to caries which had pulp exposure to the buccal environment, differently than observed in our two cases in which the teeth were diagnosed as necrotic due to trauma without exposure to the buccal cavity.

Enterococcus faecalis and surface microorganisms did not grow in any of the Pa2 samples. This is consistent with other study findings,[19] as nine of the samples collected from root canals of permanent necrotic teeth were free from bacteria. Inflammatory periapical diseases may be associated with two basic conditions: pulp necrosis associated with a rich and mixed microbiota, and aseptic traumatic necrosis, where rupture or lesion of the periodontal-pulpal vascular bundle induces aseptic pulpal necrosis.[20]

Good clinical and radiographic results of pulpectomy with SL removal with citric acid have already been reported[4,16].

Therefore, from the present case reports, the importance of using an irrigation sequence effective in elimination of microorganisms, favorable to treatment, is perceived. However, the present findings should be interpreted with caution due to the limitations inherent in this study model. The importance of carrying out more clinical research to assess the bacterial community present in root canals of primary teeth before and after chemical-mechanical preparation with removal of smear layer using citric acid is emphasized.

CONCLUSIONS

Microorganisms were present in two of the three root canals but *Enterococcus faecalis* was not detected in any sample. In cases where microorganisms were found, 100% elimination occurred after the applied protocol. Thus, we encourage the inclusion of substances that remove SL in the irrigation protocol, such as 6% citric acid, an effective and efficient solution, easily found in Brazil and abroad.

REFERENCES

1. American Academy of Pediatric Dentistry. Pulp therapy for primary and immature permanent teeth. The Reference Manual of Pediatric Dentistry. Chicago, Ill.: American Academy of Pediatric Dentistry 2020:384-92.

2. Smaïl-Faugeron V, Glenny AM, Courson F, Durieux P, Muller-Bolla M, Fron Chabouis H. Pulp treatment for extensive decay in primary teeth. Cochrane Database Syst Rev. 2018 May 31;5:1-430.

3. Pitoni CM, Figueiredo MC, Araújo FB, Souza MA. Ethylenediaminetetraacetic acid and citric acid solutions for smear layer removal in primary tooth root canals. J Dent Child. 2011;78 (3):131-7.

4. Barcelos R, Tannure PN, Gleiser R, Luiz RR, Primo LG. The influence of smear layer removal on primary tooth pulpectomy outcome: a 24-month, double-blind, randomized, and controlled clinical trial evaluation. Int J Paediatr Dent. 2012;22(5):369-81.

5. Pintor AVB, Santos MRM dos, Ferreira DM, Barcelos R, Primo LG, Maia LC. Does smear layer removal influence root canal therapy outcome? A systematic review. J Clin Pediatr Dent. 2016;40(1):1-7.

6. Estrela C, Silva JA, Alencar AHG de, Leles CR, Decurcio DA. Efficacy of sodium hypochlorite and chlorhexidine against Enterococcus faecalis – A systematic review. J Appl Oral Sci. 2008;16(6):364-8.

7. Götze GR, Cunha CBCS, Primo LSSG, Maia LC. Effect of the sodium hypochlorite and citric acid association on smear layer removal of primary molars. Braz Oral Res. 2005;19(4):261-6.

8. Valdez-Gonzalez C, Mendez-Gonzalez V, Torre-Delgadillo G, Flores-Reyes H, Gaitan-Fonseca C, Pozos-Guillen AJ. Effectiveness of oxidative potential water as an irrigant in pulpectomized primary teeth. J Clin Pediatr Dent. 2012; 37(1):31-5.

9. Tulsani SG, Chikkanarasaiah N, Bethur S. An in vivo comparison of antimicrobial efficacy of sodium hypochlorite and biopure MTADTM against Enterococcus faecalis in primary teeth: A qPCR study. J Clin Pediatr Dent. 2014;39(1):30-4.

10. Farhin K, Viral PM, Thejokrishna P, Sajjad M. Reduction in bacterial loading using MTAD as an irrigant in pulpectomized primary teeth. J Clin Pediatr Dent. 2015;39(2):100-4.

11. de Paula VA, de Carvalho Ferreira D, Cavalcante FS, do Carmo FL, Rosado AS, Primo LG, dos Santos KR. Clinical signs and bacterial communities of deciduous necrotic root canals detected by PCR-DGGE analysis: Research association. Arch Oral Biol. 2014;59:848-54.

12. Schäfer E. Irrigation of the root canal. Endod Topics 2007;1(1):11-27.

13. Hariharan VS, Nandlal B, Srilatha KT. Efficacy of various root canal irrigants on removal of smear layer in the primary root canals after hand instrumentation: a scanning electron microscopy study. J Indian Soc Pedod Prev Dent. 2010 Oct-Dec;28(4):271-7.

14. Ruviére DB, Leonardo MR, da Silva LA, Ito IY, Nelson-Filho P. Assessment of the microbiota in root canals of human primary teeth by checkerboard DNA-DNA hybridization. J Dent Child. 2007;74(2):118-23.

15. Fabris AS, Nakano V, Avila-Campos MJ. Bacteriological analysis of necrotic pulp and fistulae in primary teeth. J Appl Oral Sci. 2014;22(2):118-24.

16. Cassol DV, Duarte ML, Pintor AVB, Barcelos R, Primo LG. Iodoform Vs calcium hydroxide/zinc oxide based pastes: 12-month findings of a randomized controlled trial. Braz Oral Res. 2019;33

17. Brustolin JP, Mariath AA, Ardenghi TM, Casagrande L. Survival and Factors Associated with Failure of Pulpectomies Performed in Primary Teeth by Dental Students. Braz Dent J. 2017 Jan-Feb;28(1):121-128.

18. Tannure PN, Fidalgo TK, Barcelos R, Primo LG, Maia LC. Analysis of root canal treated primary incisor after trauma: two year outcomes. J Clin Pediatr Dent. 2012 Spring;36(3):257-62.

19. Gomes BPFA, Lilley JD, Drucker DB. Associations of endodontic symptoms and signs with particular combinations of specific bacteria. Int Endod J. 1996;29:69-75.

20. Consolaro A, Consolaro RB. Orthodontic movement of endodontically treated teeth. Dental Press J Orthod. 2013;18(4):2-7.

Revista Científica do CRO-RJ (Rio de Janeiro Dental Journal) | Instructions to authors

The Revista Científica do CRO-RJ (Rio de Janeiro Dental Journal), a periodical published quarterly aiming at divulging and promoting scientific production and interchange of information between the Brazilian and International community in the different areas of Dentistry and other fields of Health Care. The entire content of the Revista Científica do CRO-RJ (Rio de Janeiro Dental Journal) is available on the following web site http://revcientifica.cro-rj.org.br, to which there is free access. All the articles published in the Revista Científica do CRO-RJ (Rio de Janeiro Dental Journal) have a publication license CC BY-NC-ND (http://creativecommons.org/licenses/by-nc-nd).

The Revista Científica do CRO-RJ (Rio de Janeiro Dental Journal) publishes original articles, clinical case reports, protocols, reviews, letters to the editor and editorials/comments. Researches involving animals and/or human beings must be accompanied by the Certificate of Approval of a Research Ethics Committee. All articles are published in PDF format, in American English and must be submitted in this language. An abstract in Portuguese is demanded at the time of submitting and sending the final version.

Peer Review Process

All the content published by the Revista Científica do CRO-RJ (Rio de Janeiro Dental Journal) goes through the process of review by specialists. Articles submitted for appreciation are sent to the CRO-RJ librarian, who, under the supervision of the Editors-in Chief, initially assesses them with regard to the minimum standards demanded relative to form of presentation in the Revista Científica do CRO-RJ (Rio de Janeiro Dental Journal), with a view to complying with all the guidelines required for sending original articles. Once approved at this stage, the original is submitted for appreciation by the Editorial Board, to assess the merit of the work and decide about the convenience of publishing it, with or without changes. After this, the article is sent to undergo a process of evaluation carried out in the review system, by peers selected from a register of reviewers. The reviewers are always professionals from institutions different from that of the origin of the article; they are blind to the identity of the authors and place of origin of the work. After receiving both reports, the Editorial Council evaluates them, and decides about acceptance of the article without changes, rejection, or return to the authors with the suggestions about changes. The Editorial Board is responsible for returning the article to the authors for explanations, as many times as necessary, and at any time, the Editors may decide to reject the document. Each version is always analyzed by the Editorial Board that has the power of making the final decision.

Types of Articles Published

The Revista Científica do CRO-RJ (Rio de Janeiro Dental Journal) accepts the spontaneous submission of original articles, clinical case reports, protocols, reviews, letter sot the editor and editorials/review comments, and letters to the editor.

Original articles include randomized and controlled studies; studies of diagnostic tests and triage; observational cohort, case control and cross-sectional studies; other descriptive and experimental studies, as well as those of basic research with laboratory animals. The text must have a maximum of 3.000 words, excluding tables and references; the number of references must not exceed 30. Articles that report clinical trials with therapeutic interventions must be registered in one of the Registers of Clinical Trials

listed by the World Health Organization. In the absence of a Latin American Register, the Revista do CRO-RJ (Rio de Janeiro Dental Journal) suggest that the authors use the following register www.clinicaltrials.gov, of the National Institute of Health (NIH). The Identification Number must be presented in the body of the manuscript. The submission of clinical trials must adhere to CONSORT checklist (http://www.consort-statement.org/). In cases of submission of observational studies, for preparation of the manuscript, adhesion to the STROBE guidelines is requested (https://www.strobe- statement.org/index.php?id=strobe-home).

Clinical Case Reports must not exceed 2000 words, including the abstract, brief introduction, description of the case, discussion, acknowledgments (if there are any). The figures may be organized in the form of a panel. Each panel will be considered a figure. The abstract must not exceed 250 words. Case report articles must be accompanied by the term of free and informed consent signed by the participant and/or his/her legal guardian. For preparation of the manuscript, authors must adhere to the guidelines suggested in CARE (http://www.care-statement.org).

Protocols aim to guide clinical practices in the different specialties of dentistry. Description: Structured Summary (150 words); introduction; step-by-step presentation of the adopted protocol with textual description and images/figures/tables; discussion, conclusions and references.

Reviews are critical and orderly assessments of the literature relative to topics of clinical importance, with emphasis on factors such as the causes and prevention of diseases, their diagnosis, treatment and prognosis. Systematic reviews and meta-analyses are included in this category. In the body of the manuscript of the latter two types of reviews, authors must include the Registration Number of the Review protocol in PROSPERO (http://www.crd.york.ac.uk/PROSPERO/). For preparation of the manuscript, authors must follow the guidelines proposed by PRISMA (http://www.prisma-statement.org/). Authors may also submit a proposal of a review article, with a script, to the Editorial Board. If this is approved the author may develop the script and submit it for publication. Review articles must be limited to 6.000 words, excluding references and tables.

Letters to the editor must contain comments with a constructive critical content about subject matter previously published in the Revista Científica do CRO-RJ (Rio de Janeiro Dental Journal). These must be submitted directly to the Editorial Board. The maximum size is 1000 words, including a maximum of 10 bibliographic references. Whenever possible, a reply to the authors will be published together with the letter.

Editorials and comments are commissioned from authorities in specific areas. The Editorial Board may also analyze proposals of spontaneously submitted comments.

General Guidelines

The manuscript must be written using 12-point Arial font, on A4 size pages, with 1.5 line spacing, and a 3 cm margin on each side of the page, including the bibliographic references and titles/legends of tables and illustrations. The file must be presented in digital format, extension “doc” or “docx”. Each section must start on a new page, in the following order; title page, abstract in Portuguese, Abstract in English, text, acknowledgments, bibliographic references, tables (each complete table, with title and footnotes, on a separate page), figures (each complete figure, with titles and footnotes, on a separate page) and figure legends.

The following are the main guidelines about each section, according to the type of manuscript:

Title Page

The title page must contain all of the following items of information:

a) Title of the article, concise and informative, avoiding the use of superfluous terms and abbreviations; also avoid indicating the place and city where the study was conducted;

b) Abbreviated title (short title) to be stated at the top of all the pages with a maximum of 60 characters, counting the spaces;

c) The full name of each of the authors (first name and other surnames, with the last surname typed in bold-face font.

d) Department to which the authors are affiliated and/or definition of the institution or official service to which the study is tied;

e) Specific contribution of each author to the study;

f) Declaration of conflict of interest (write “nothing to declare” or a clear revelation of any interest of an economic or other nature that may cause embarrassment if it becomes known after publication of the article);

g) Name, address, telephone, fax and e-mail address of the corresponding author;

h) Source of financing or supplier of equipment and materials, if this were the case;

ABSTRACT

The abstracts (Portuguese and English) must contain a maximum of 250 words, avoiding the use of abbreviations. No words that identify the institution or city where the article was written must be put into the abstract, to facilitate blind reviewing. All the information that appears in the abstract must also appear in the article. The abstract must be structured according to the following description:

Abstract of Original Article

Introduction (optional): introduce the reader to the topic to be addressed in the article.

Aim: inform the initial hypotheses, if there are any. Define the main aim and inform only the most relevant secondary aims.

Methods: Inform the type of study design, contextual or local, the patients or participants (define the eligibility criteria, sample number, sample distribution criteria among groups, etc.), the interventions/ exposures (describe characteristics, including methods of application, variables analyzed, duration, etc.), and the criteria for measuring the outcome, including the statistical analysis.

Results: Inform the main data, confidence intervals and significance, the statistics of the findings.

Conclusions: Present only those supported by the data of the study, and that contemplate the aims, as well as their practical application with equal emphasis on the positive and negative findings that have similar scientific merits.

Abstract of Case Reports

Introduction (optional): inform the reader about the topic to be addressed.

Aim: briefly state the aims of the report.

Case Report: report the case itself.

Results: Inform the main data related to resolution of the case.

Conclusions: Present only those supported by the data of the study, and that contemplate the aims and their application.

Abstract of Reviews

Introduction (optional): briefly report the central topic of the review, and justify why it was conducted.

Aim: Inform the aim of the review, indicating whether it especially emphasizes some factor, risk, prevention, diagnosis, treatment or prognosis.

Sources of data: Describe the sources of the research, defining the databases and years researched. Briefly inform the eligibility criteria of articles and methods of extraction and evaluation of the quality of information (in cases of Systematic Reviews).

Summary of data: Inform the main results of the research, whether they are quantitative or qualitative.

Conclusions: Present the conclusions and their clinical application.

After the summary of the original articles, case reports or reviews, include three to six key-words that will be used for indexing. Use terms of Medical Subject Headings (MeSH), available in http:// www.nlm.nih.gov/mesh/ meshhome.html. When adequate descriptors are not available, it is possible to use free terms.

Abstract of Protocols

Inform the reader about the topic to be addressed and state the aim of the protocol.

ABBREVIATIONS

These must be avoided, because they hamper comfortable reading of the text. When used, they must be defined when they are used for the first time. They must never appear in the title and abstracts.

TEXTS

The text of **original articles** must contain the following sections, each with its respective sub-title:

Introduction: Clear, objective, succinct, citing only references strictly related to the topic, and seeking to justify why the study was conducted. At the end of the introduction, the aims of the study must be clearly described.

Materials and Methods: Describe the population studies, sample and eligibility criteria; clearly define the variables and detail the statistical analysis; if necessary, include references about the methods used during the course of this section. Procedures, products and items of equipment used must be described in sufficient detail to allow reproduction of the study. Furthermore, they must contain details of the brand and place of manufacture. In case of studies with human beings and/or animals, it is mandatory to include a declaration that all the procedures were approved by the research ethics committee of the institution to which the authors belong. In the absence of this, approval must be obtained from another research ethics committee indicated by the National Commission of Research Ethics of the Ministry of Health.

Results: These must be presented clearly, objectively and in a logical sequence. The information contained in tables or figures must not be repeated in the text. The option to use graphs instead of tables with a large number of data depends on the authors and Editorial Board, which may suggest changes and adjustments with the purpose of making them better suited to the guidelines and specificities of the Revista de Odontologia do CRO-RJ (Rio de Janeiro Dental Journal).

Discussion: This must interpret the results and compare them with data previously described in the literature, emphasizing the new and important aspects of the study. Discuss the implications of the findings and their limitations, as well as the need for additional researches. Avoid repetition of the results and/or superimposition between results and discussion. The conclusions must be presented at the end of the discussion, and must respond to the aims of the study, by avoiding information if inferences were not supported by the findings. The authors must place equal emphasis on favorable and unfavorable findings that have similar scientific merits. Include recommendations, when these are pertinent.

The text of **case reports** must contain the following sections, each with its respective sub-title:

Introduction: Clear, objective, succinct, citing only references strictly related to the topic, and seeking to justify why the study was conducted. Describe the aims at the end of the introduction.

Case Report: must present details of the case and procedures for performing them. Describe the follow-up data and prognosis of the case, when pertinent. CRO suggests that cases without due conclusion should be avoided. Mention the Term of Free and Informed Consent.

Discussion: Discuss the diagnostic, therapeutic and technical criteria used, among other details about the case. Discuss the clinical implications of the findings and their limitations. The conclusions must be presented at the end of the discussion, and must respond to the aims of the study, by avoiding information if inferences were not supported by the findings. The authors must place equal emphasis on favorable and unfavorable findings that have similar scientific merits. Include recommendations, when these are pertinent.

The text of **review articles** must contain the following topics: - In case of **narrative reviews**, the following are suggested:

Introduction: clear and objective, in which the authors explain the importance of the review to clinical practice, in the light of dental literature. The introduction must conclude with the aims of the review.

Materials and Methods/Data Source: It is necessary to describe the methods of data selection and extraction, followed by Data Synthesis.

Data Synthesis: This data synthesis (result/discussion) must present all the pertinent information in rich detail.

Conclusion: The conclusion section must correlate the main ideas of the review with the possible clinical applications, limiting generalization to the domains of the review.

- In cases of **systematic reviews, with or without meta-analyses**, the authors must follow the PRISMA statement (http://www.prisma-statement.org/). These reviews must contain: **Introduction**: that demonstrates the pertinence of the subject and the existent controversy with respect to the topic. At the end of the introduction, the authors should raise the focal question of the review. **Materials and Methods**: must present the search strategy; eligibility criteria of the studies; risk of bias analysis of the included studies; data extraction, and when pertinent, the strategy used for quantitative data synthesis.

Result: must respond in an orderly manner to the data searched according to the methodological design with respect to the qualitative and quantitative synthesis of the primary studies included.

Discussion: must consider interpreting the results, emphasizing resolution of the controversies related to the topic, with this being directed towards answering the focal question of the review, showing whether or not there is need for further research. The limitations of the study must also be pointed out and envisage the external validity of the study (power of generalization of the data).

Conclusion: The conclusion section must correlate the main ideas of the review with the possible clinical applications.

Acknowledgments

These must be brief and objective; they should only mention the person or institutions that made a significant contribution to the study, butthat had not fulfilled the criteria of authorship.

References

The references must be formatted in the Vancouver style, also known as the Uniform Requirements style.

The bibliographic references must be numbered and ordered according to the order in which they appear in the text, in which they must be identified by the respective superscript Arabic numbers. To list the references, do not use the Word resource of end notes or footnotes.

Articles accepted for publication, but not yet published, may be cited provided that the name of the journal is indicated and that it is "in press". Unpublished observations and personal communications may not be cited as references. If it were imperative to include information of this type in the article, it must be followed by the observation "unpublished data" or "personal communication" in parentheses in the body of the article.

The titles of periodicals must be abbreviated as recommended in the Medicus Index; a list with their respective abbreviations may be obtained by means of the publication NLM "List of Serials Indexed for Online Users", available at the address http:// www.nlm.nih.gov/tsd/serials/lsiou.html.

As follows, we present some examples of the model adopted by the Revista Científica do CRO-RJ (Rio de Janeiro Dental Journal):

Articles in periodicals:

1. Up to six authors:

Vieira AR, Bayram M, Seymen F, Sencak RC, Lippert F, Modesto A. In Vitro Acid-Mediated Initial Dental Enamel Loss Is Associated with Genetic Variants Previously Linked to Caries Experience. Front Physiol. 2017 Feb 22;8:104. doi: 10.3389/fphys.2017.00104.

2. More than six authors:

da Silva Bastos Vde A, Freitas-Fernandes LB, Fidalgo TK, Martins C, Mattos CT, de Souza IP, et. al. Mother-to-child transmission of Streptococcus mutans: a systematic review and meta-analysis. J Dent. 2015 Feb;43(2):181-91. doi: 10.1016/j.jdent.2014.12.001.

3. Organization as author:

American Academy of Pediatrics. Clinical practice guideline. Diagnosis and management of childhood obstructive sleep apnea syndrome. Pediatrics 2012;130 (3):576-684.

4. Articles with electronic publication, not yet with printed publication:

Tavares Silva C, Calabrio IR, Serra-Negra JM, Fonseca- Gonçalves A, Maia LC. Knowledge of parents/guardians about nocturnal bruxism in children and adolescents. Cranio. 2016; Jun 24:1-5. [Epub ahead of print]

Books:

Andreasen JO, Andreasen FM. Textbook and color atlas of traumatic injuries to the teeth. 4ª ed. Copenhagen: Mosby. 2007.

Chapters of Books:

Pagel JF, Pegram GV. The role for the primary care physician in sleep medicine. In: Pagel JF, Pandi-Perumal SR, editors. Primary care sleep medicine. 2nd ed. New York: Springer; 2014.

Academic Studies:

BorkowskiMM. Infant sleep and feeding: a telephone survey of Hispanic Americans [dissertation]. MountPleasant(MI): Central Michigan University; 2002.

CD-ROM:

Soils. Geographica on CD ROM. [CD ROM]. Melbourne, Australia: Random House. 1999.

Homepage/website:

Integrative Medicine Center[Internet]. Houston: University of Texas, M. D. Anderson Cancer Center; c2017 [cited 2017 Mar 25]. Available from: https://www.mdanderson.org/patients- family/diagnosis-treatment/care-centers-clinics/integrative- medicine-center.html.

Ministry of Health Documents/Decrees and Laws:

1. Brazil. Decree 6.170, of July 25, 2007. States provisions about the rules relative to Transfers of resources from the Union by means of transfer agreements and contracts and makes other provisions. Diário Oficial, Brasília, 26 jul. 2007.

2. Brazil. Ministry of Health Health Care Secretary Department of Primary Care Política Nacional de Atenção Básica / Ministério da Saúde. Health Care Secretary Department of Primary Care Brasília, Ministério da Saúde, 2012. (Série E. Legislação em Saúde)

Presentation of Paper/Study?

Pierro VSS, Maia LC, Silva EM. Effect of pediatric syrups on roughness and erosion of enamel (abstract). 82nd. IADR General Session & Exhibition; 2004 Mar 10-13, Honolulu, Hawaii. J Dent Res 2004, 83 (Special Issue A): 896.

Tables

Each table must be presented on a separate page, numbered with a Arabic numeral (1, 2, 3, etc.), in the order of appearance in the text; with single spacing between lines, and contain a summarized but explanatory title. All the explanations must be presented in footnotes and not in the title, identified with superscript letters in alphabetical order. Do not underline or draw lines within the tables and do not use spaces to separate the columns. Do not use space on either side of the symbol ± or any other symbol.

Figures (photographs, drawings, graphs, etc.)

All the figures must be numbered with Arabic numerals (1, 2, 3, etc.), in order of appearance in the text. The title must be clear and objective, and must appear at the base of the Figure. All the explanations must be presented in the legends, including those about the abbreviations used. Figures reproduced from other previously published sources must indicate this condition in the legend, in addition to being accompanied by a letter of permission from the copyright holder. Photographs must not allow identification of the patient; masking the patient's eye region in the photograph may not provide sufficient protection. Should there be possibility of identification, it is mandatory to include a written term of free and informed consent to publication. Microphotographs must present internal scales and arrows in contrast with the background.

Illustrations in color are accepted for publication online, without additional cost to the authors. However, all the figures will be transformed to black and white in the printed version. If the authors consider it essential for a certain image to be in color, even in the printed version, the authors are requested to make special contact with the editors. Computer-generated images, such as graphs, must be attached in the form of files in the following formats: .jpg, .gif or .tif, with minimum resolution of 300 dpi. Graphs must preferably be presented in two dimensions. CRO will only accept

drawings, photographs or any illustrations that contain an adequate degree of resolution for the printed version of the journal.

Figure Legends

These must be presented on a separate page, duly identified with their respective numbers.

Verification List

As part of the submission process, authors are requested to indicate their agreement with the items listed as follows:

1. All the authors will sign and submit their agreement by means of a Copyright License Declaration (and end user license), and the content of their intellectual work will be their sole and exclusive responsibility.

2. The corresponding author must prepare, with the consent of the other authors, a letter of submission of the article to the Revista Científica do CRO-RJ (Rio de Janeiro Dental Journal).

3. The submission file (manuscript) must be sent as a Microsoft Word document.

4. The title page must contain all the information required, as specified in the guidelines to the authors.

5. The abstract and key words must be formatted and submitted in English and Portuguese, following the title page.

6. The entire text must be presented in double line spacing using 12-point Arial font, and using italics instead of underlining to indicate emphasis (except in e-mail addresses. All the tables, figures and legends must be numbered in the order in which they appear in the text; each of these must be placed on a separate page, after the bibliographic references at the end of the article.

7. The text must be in accordance with the demands of style and bibliography described in the publication guidelines.

8. The references must be presented in the so-called Vancouver style, and numbered consecutively in the order in which they appear in the text.

9. Information about approval of the study by a research ethics committee must be clearly presented in the text, in the Methods section, and must be sent as an attachment.

10 All the internet addresses presented in the text must be active and ready to be clicked on.

11.Documentary proof of potential Conflict of Interest must be signed by all the authors and sent as an attachment during the submission process.

Final Considerations:

Anti-Plagiarism Policy

The Revista Científica do CRO-RJ (Rio de Janeiro Dental Journal) uses a system to detect plagiarism (available at http//:www.plagium.com/pt/detectordeplagio). When submitting an article to the journal, the authors accept that the work will be digitized in the mentioned program at the time of submission, and in the case of acceptance, prior to publication.

Ethics Policy of the Publication

All submissions will be subject to the condition that the articles have not been previously published, and have also not been simultaneously submitted to another medium of disclosure. All the authors must have read and approved the content and all the authors have declared possible conflicts of interest. The article must follow the ethical principles

of the Revista Científica do CRO-RJ (Rio de Janeiro Dental Journal), and they must also comply with the international standards of research ethics in studies with human beings and animals.

Conflict of interest and financial aid

The Revista Científica do CRO-RJ (Rio de Janeiro Dental Journal) requires all authors to declare potential conflicts of interest. Any interest or relationship, financial or other type that may be perceived as having influenced the results of a study, and the objectivity of an author, is considered a potential source of conflict of interests, and must be declared. The potential sources of conflict of interest include, but are not limited to, rights arising from patent rights or ownership of shares, membership of a board of directors, membership of an advisory board or committee of a company, and receiving advice or speaking fees from a company. If the authors are not sure whether a past or present affiliation or relationship needs to be divulged in the manuscript, please contact the editorial office at http://revcientifica.cro-rj.org.br

The existence of conflict of interests does not exclude publication.

The corresponding author is responsible for ensuring that all the authors fulfill and sign the copyright license declaration and other mandatory documents at the time of submission.

Confirmation of sending the documents

After submission, the corresponding author will receive an e-mail to confirm receipt of the article. If this e-mail of confirmation is not received after 24 hours, please contact the Revista Científica do CRO-RJ (Rio de Janeiro Dental Journal) by e-mail: revistacientifica@cro-rj.org.br. The error may have been caused by some type of spam filtering in the e-mail server.

Updating the status of the article

The initial process of evaluating the article may take up to 60 days, counted from the date of its submission. Should this period have expired, you may contact the Editorial Board to verify the present status. The Revista Científica do CRO-RJ (Rio de Janeiro Dental Journal) will inform you by e-mail, once a decision has been made. One of the following possibilities will be indicated in the reply e-mail: 1. Make adjustments to suit the guidelines and Re-submit; 2. Accepted; 3. Minor adjustments required; 4. Major adjustments required; 5. Rejected. In the latter case, the article will be summarily refused and cannot be re-submitted to the journal.

Submission of Revised Articles

The revised manuscripts must be sent within 2 months after notifying the authors about the conditional acceptance (minor or major adjustments). All the revisions must be accompanied by a letter of response to the reviewers, in which each question or suggestion made by the reviewers must be answered in sequential order. The letter must a) detail the author's reply, point by point, to each of the reviewers' comments, and b) a revised manuscript, highlighting in color, exactly what has been changed in the manuscript after revision. In addition to this, any need for adjustment or correction of the manuscript is the sole responsibility of the authors.

The authors must supply an official certificate of revision of the English language in the act of submitting the revised manuscript. The authors will be fully responsible for the costs of translation/revision of the English language.