*RIO DE JANEIRO DENTAL JOURNAL*

# REVISTA CIENTÍFICA DO CRO-RJ

revcientifica.cro-rj.org.br

**Editors-in-Chief**
**Lucianne Cople Maia**
**Andréa Fonseca-Gonçalves**

**Volume 4 - Nº2**
**May - August 2019**

ISSN 1518-5249
e-ISSN 2595-4733

IMAGEM FREEPIK

CRO RJ

The official journal of the
Conselho Regional de Odontologia do Rio de Janeiro

# REVISTA CIENTÕFICA DO CRO-RJ (RIO DE JANEIRO DENTAL JOURNAL)

Conselho Regional de Odontologia do Rio de Janeiro
**President:** Altair Dantas de Andrade
**Secretary:** Ricardo Guimarães Fischer
**Financial officer:** Outair Bastazini Filho
**Counselors:** Felipe Melo de Araujo, Igor Bastos Barbosa, Juarez D´Avila Rocha Bastos, Leonardo Alcântara Cunha Lima, Marcelo Guerino Pereira Couto, Maria Cynesia Medeiros de Barros e Sávio Augusto Bezerra de Moraes

**Editors-in-Chief/Editoras-chefes**
• Lucianne Cople Maia de Faria
Professora Titular do Departamento de Odontopediatria e Ortodontia da Universidade Federal do Rio de Janeiro - maia_lc@ufrj.br
• Andréa Fonseca-Gonçalves
Professora Adjunta do Departamento de Odontopediatria e Ortodontia da Universidade Federal do Rio de Janeiro - andrea.goncalves@odonto.ufrj.br

**Associate Editors / Editores Associados**
Alessandra Buhler Borges (Unesp – SJC), Brazil
Alexandre Rezende Vieira (University of Pittsburgh), EUA
Anna Fuks (Hebrew University of Jerusalem), Israel
Antônio Carlos de Oliveira Ruellas (UFRJ), Brazil
Glória Fernanda Barbosa de Araújo Castro (UFRJ), Brazil
Ivo Carlos Corrêa (UFRJ), Brazil
Júnia Maria Cheib Serra-Negra (UFMG), Brazil
Laura SalignacGuimarães Primo (UFRJ), Brazil
Luiz Alberto Penna (UNIMES), Brazil
Marco Antonio Albuquerque de Senna (UFF), Brazil
Maria Augusta Portella Guedes Visconti (UFRJ), Brazil
Mauro Henrique Abreu (UFMG)
Senda Charone (UnB), Brazil
Tatiana Kelly da Silva Fidalgo (UERJ), Brazil
Walter Luiz Siqueira (University of Saskatchewan), Canada
Yuri Wanderley Cavalcanti (UFPB), Brazil

**Ad Hoc Consultants**
Adilis Kalina Alerxandria de França (UERJ), Brazil
Alessandra Reis Silva Loguercio (UEPG), Brazil
Alfredo Carrillo Canela (UAA), Paraguai
Aline Abrahão (UFRJ), Brazil
Ana Maria Gondim Valença (UFPB), Brazil
Andréa Neiva da Silva (UFF), Brazil
Andréa Pereira de Morais (UNIVERSO), Brazil
Andréa Vaz Braga Pintor (UFRJ), Brazil
Bianca Marques Santiago (UFPB), Brazil
Branca Heloisa Oliveira (UERJ), Brazil
Brenda Paula F. de Almeida Gomes (FOP-UNICAMP), Brazil
Camillo Anauate Netto (GBPD), Brazil
Carlos José Soares (UFU), Brazil
Casimiro Abreu Possante de Almeida (UFRJ), Brazil
Celso Silva Queiroz (UERJ), Brazil
Cinthia Pereira M. Tabchoury (FOP/UNICAMP), Brazil
Cláudia Maria Tavares da Silva (UFRJ), Brazil
Cláudia Trindade Mattos (UFF), Brazil
David Normando (UFPA), Brazil
Denise Fernandes Lopes Nascimento (UFRJ), Brazil
Eduardo Moreira da Silva (UFF), Brazil
Fabian Calixto Fraiz (UFPR), Brazil
Gisele Damiana da Silveira Pereira (UFRJ), Brazil
Issis Luque Martinez (PUC), Chile
Jonas de Almeidas Rodrigues (UFRGS), Brazil
Jônatas Caldeira Esteves (UFRJ), Brazil
José Valladares Neto (UFG), Brazil
Kátia Regina Hostilio Cervantes Dias (UFRJ), Brazil
Leopoldina de Fátima Dantas de Almeida (UFPB), Brazil
Lívia Azeredo Alves Antunes (UFF/Nova Friburgo), Brazil
Luciana Pomarico Ribeiro (UFRJ), Brazil
Maíra do Prado (FO-UVA), Brazil
Maria Cynésia Medeiros de Barros (UFRJ), Brazil
Maria Eliza Barbosa Ramos (UERJ), Brazil
Maria Elisa Janini (UFRJ), Brazil
Mariane Cardoso (UFSC), Brazil
Mario Vianna Vettore (UFMG), Brazil
Maristela Barbosa Portela (UFF), Brazil
Matheus Melo Pithon (UESB), Brazil
Matilde da Cunha Gonçalves Nojima (UFRJ), Brazil
Martinna Bertolini (University of Connecticut), USA
Michele Machado Lenzi da Silva (UERJ), Brazil
Miguel Muñoz (University of Valparaiso), Chile
Mônica Almeida Tostes (UFF), Brazil
Paula Vanessa P. Oltramari-Navarro (UNOPAR), Brazil
Paulo Nelson Filho (FORP),Brazil
Patrícia de Andrade Risso (UFRJ), Brazil
Rafael Rodrigues Lima (UFPA),Brazil
Rejane Faria Ribeiro-Rotta (UFG), Brazil
Roberta Barcelos (UFF), Brazil
RogérioLacerda Santos (UFJF) Brazil
Ronaldo Barcellos de Santana (UFF), Brazil
Ronir Ragio Luiz (IESC/UFRJ), Brazil
Samuel Jaime Elizondo Garcia (Universidad de León), México
Sandra Torres (UFRJ), Brazil
Taciana Marco Ferraz Caneppele (UNESP), Brazil
Tiago Braga Rabello (UFRJ), Brazil
Thiago Machado Ardenghi (UFSM), Brazil

**Disclaimer**
The Publisher, CRO-RJ and Editors cannot be held responsible for errors or any consequences arising from the use of information contained in this journal; the views and opinions expressed do not necessarily reflect those of the Publisher, CRO-RJ and Editors, neither does the publication of advertisements constitute any endorsement by the Publisher,CRO-RJ and Editors of the products advertised.

**MAIL/CORRESPONDÊNCIA**
All mail shoud be sent to revistacientifica@cro-rj.org.br
Toda correspondência deve ser enviada à Secretaria no endereço abaixo:
revistacientifica@cro-rj.org.br

ISSN (print): 1518-5249
e-ISSN 2595-4733

CONSELHO REGIONAL DE ODONTOLOGIA DO RIO DE JANEIRO
REVISTACIENTÍFICADOCRORJ(
RIODEJANEIRODENTALJOURNAL)
Rua Araújo Porto Alegre, 70, 5º andar, Centro, Rio de Janeiro-RJ - Cep 20030-015 • Tel. (21) 3505-7600. - Site: www.cro-rj.org.br
**Graphic Design**: Claudio Santana
**Librarian**: Vinicius da Costa Pereira
**Trainee Librarian**: Aline Chahoud
**Information Technology Intern**: Moisés Limeira e Paulo Felippe
**Available on**: www.revcientifica.cro-rj.org.br
2018 - Conselho Regional de Odontologia do Rio de Janeiro

# Revista Científica do CRO-RJ (Rio de Janeiro Dental Journal)

## Volume 4, Number 2


**Summary**
**Contents**

## Editorial


**The difficult science in making science difficult.**
Sergio Eduardo de Paiva Gonçalves ..... 1


## Review


**Association between p561t polymorphism in growth hormone receptor gene and mandibular prognathism: systematic review and meta-analysis.**
Mariele Andrade do Nascimento, Daniela Barroso de Oliveira, Caio Luiz Bitencourt Reis, Letícia Maira Wambier, Karla Carpio Horta, Fabio Lourenço Romano, Léa Assed Bezerra da Silva, Raquel Assed Bezerra da Silva, Paulo Nelson-Filho, Erika Calvano Kuchler ..... 2


## Original Article


**Pulpal and periapical response of dogs' teeth after pulpotomy and use of enamel matrix derivative as a capping agent.**
Léa Assed Bezerra da Silva, Lisa Danielly Curcino Araujo, Marcela Martín del Campo Fierro, Francisco Wanderley Garcia de Paula-Silva, Raquel Assed Bezerra da Silva, Paulo Nelson Filho, Alberto Consolaro, Mário Roberto Leonardo ..... 12

**Parents and Caregivers'Knowledge and attitudes towards children's toothbrushing.**
Naiara Oliveira Carvalho, Hilda Lara Prado Vasconcelos, Cristiane Tomaz Rocha, Beatriz Gonçalves Neves ..... 19

**Maxillary dental midline deviation in the patient perspective.**
Thaís Magalhães Galindo, Licínio Esmeraldo da Silva, Andréa Fonseca Jardim da Motta, Adriana de Alcantara Cury-Saramago ... 27

***Myosin 1h* and the soft tissue profile of african american females with mandibular prognathism**
John Burnheimer, Kathleen Deeley, Alexandre R. Vieira ..... 35


## Case Report


**Oral findings in Robinow Syndrome: A case report in pediatric patient.**
Camila Nassur, Adílis Kalina Alexandria , Luciana Pomarico , Gloria Fernanda Barbosa de Araújo Castro ..... 42

**Development of odontoma in the permanent dentition after intrusion of primary incisors: case report.**
Daniela Maria Carvalho Pugliesi, Valdeci Elias dos Santos Junior, Camila Maria Beder Ribeiro, Lisa Danielly Curcino Araujo, Pedro Jorge Cavalcante Costa, Guilherme Costa do Amaral ..... 46

**Dentomaxillofacial sequelae resulting from a chemoradiotherapy against rhabdomyosarcoma: 6-Year follow-up.**
Adilis Kalina Alexandria, Patricia Nivoloni Tannure, Camila Nassur, Gloria Fernanda Barbosa de Araújo Castro, Ivete Pomarico Ribeiro de Souza. ..... 52

**Unusual case of ankyloglossia recurrence after frenectomy in a child with cerebral palsy.**
Fernanda Michel Tavares Canto, Aline dos Santos Letieri, Michelle Agostini, Oswaldo de Castro Costa Neto, Gloria Fernanda Barbosa de Araújo Castro. ..... 56

**Orofacial findings and dental care management in a patient with robinow syndrome.**
Marina Fernandes Sena, Paôla Caroline da Silva Mira, Thais Tedeschi dos Santos, Carolina Paes Torres, Francisco Wanderley Garcia Paula-Silva, Fábio Lourenço Romano, Sandra Maria Garcia da Silveira, Karina Mayra de Queiroz Brito, Alexandra Mussolino de Queiroz. ..... 60

**Aesthetic recovery of the smile using a simple and effective application of prepolymerized composite veneers Prepolymerized resin veneers**
Cínthia Marques Sperduto, Jeane Batista dos Santos Cavalcante, Núbia Gomes de Santana, João Victor Frazão Câmara, Isabel Ferreira Barbosa, Gisele Damiana da Silveira Pereira ..... 67

# THE DIFFICULT SCIENCE IN MAKING SCIENCE DIFFICULT

What to do when your manuscript is violently debased by the reviewers of a journal? What to understand of such forceful affront to your knowledge and ethical principles? Why is it necessary to look abroad for quality and creativity when these qualities areinherent to Brazilians? Why does the feeling of "Colony" rule over the country that occupies the second place in scientific publication in the area of Dentistry? Why do regulators of the Brazilian academic management system themselves devalue Brazilian journals and maintain unclear rules policy[1]?

Amazingly, these are questions and reflections that are apparently not restricted to our area of knowledge.

History has conditioned us to value what comes from abroad over what can be generated in our own country. The foreign singer is better, more prepared; European food is more sophisticated; Americans are better educated and more capable; We export our best food and our market carries goods of a lesser quality. We are trying desperately to publish our most relevant studies abroad, without even thinking that Brazilian journals are now available in an international language (English) and indexed in an international databasis, allowing free and online access to the manuscript from anywhere in the world.

The disciple surpasses the master and this is the natural course of human development, but it seems that Brazil insists on maintaining itself on the contrary of universal learning.

Perhaps the reviewer's aggressive response keeps him at the top of the knowledge hierarchy, or at least it makes him think this is true. Perhaps you will reflect on these aspects when you come to a denial addressed to Mr. "Dear Brazil", clarifying the denial by the excessive number of papers submitted to the newspaper.

Perhaps preprints can contribute to a truer discussion of the science produced by everyone, which seems to be a trend of open publishing. As well as the "Pint of Science", which brings science directly to the public with lectures in bars, makes the population aware of the importance of investing in science and how the results of these studies influence the future of humanity[2].

Valuing the publication in national journals may perhaps put us on a higher level of awareness of the strength of Brazilian science, which is necessary for the researchers themselves.

Perhaps economic supremacy can really favor the science that needs inputs. But creativity and a sense of observation generate ideas and results that can surprise and overcome the scarity of resources. Perhaps still, the real difference between European or American science and Brazilian science is that we need to go to great pain to prove our competence.

**REFERENCES**

1. Silva, M. R. Editorial – Clinics 2010, v.65 (10), p.935-36.
2.Pontes, N. Editorial- Science in New Spaces. Braz Dent Sci 2019, v.22, n3, p. 295-6.

**Sergio Eduardo de Paiva Gonçalves**
Full Professor UNESP
Editor-in-chief of Brazilian Dental Science journal

# ASSOCIATION BETWEEN P561T POLYMORPHISM IN GROWTH HORMONE RECEPTOR GENE AND MANDIBULAR PROGNATHISM: SYSTEMATIC REVIEW AND META-ANALYSIS

Mariele Andrade do **Nascimento**[1], Daniela Barroso de **Oliveira**[2*], Caio Luiz Bitencourt **Reis**[2], Letícia Maira **Wambier**[3], Karla Carpio **Horta**[1], Fabio Lourenço **Romano**[1], Léa Assed Bezerra da **Silva**[1], Raquel Assed Bezerra da **Silva**[1], Paulo **Nelson-Filho**[1], Erika Calvano **Küchler**[1]

[1]Department of Pediatric Dentistry, School of Dentistry of Ribeirão Preto/University of São Paulo, Ribeirão Preto, SP, Brazil.
[2]Department of Clinic and Surgery, School of Dentistry, Federal University of Alfenas, Alfenas, MG, Brazil.
[3]School of Health and Biological Sciences, Positivo University, Curitiba, PR, Brazil.

**Palavras-chave:** Polimorfismo Genético. Classe III de Angle. Prognatismo. Nucleotídeo Único. Proteína Ligante à Somatotropina.

**RESUMO**

**Objetivo:** Por meio de uma revisão sistemática e meta-análise, o objetivo deste estudo foi avaliar a associação entre o polimorfismo P561T em GHR (rs6184) com a maloclusão de Classe III esquelética em diferentes populações. **Métodos:** Uma ampla pesquisa de estudos foi realizada utilizando os bancos de dados PubMed, Web of Science, Scopus, Cochrane, Google Scholar e Open Grey até dezembro de 2018. O desenho do estudo de acordo com o PECOS foi: P-Pacientes ortodônticos; Polimorfismo P561T em GHR; C-ausência de polimorfismo P561T em GHR ; O-alterações na dimensão linear das medidas maxilares e mandibulares; S- Estudos transversais. Os estudos selecionados foram qualificados pela qualidade metodológica em uma escala de 10 pontos. A avaliação em subgrupos. O subgrupo foi realizada de acordo com as medidas lineares avaliadas em dois ou mais estudos, como a seguir: altura corporal, N-S, A'-PTM ', Gn-Go, Pog'-Go. Foi utilizado o modelo de efeito fixo e as diferenças médias foram realizada usando a metanálise de variância inversa. O $I^2$ (95%) foi utilizado para medir heterogeneidade estatística entre estudos, em que valores de $I^2$ de 25%, 50% e 75% significaram baixa, média e alta heterogeneidade, respectivamente. **Resultados:** A pesquisa inicial identificou 146 estudos. Após excluir resumos duplicados, 138 foram selecionados. Sete estudos foram incluídos na revisão sistemática. Apenas 1 estudo foi classificado como de baixa qualidade metodológica. Três estudos foram incluídos na meta-análise. A meta-análise demonstrou uma associação entre a medida linear Co-Go e o genótipo CC (p<0,0001), com diferença média e intervalo de confiança de 3,79 [2,06; 5,52]. CC foi associado com maior altura mandibular. **Conclusão:** O polimorfismo P561T em GHR está associado à medida Co-Go em asiáticos, com baixo nível de evidência.

**Keywords:** Genetic Polymorphism. Angle Class III. Prognathism. Single nucleotide. Somatotropin-Binding Protein.

**ABSTRACT**

**Objective:** Through a systematic review and meta-analysis, the aim this study was evaluating the association between the P561T polymorphism in *GHR* (rs6184) with skeletal Class III malocclusion in different populations. **Methods:** A broad search for studies was conducted using the databases: PubMed, Web of Science, Scopus, Cochrane, Google Scholar and Open Grey until December 2018. The study design according to PECOS was: P-Orthodontic patients; E- polymorphism P561T in GHR; C- absence of polymorphism P561T in GHR; O- linear dimension alterations in maxilla and mandibular measurements; S- Cross-sectional studies. The selected studies were qualified by 10-point scoring sheet methodological quality. The subgroups evaluation was performed according to the linear measurements evaluated in two or more studies, as follows: body height, N-S, A'-PTM', Gn-Go, Pog'-Go, and Co-Go.A fixed effect model was used and the mean differences were performed using the inverse-variance meta-analysis. The $I^2$ (95%) was used to measure statistical heterogeneity between studies, where $I^2$ values of 25%, 50%, and 75% signified low, medium, and high heterogeneity, respectively. **Results:** The initial search identified 146 studies. After excluding duplicate abstracts, 138 were selected. Seven studies were included in the systematic review. Only one study was classified as having low methodological quality. Three studies were included in the meta-analysis. The meta-analysis demonstrated an association between the Co-Go linear measure and CC genotype (p<0.0001), with a mean difference and confidence interval of 3.79 [2.06, 5.52]. CC was associated with greater mandibular height. **Conclusion:** The polymorphism P561T in *GHR* is associated with Co-Go measurement in Asians, with low level of evidence.

Submitted: March 6, 2019
Modification: September 14, 2019
Accepted: September 20, 2019

***Correspondence to:**
Daniela Silva Barroso de Oliveira
Address: Rua Gabriel Monteiro da Silva, 700, Centro, Alfenas, MG, Brazil.
Zip Code: 37130-000
Telephone number: +55 (35)3701-9410
E-mail: barrosodaniela@hotmail.com

# INTRODUCTION

Malocclusion is a misalignment or incorrect relation of teeth and jaws[1] that can lead to alterations in facial profile with esthetic impact,[2] limition in the masticatory function,[3] higher risk for dental trauma[4] and compromised quality of life[5]. Skeletal Class III malocclusion is one of the most severe maxillofacial skeletal alteration in orthodontics. It may be associated to excessive mandibular growth, inefficient maxillary growth or a combination of both conditions.[6-8]

In the past few decades, many association studies with candidate genes[8-13] and genome-wide screenings have evaluated the etiology of skeletal Class III malocclusion in different populations.[14-18] These studies indicated different chromosomal locations shared by the affected subjects. The variety of chromosomal locations identified by these previous studies may be due to the polygenic model of this trait.[18]

The gene growth hormone receptor (*GHR*) has been a widely studied candidate gene in the orthodontic field.[7,9–12,19,20] The polymorphism P561T in *GHR* was a missense mutation, causing a transversion of amino acid from cytosine to adenine and changing codon 56 from proline to threonine.[21] The human *GHR* gene is encoded by a single gene on chromosome 5p13.1. GHR is one of the probable candidates for determining morphological traits, because growth hormone (GH) is a key regulator of bone growth.[10] GH is a peptide hormone made in the anterior pituitary gland that has an important role in the regulation of the growth and development of the maxilla and craniofacial complex. GH binds to specific cell surface receptors to initiate these processes and activate diverse intracellular signaling pathways.[7] Although many studies evaluated the association between the polymorphism P561T in *GHR* with skeletal Class III malocclusion,[7,9–12,19,20] it is unclear if the polymorphism plays a role in its etiology. Therefore, the aim of this study is to perform a systematic review and meta-analysis to evaluate the association between the polymorphism P561T in *GHR* with skeletal Class III malocclusion in orthodontic patients.

# MATERIAL AND METHODS

### Eligibility criteria

This study was performed in agreement with the Preferred Reporting Items for Systematic Review and Meta-Analyses (PRISMA) Statement [22] and was registered with PROSPERO (CRD 42016035790).

The inclusion criteria included original, cross-sectional, case-control, or cohort studies that evaluated if the polymorphism P561T in *GHR* is associated with skeletal class III malocclusion in healthy orthodontic patients. Publication dates, sample sizes, and statistical analyses were not a restriction. To certify the broadest possible search, no language restriction was applied. Unpublished manuscripts and theses, book chapters, case reports, and case studies were excluded.

### Search strategy

Electronic databases were used for the selection of the primary studies: PubMed (Jan 1996/1966– Dez 2018), Web of Science (1900– Dez 2018), Scopus (1960– Dez 2018), Cochrane (1993/1990- Dez 2018), Google Scholar (Nov 2004- Dez 2018) and OpenGrey (1997- Dez 2018). No filters or limits were used in the searches. The descriptors were selected from a combination of previous searches in MeSH (Medical Subject Headings) terms and the most cited terms in relevant previous publications. The search was conducted using the following terms from Medical Subject Heading terms (MeSH) and their combinations: "genes" (MeSH terms) OR "polymorphism, genetic" (MeSH terms) OR "polymorphism, single nucleotide" (MeSH terms) AND "*ghr*" (MeSH terms) OR "growth hormone receptor" (MeSH terms) OR "somatotropin binding protein" (MeSH terms) AND "malocclusion, Angle class III" (MeSH terms) OR "prognathism" (MeSH terms) OR "mandible" (MeSH terms) OR "skeletal class III malocclusion" (tw). Moreover, the bibliographies of the final selected articles were hand searched to identify any relevant articles that were not identified previous.

### Study selection

Two reviewers independently read all retrieved articles' titles and abstracts. If one reviewer considered a publication as having met the inclusion criteria, the full article was obtained. Abstracts potentially eligible, as well as abstracts that did not presented enough information, were included for full-text analysis. Differences regarding eligibility after evaluation of the full text was resolved through consensus, and, when differences still persisted, a third reviewer was accessed to reach a final decision.

### Data extraction

Two reviewers independently performed the data extraction. General information was collected from each article. The specific characteristics were collected: author/year, ethnicity/country, age range in years, sample size, case definition, methods used in the cephalometric analysis to evaluate facial measures, molecular biology technique, and author's conclusion.

The authors of the included articles were contacted by email for the identification of additional information.

### Quality assessment

The authors adopted a 10-point scoring sheet, based on published criteria recommendations on the assessment

of the quality of epidemiological genetic association studies.[23] Each quality criterion was assessed as present (yes, score of 1 point) and absent or undetermined (no, score of 0 points). Two authors independently scored all the articles. In any case of disagreement, a consensus regarding the final score was reached. A final quality score was obtained by summation of each component, providing a range of 0–10 for each article. Based on the score, the articles were classified into three categories: i) high methodological quality: presenting 8 or more criteria; ii) moderate methodological quality: presenting 5–7 criteria; iii) low methodological quality: presenting 4 or fewer criteria. Therefore, the studies were also classified as having high, moderate, and low quality of evidence. Only studies with high and moderate evidence were used in the meta-analysis.

### Meta-analysis

### Data synthesis and meta-analysis

The outcome was presented in all included studies as continuous data. For the meta-analysis, we extracted the mean and the standard deviation. The subgroup evaluation was performed according to the linear measurements evaluated in two or more studies, as follows: body height, N-S, A'-PTM', Gn-Go, Pog'-Go, and Co-Go.

Two studies with high and moderate evidence were used in the meta-analysis. A fixed effect model was used for the meta-analysis. The mean differences in CC and CA genotypes were performed using the inverse-variance meta-analysis. The $I^2$ was used to measure statistical heterogeneity between studies, where $I^2$ values of 25%, 50%, and 75% signified low, medium, and high heterogeneity, respectively.[24] The meta-analysis calculation and Forest plot creations were performed with Rev Man 5.3. with the studies that present moderate and high methodological quality, full data regarding linear measurements.

### Assessment of the quality of evidence using GRADE

We graded the quality of the evidence for each outcome across studies (body of evidence) using the Grading of Recommendations: Assessment, Development and Evaluation (GRADE) (http://www.gradeworkinggroup.org/). This technique allows one to determine the overall strength of evidence for each meta-analysis.[25] Using the GRADE framework, body of evidence for observational studies is initially classified as low quality. This body of evidence can be rate up if there is special strengths or the study lack limitations. Factors that may rate up the quality of evidence for observational studies is the presence of a large magnitude of an effect (upgrade in one or two levels), presence of a dose-response gradient (upgrade one level) and by the effect of a plausible residual confounding (upgrade one level).

The GRADE pro Guideline Development Tool, available online (www.gradepro.org), was used to create Summary-of-findings table as suggested in the Cochrane Handbook for Systematic Reviews of Interventions.[26]

## RESULTS

The search strategy is presented in Table 1, which describes the study selection process and the total number of references. After the analysis of the full text and summary, 6 studies were included. We manually searched one study, totaling 7 studies included in the systematic review.

The data extracted of the included studies are presented in Table 2. Five studies were performed on Asian populations,[9–11,19,20] one study was performed in Turkey,[7] and one was performed in the United States of America.[12]

Table 3 reported the qualitative scoring of the included articles. Four studies[10–12,19] were classified as high methodological quality, 2 studies were classified as moderate methodological quality[7-9] and 1 study[20] was classified as low methodological quality.

Tassopoulou-Fishell et al., did not evaluate linear measurements.[12] Two studies did not fully report the data in the result section.[7,19] We sent a request for additional data by email to the corresponding authors, who did not reply to the request. Sasaki et al. was excluded due its low methodological quality.[20] Therefore, only 3 studies were eligible to be subject to the meta-analyses (Figure 1).[9-11]

Forest plots of the subgroups are presented in Figure 2. The overall heterogeneity ($I^2$) among the articles was low. The only linear measure that presented statistical association with the polymorphism P561T in *GHR* was Co-Go. A statistical difference was found for Co-Go linear measurements, in which the CC genotype presented greater measurements than the CA genotype ($p<0.0001$), with a mean difference and confidence interval of 3.79 (2.06, 5.52). The body height and the other facial linear measurements (N-S, A'-PTM', Gn-Go and Pog'-Go) were not associated with polymorphism P561T in *GHR* ($p>0.05$).

Assessment of the quality of evidence is described In the summary-of-findings table (Table 4), the meta-analysis was graded as low quality for body height, N-S, A' PTM', Gn-Go, Pog'-Go, and Co-Go. The reasons for downgrading the evidence were that the studies were cross-sectional and were at "unclear" risk of bias and presence of a dose-response gradient (Table 4).

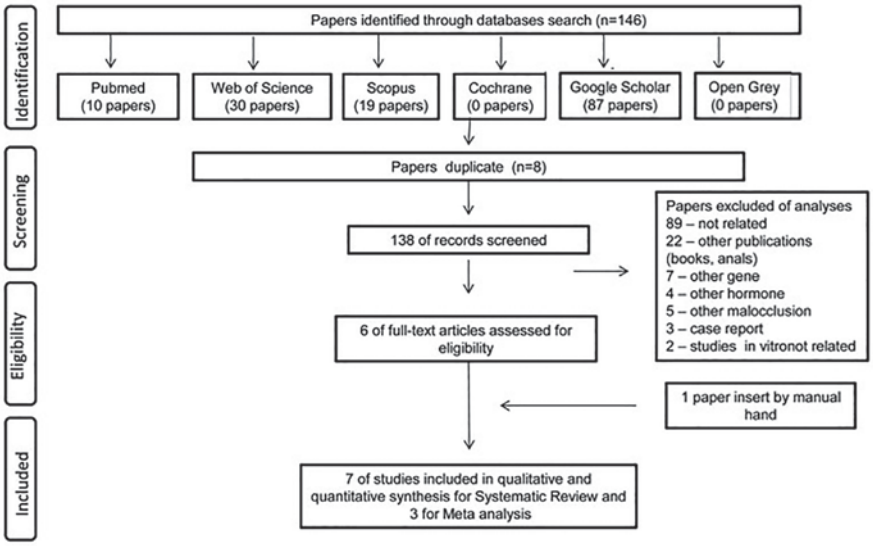


***Figure 1**: Stages of the studies selection progression according to Prisma Statement.*

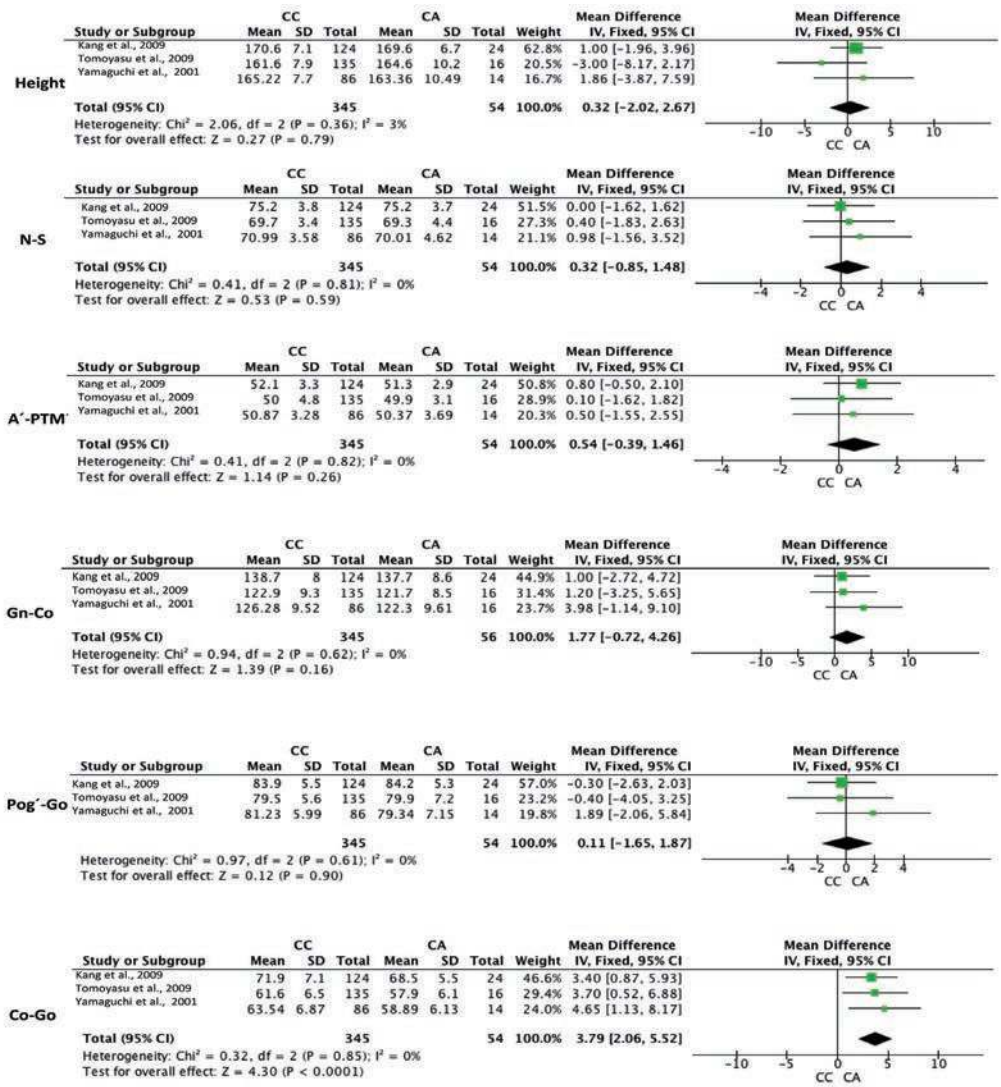


***Figure 2**: Forest plot of cephalometric measures.*

***Table 1:*** *Search Strategy in databases*

| Type of term | Search terms used: MeSH terms | PubMed | Web of Science | Scopus | Cochrane | Google Scholar | Open Grey |
|---|---|---|---|---|---|---|---|
| **Phenotype** | Malocclusion OR Angle class III OR Prognathism OR Mandible | 96046 | 35155 | 164423 | 190 | 514000 | 0 |
| **Genetics** | Genes OR Polymorphism, Genetic OR Polymorphism, Single nucleotide | 1442659 | 2545514 | 5850356 | 602 | 500,000 | 0 |
| | GHR OR Growth hormone receptor OR Somatotropin binding protein | 27783 | 22696 | 22699 | 266 | 23900 | 0 |
| **Combined terms** | (Malocclusion OR Angle class III OR Prognathism OR Mandible) AND (Genes OR polymorphism, genetic OR polymorphism, single nucleotide) AND (GHR OR growth hormone receptor OR somatotropin binding protein) | 14 | 37 | 106 | 2 | 13400 | 0 |

***Table 2**: Characteristics of the included studies.*

| Author/Year | Study location | Age in years | Sample size (case/control) Case Definition | Cephalometric landmarks/ measurements | Molecular biology technique | Authors' conclusion regarding the polymorphism P561T |
|---|---|---|---|---|---|---|
| Yamaguchi *et al*. 2001 | Japanese | 18-49 | 100 (Case and control was not dicothomized)The phenotype was evaluated as continuous variable | Body height, N-S, A´-ptm, Gn-Co, POG´-Go, Co-Go, and Body height/Co-Go | RFLP-PCR | Associated with Co-Gn measurement. |
| Zhou *et al*. 2005 | Chinese | 20-35 | 140 (Case and control was not dicothomized)The phenotype was evaluated as continuous variable | N-S, N-Ba, N-Ar, S-Ba, S-Ar, A´-PTM´, Co-Go, Ar-Go, Go-Gn, Go-POG, Co-Gn, Ar-Gn, Ar-Pog, N-Me, and S-Go | PCR and sequencing | Was not associated with any measurement parameter. |
| Tomoyasu *et al*. 2009 | Japanese | 18-58 | 167 (Case and control was not dicothomized)The phenotype was evaluated as continuous variable | Body height, N-S, A´PTM´, Gn-Co, Pog´-Go, and Co-Go | PCR and sequencing | Associated with Co-Gn measurement |
| Kang *et al*. 2009 | Korean | 18-58 | 159 (87 Class I/44 Class II/28 Class III)The phenotype was also evaluated as continuous variable - Craniofacial linear measurements | Body height, N-S, A´-PTM´, Gn-Co, Pog´-Go, and Co-Go | PCR and sequencing | Contributes to the mandibular ramal height |
| Sasaki *et al*. 2009 | Japanese | 3-13 | 60 (33 mandibular protrusion/27 Class I)The phenotype was also evaluated as continuous variable - Craniofacial linear measurements | Cd-Go, Pog'-Go, Gn-Cd,A'-Ptm', Gn-Cd, and Ar-Go-Mn | RFLP-PCR | Was not associated with mandibular prognathism |
| Tassopoulou-Fishell *et al*. 2012 | USA | 11-52 | 79 (44 mandibular protrusion/35 Class I)The phenotype was evaluated as Class I and Mandibular prognathism | Steiner´s ANB, Wits appraisal and Downs´ A-B ´lane | Real time PCR | Was not associated with mandibular prognathism. |
| Bayram *et al*. 2014 | Turkish | Older than 16 | 200 (101 mandibular prognathism/99 Class I)Case defined as ANB and Wits <0°.The phenotype was also evaluated as continuous variable | ANB, Wits, Ar-Go, Go-Me, Go-Pog´, Co-Gn, A´-Ptm, and Co-A | RFLP-PCR | May have an effect on mandibular growth. |

***Table 3**: Methodological scoring protocol based on quality assessment for selected studies.*

| Criteria evaluated | Included studies | | | | | | |
|---|---|---|---|---|---|---|---|
| | Yamaguchi *et al.* 2001* | Zhou *et al.* 2005* | Tomoyasu *et al.* 2009* | Kang *et al.* 2009* | Sasaki *et al.* 2009 | Tassopoulou-Fishell *et al.* 2012 | Bayram *et al.* 2014 |
| Control group | 1 | 1 | 1 | 1 | 0 | 1 | 1 |
| Hardy–Weinberg equilibrium | 0 | 1 | 1 | 1 | 0 | 1 | 1 |
| Case group | 1 | 1 | 1 | 1 | 0 | 1 | 1 |
| Reproducibility | 1 | 1 | 1 | 1 | 0 | 1 | 1 |
| Blinding | 0 | 0 | 0 | 0 | 0 | 0 | 0 |
| Power calculation | 0 | 0 | 0 | 0 | 0 | 0 | 0 |
| Statistics | 1 | 1 | 1 | 1 | 1 | 1 | 1 |
| Corrected statistics | 1 | 1 | 1 | 1 | 0 | 1 | 0 |
| Independent replication | 1 | 1 | 1 | 1 | 1 | 1 | 1 |
| Compilation of reported associations and outcomes | 1 | 1 | 1 | 1 | 1 | 1 | 1 |
| **Score** | **7** | **8** | **8** | **8** | **3** | **8** | **7** |

*Note: Quality assessment criteria were adapted by Clark and Baudouin [23] For the quantification of criteria: "1" means present, and "0" absent. Total score is 10 * Case and control was not defined, the phenotype was evaluated as continuous variable.*

***Table 4***: *Summary of findings table.*

| **Patient or population:** Orthodontic patients<br>**Intervention:** polymorphism P561T in GHR<br>**Comparison**: absence of polymorphism P561T in GHR | | | | | |
|---|---|---|---|---|---|
| **Outcomes** | **Anticipated absolute effects†**(95% CI) | | Relative effect (95% CI) | Nº of participants (studies) | Quality of the evidence (GRADE) |
| | **polymorphism P561T in GHR** | **absence of polymorphism P561T in GHR** | | | |
| **Height** | – | – | MD 3.32 SD lower (-2.02 to 2.67) | 399 (3 cross-sectional) | **%%LOW QUALITY‡ |
| **N-S** | – | – | MD 3.32 SD lower (-0.85 to 1.48) | 399 (3 cross-sectional) | **%%LOW QUALITY ‡ |
| **A'-PTM** | – | – | MD 0.54 SD lower (-0.39 to 1.46) | 399 (3 cross-sectional) | **%%LOW QUALITY ‡ |
| **Gn-Co** | – | – | MD 1.77 SD lower (-0.72 to 4.26) | 401(3 cross-sectional) | **%%LOW QUALITY ‡ |
| **Pog'-GO** | – | – | MD 0.11 SD lower (-1.65 to 1.87) | 399 (3 cross-sectional) | **%%LOW QUALITY ‡ |
| **Co-Go** | – | – | MD 3.79 SD lower(2.06 to 5.52) | 399 (3 cross-sectional) | **%%LOW QUALITY ‡ |

*Note: †The risk in the intervention group (and its 95% CI) is based on the assumed risk in the comparison group. ‡Imprecision and risk of bias. CI, confidence interval; MD, mean difference; SD, standard difference.*

# DISCUSSION

Our study demonstrated that the polymorphism P561T in *GHR* may be biologically relevant to craniofacial development and could act as a genetic marker for mandibular ramus height growth (condyle-gonion). At position 1777 in *GHR*, a transversion of amino acid from cytosine to adenine changes codon 561 from proline to threonine, which affects the cytoplasmic domain of the *GHR*. The Forest plot demonstrated that the homozygotic CC genotype was strongly associated with greater Co-Go measurement.

The others evaluated facial linear measurements were not associated with the polymorphism P561T in *GHR*. However, it is important to consider the heterogeneity of the skeletal Class III malocclusion. It is not surprising that genetic linkage and candidate gene studies have indicated some other candidate genes and loci to be involved in the skeletal Class III malocclusion etiology. It is possible that other genes play a role in other facial linear measurements, such as N-S, A'-PTM', Gn-Go, and Pog'-Go. Additionally, is possible that epistasis is involved, in which the effect of one gene is influenced by one or more modifier genes.

Another important factor that should be highlighted is the multifactorial nature of skeletal Class III malocclusion. Bone development and oral muscles are involved in the development and establishment of the skeletal malocclusion.[27] GH stimulates periosteal apposition within the action of osteoblasts[28] and indirectly through muscle forces that acts on bones, which is regulated by anabolic effects of GH on muscle tissue.[29] Skeletal muscle cells respond rapidly to GH increasing tyrosine phosphorylation of the GHR.[29] This may indicate that the polymorphism P561T in *GHR* may be involved in the mandibular ramal height through bone or muscle function.

One important factor to be taken into consideration in epidemiological genetic studies is the population's ethnic background. The frequency of skeletal Class III malocclusion ranges among worldwide populations, in which the lowest frequencies is in European American populations (0.48 to 4%), moderate frequencies in Sub-Saharan African populations (3 to 8%), and higher frequencies in far-eastern

Asian populations such as Korean, Chinese, and Japanese populations (15 to 23%).[15] In addition, the minor allele frequency of the studied polymorphism varies according to the population (NCBI). It is important to emphasize that the three studies included in the meta-analysis were performed on Asian populations.

Although the included studies were performed on different Asian populations, the heterogeneity of the included studies in the meta-analysis was 0%. In addition, only 2 studies included in the systematic review, that were performed on a Chinese and North American populations, did not find or suggest an association between mandibular ramal height growth and the polymorphisms P561T in *GHR*.[19,12]

It is possible that the differences observed were due to population differences or methodological differences among the studies. None of the included studies performed a sample size calculation[7,9–12,19,20] Two studies did not report if the polymorphism was in Hardy-Weinberg equilibrium.[9,20] The Hardy-Weinberg equilibrium is a principle stating that the polymorphism in a population will remain constant from one generation to the next in the absence of disturbing factors. Studies without Hardy-Weinberg equilibrium could reflect some methodological error in the sample selection or during the genotyping experiment.

Future research in different populations should be performed in order to evaluate if the polymorphisms P561T in *GHR* is associated with the mandibular ramal height in different ethnic backgrounds. This polymorphism may be a genetic marker for mandibular ramal height growth and might impact the orthodontic practice in the near future.

# CONCLUSION

Our systematic review and meta-analysis provide further evidence of the association between the polymorphism P561T in *GHR* and the Co-Go measurement, which allows to conclude, with low certainty of evidence, the relation of this SNP with Class III malocclusion Asian patients.

## ACKNOWLEDGEMENTS

Authors thanks to the Brazilian Ministery of Health's Federal Agency for Support and Evaluation of Pos-graduate Education (CAPES) for the scholarship, to São Paulo State Research Foundation (FAPESP) for the financial support.

# REFERENCES

1. Moreno Uribe LM, Miller SF. Genetics of the dentofacial variation in human malocclusion. Orthod Craniofac Res 2015;18:91–99.
2. Sundareswaran S, Ramakrishnan R. The Facial Aesthetic index: An additional tool for assessing treatment need. J Orthod Sci 2016;5:57–63.
3. Hilasaca-Mamani M, Barbosa T de S, Fegadolli C, Castelo PM. Validity and reliability of the quality of masticatory function questionnaire applied in Brazilian adolescents. CoDAS: SciELO Brasil 2016;28:149–154.
4. Lexomboon D, Carlson C, Andersson R, Bultzingslowen I, Mensah T. Incidence and causes of dental trauma in children living in the county of Värmland, Sweden. Dent Traumatol 2016;32:58–64.
5. Souza JGS, Martins AMEDB, Silveira MF, Jones KM, Meirelles MPMR. Impact of oral clinical problems on oral health-related quality of life in brazilian children: a hierarchical approach. Int J Paediatr Dent 2017;27:66–78.
6. Xue F, Rabie ABM, Luo G. Analysis of the association of COL2A1 and IGF-1 with mandibular prognathism in a Chinese population. Orthod Craniofac Res 2014;17:144–149.
7. Bayram S, Basciftci FA, Kurar E. Relationship between P561T and C422F polymorphisms in growth hormone receptor gene and mandibular prognathism. Angle Orthod 2014;84:803–809.
8. da Fontoura CSG, Miller SF, Wehby GL, Amendt BA, Holton NE, Southard TE, et al. Candidate gene analyses of skeletal variation in malocclusion. J Dent Res 2015;94:913–920.
9. Yamaguchi T, Maki K, Shibasaki Y. Growth hormone receptor gene variant and mandibular height in the normal Japanese population. Am J Orthod Dentofacial Orthop 2001;119:650–653.
10. Kang EH, Yamaguchi T, Tajima A, Nakajima T, Tomoyasu Y, Watanabe M, et al. Association of the growth hormone receptor gene polymorphisms with mandibular height in a Korean population. Arch Oral Biol 2009;54:556-562.
11. Tomoyasu Y, Yamaguchi T, Tajima A, Nakajima T, Inoue I, Maki K. Further evidence for an association between mandibular height and the growth hormone receptor gene in a Japanese population. Am J Orthod Dentofacial Orthop 2009;136:536–541.
12. Tassopoulou-Fishell M, Deeley K, Harvey EM, Sciote J, Vieira AR. Genetic variation in myosin 1H contributes to mandibular prognathism. Am J Orthod Dentofacial Orthop 2012;141:51–59.
13. Guan X, Song Y, Ott J, Zhang Y, Li C, Xin T, et al. The ADAMTS1 gene is associated with familial mandibular prognathism. J Dent Res 2015;94:1196-1201.
14. Frazier-Bowers S, Rincon-Rodriguez R, Zhou J, Alexander K, Lange E. Evidence of linkage in a Hispanic cohort with a Class III dentofacial phenotype. J Dent Res 2009;88:56–60.
15. Cruz RM, Hartsfield Jr JK, Falcão-Alencar G, Koller DL, Pereira RW, Mah J, et al. Exclusion of Class III malocclusion candidate loci in Brazilian families. J Dent Res 2011;90:1202–1205.

16. Nikopensius T, Saag M, Jagomägi T, Annilo T, Kals M, Kivistik PA, et al. A missense mutation in DUSP6 is associated with Class III malocclusion. J Dent Res 2013;92:893–898.
17. Ikuno K, Kajii TS, Oka A, Inoko H, Ishikawa H, Iida J. Microsatellite genome-wide association study for mandibular prognathism. Am J Orthod Dentofacial Orthop 2014;145:757–762.
18. Perillo L, Monsurrò A, Bonci E, Torella A, Mutarelli M, Nigro V. Genetic association of ARHGAP21 gene variant with mandibular prognathism. J Dent Res 2015;94:569–576.
19. Zhou J, Lu Y, Gao XH, Chen YC, Lu JJ, Bai YX, et al. The growth hormone receptor gene is associated with mandibular height in a Chinese population. J Dent Res 2005;84:1052–1056.
20. Sasaki Y, Satoh K, Hayasaki H, Fukumoto S, Fujiwara T, Nonaka K. The P561T polymorphism of the growth hormone receptor gene has an inhibitory effect on mandibular growth in young children. Eur J Orthod 2009;31:536–541.
21. Leung DW, Spencer SA, Cachianes G, Hammonds RG, Collins C, Henzel WJ, et al. Growth hormone receptor and serum binding protein: purification, cloning and expression. Nature 1987;330:537–543.
22. Moher D, Shamseer L, Clarke M, Ghersi D, Liberati A, Petticrew M, et al. Preferred reporting items for systematic review and meta-analysis protocols (PRISMA-P) 2015 statement. Syst Rev 2015;4:1.
23. Clark MF, Baudouin SV. A systematic review of the quality of genetic association studies in human sepsis. Intensive Care Med 2006;32:1706-1712.
24. Higgins JP, Thompson SG, Deeks JJ, Altman DG. Measuring inconsistency in meta-analyses. BMJ 2003;327:557.
25. Guyatt G, Oxman AD, Akl EA et al. (2011) GRADE guidelines: 1. Introduction–"GRADE evidence profiles and summary of findings tables. J Clin Epidemiol"64:383–94.
26. Schünemann HJ, Oxman AD, Vist GE, Higgins JPT, Deeks JJ, Glasziou P, Guyatt GH (2008) Chapter 12: interpreting results and drawing conclusions. In: Higgins J, Green S (eds) Cochrane handbook for systematic reviews of interventions version 501. The Cochrane Collaboration
27. Saccomanno S, Antonini G, D'Alatri L, D'Angelantonio M, Fiorita A, Deli R. Causal relationship between malocclusion and oral muscles dysfunction: a model of approach. Eur J Paediatr Dent 2012;13:321-323.
28. Zhang CZ, Young WG, Li H, Clayden AM, Garcia-Aragon J, Waters MJ. Expression of growth hormone receptor by immunocytochemistry in rat molar root formation and alveolar bone remodeling. Calcif Tissue Int 1992;50:541-546.
29. Litsas G. Growth Hormone and Craniofacial Tissues. An update. Open Dent J 2015;9:1-8.

# PULPAL AND PERIAPICAL RESPONSE OF DOGS' TEETH AFTER PULPOTOMY AND USE OF ENAMEL MATRIX DERIVATIVE AS A CAPPING AGENT

Léa Assed Bezerra da **Silva**[1*], Lisa Danielly Curcino **Araujo**[1], Marcela Martín del Campo **Fierro**[1], Francisco Wanderley Garcia de **Paula-Silva**[1], Raquel Assed Bezerra da **Silva**[1], Paulo **Nelson Filho**[1], Alberto **Consolaro**[1], Mário Roberto **Leonardo**

[1]Department of Pediatric Clinic, School of Dentistry of Ribeirão Preto, University of São Paulo, Ribeirão Preto, SP, Brazil.

**Palavras-chave:** Pulpotomia. Esmalte Dentário. Hidróxido de Cálcio. Óxido de Zinco e Eugenol.

**RESUMO**

**Objetivo**: Avaliar a resposta pulpar e periapical de dentes de cães após pulpotomia e uso de Derivados de Matriz de Esmalte (EMD) como agente de capeamento. **Métodos**: A pulpotomia foi realizada em 40 dentes de 4 cães e o tecido pulpar remanescente foi recuperado com os seguintes materiais: Grupos I e IV: EMD (Emdogain®); Grupos II e V: hidróxido de cálcio; Grupos III e VI: cimento de óxido de zinco e eugenol. Após 7 dias (Grupos I, II e III) e 70 dias (Grupos IV, V e VI), os animais foram eutanásiados e os dentes foram removidos e processados para análise histológica; foram analisados pelo teste de Kruskal-Wallis, seguido pelo teste de Dunn ou Mann Whitney ($\alpha = 0,05$). **Resultados**: Período de 7 dias: no Grupo I, observou-se infiltrado inflamatório leve a moderado e intensa proliferação vascular, enquanto o Grupo II apresentou infiltrado inflamatório leve e tecido pulpar intacto ($p < 0,05$). O grupo III apresentou infiltrado inflamatório moderado a grave. Período de 70 dias: os grupos IV e VI mostraram, na formação da ponte de dentina, que o tecido pulpar remanescente apresentava áreas necróticas com células inflamatórias na região periapical, reabsorção óssea e de cemento ($p > 0,05$). No Grupo V, houve formação de ponte de dentina, ausência de inflamação e ausência de reabsorção tecidual mineralizada ($p < 0,05$). **Conclusão**: O EMD como material de cobertura após pulpotomia não mostrou resposta tecidual satisfatória ou capacidade de induzir deposição de tecido mineralizado na polpa dentária.

**Keywords:** Pulpotomy. Dental Enamel. Calcium Hydroxide. Zinc Oxide and Eugenol.

**ABSTRACT**

**Objective**: To evaluate the pulpal and periapical response of dogs' teeth after pulpotomy and use of Enamel Matrix Derivative (EMD) as capping agent.

**Methods:** Pulpotomy was performed in 40 teeth from 4 dogs and the remaining pulp tissue was recovered with the following materials: Groups I and IV: EMD (Emdogain®); Groups II and V: calcium hydroxide; Groups III and VI: zinc oxide and eugenol cement. After 7 days (Groups I, II, and III) and 70 days (Groups IV, V, and VI), the animals were euthanized and the teeth were removed and processed for histological analysis; were analyzed using Kruskal-Wallis test followed by Dunn test or Mann Whitney test ($\alpha$=0.05). **Results**: *7-day period:* in Group I, it was observed a mild to moderate inflammatory infiltrate and intense vascular proliferation while Group II presented a mild inflammatory infiltrate and an intact pulp tissue ($p < 0.05$). Group III presented a moderate to severe inflammatory infiltrate. *70-day period*: Groups IV and VI showed no dentin bridge formation, the remaining pulp tissue presented necrotic areas with inflammatory cells in the periapical region and bone and cementum resorption ($p > 0.05$). In Group V, there was dentin bridge formation, absence of inflammation and absence of mineralized tissue resorption ($p < 0.05$). **Conclusion**: EMD as a capping material after pulpotomy did not show either satisfactory tissue response or capacity of inducing deposition of mineralized tissue in dental pulp.

Submitted: April 29, 2019
Modification: August 25, 2019
Accepted: September 9, 2019

***Correspondence to:**
Léa Assed Bezerra da Silva
Address: Rua Hortêncio Mendonça Ribeiro, 414 – Alto da Boa Vista. Ribeirão Preto – SP – Brasil. Zip code:14025-590.
Telephone number: +55 (16) 3602-3984
E-mail: lea@forp.usp.br

# INTRODUCTION

The objective of pulpotomy is to induce a dentinogenic reparative response after amputation of inflamed dental pulp. Although calcium hydroxide and mineral trioxide aggregate are the materials of choice for this procedure, mostly because the ability to forms a dentine bridge completely, several bioactive agents have been developed for pulp capping, including enamel matrix derivative (EMD).[1,2] Some studies have suggested that EMD stimulates odontoblastic differentiation and subsequent collagen matrix mineralization[3,4] to achieve dentinogenesis.[5,6]

Emdogain® is a gel that consists of EMD in a vehicle of propylene glycol alginate (PGA), used to induce biological regeneration in cases of loss of insertion of the periodontal ligament via promoting proliferation, migration and differentiation of fibroblasts from the periodontal ligament (PDL).[7,8] This formulation contains an extract of enamel matrix proteins of low molecular weight, mainly amelogenin. Emdogain® is produced by heat of EMD and PGA to reduce the risk of microbial contamination.[9] Clinical evaluations have demonstrated that Emdogain® induces regeneration of cement, insertion of PDL fibers, and bone repair.[8,10-15]

Although Emdogain® have been evaluated regarding the capacity of induce dentin repair after direct pulp capping,[3-6;16,17] the results have been divergent.[18] Some authors described that EMD induces the deposition of a newly formed "dentin-like" tissue.[3,5,6,17] On the other hand, other authors demonstrated that the ability to form a structural barrier to protect the pulp is unlikely, since the EMD induces the formation of disorganized islets of mineralized tissue.[2,18,19,20]

Although the enamel matrix derivative (Emdogain®) has been widely evaluated for PDL regeneration, few studies have been aimed to evaluate the use of this material in the conservative therapy of pulp tissue. Therefore, the purpose of this study is to evaluate the pulpal and periapical response of dogs' teeth after pulpotomy and use of EMD as capping agent, comparing with others materials.

# MATERIAL AND METHODS

## Operative procedures

The experimental protocol was conducted in compliance with the specifications of the Animal Experimentation Ethics Committee of the University of São Paulo, Brazil (#2008.1.87.53.9) and according to International Organization for Standardization 7405:2008.[21]

The second, third and fourth mandibular premolars, and the second and third maxillary premolars of 4 twelve-month-old male and female dogs of undefined breed, coming from the same litter and weighing 15 kg were selected for this study. A total of 40 teeth (80 roots) were assigned to 6 groups as described in (Table 1).

The animals were anesthetized intravenously with Neozine (1 mg/kg body weight; Aventis Pharma Ltda, Souzano, Brazil). Supplementary anesthesia was provided when required. The animals were maintained with isotonic saline plus 2.5% glucose (Glicolabor Indústria Farmacêutica Ltda, Ribeirão Preto, Brazil). Periapical radiographs were taken prior to the operative procedures and 7 and 70 days post-operatively using a custom-made film-holding device for standardization of the radiographic technique in dogs.[22]

After placement of a rubber dam and disinfection with 3% hydrogen peroxide and 2% chlorhexidine digluconate, coronal access was performed using air / water cooled high-speed #1015 diamond burs (KG Sorensen Indústria e Comércio, São Paulo, Brazil). The burs were replaced every 4 cavity preparations to ensure cutting efficiency and avoid overheating. The pulp chamber was irrigated with sterile saline and the coronal pulp was amputated at the level of the root canal entrances using sharp curettes. Hemostasis was obtained by copious irrigation of the pulp chamber with saline.

All experimental groups were tested in the same animal and were performed in alternate quadrants in a change-over system distributed at random. The materials were prepared according to the manufactures' instructions.

***Table 1***: *Material used in this study, number of teeth per group and experimental periods.*

| Group | Material | Number of teeth / roots | Experimental period |
|---|---|---|---|
| I | EMD (Emdogain®) | 12 / 24 | 7 days |
| II | Calcium hydroxide (Negative control) | 4 / 8 | 7 days |
| III | Zinc oxide and eugenol (Positive control) | 4 / 8 | 7 days |
| IV | EMD (Emdogain®) | 12 / 24 | 70 days |
| V | Calcium hydroxide (Negative control) | 4 / 8 | 70 days |
| VI | Zinc oxide and eugenol (Positive control) | 4 / 8 | 70 days |

***Chart 1**: Results from histopathological analysis of dental pulp and periapical area, regarding presence of dentin barrier, inflammatory response, pulpal hemorrhage, focal osteodentinogenesis, pulpal necrosis, external root resorption and periodontal ligament thickness. Values are expressed in number of teeth.*

| Parameter | Score | 7 days | | | 70 days | | | *Comparison between periods* | |
|---|---|---|---|---|---|---|---|---|---|
| | | Emdogain® (n=12) | Calcium Hydroxide (n=4) | Zinc Oxide and Eugenol (n=4) | Emdogain® (n=12) | Calcium Hydroxide (n=3)[&] | Zinc Oxide and Eugenol (n=3)[&] | | |
| Dentin barrier thickness | 0 (None) | 10 | 4 | 4 | -[#] | 0 | 2 | EMD | -[#] |
| | 1 (Thin) | 0 | 0 | 0 | -[#] | 1 | 1 | CH | $p = 0.0357$* |
| | 2 (Medium) | 0 | 0 | 0 | -[#] | 1 | 0 | ZOE | $p = 0.0384$* |
| | 3 (Thick) | 0 | 0 | 0 | -[#] | 1 | 0 | | |
| | Not evaluated[$] | 2 | 0 | 0 | 0 | 0 | 0 | | |
| *Comparison among groups* | | $p > 0.05$ | | | $p = 0.0975$ | | | | |
| Inflammatory response | 0 (None) | 2 | 3 | 0 | -[#] | 1 | 0 | EMD | -[#] |
| | 1 (Mild) | 6 | 1 | 1 | -[#] | 2 | 3 | CH | $p = 0.1535$ |
| | 2 (Moderate) | 4 | 0 | 1 | -[#] | 0 | 0 | ZOE | $p = 0.0111$* |
| | 3 (Severe) | 0 | 0 | 2 | -[#] | 0 | 0 | | |
| | Not evaluated[$] | 0 | 0 | 0 | 0 | 0 | 0 | | |
| *Comparison among groups* | | $p = 0{,}0002$* EMD × CH = $p < 0.05$*; EMD × ZOE = $p > 0.05$; CH × ZOE = $p < 0.05$* | | | $p = 0.1740$ | | | | |
| Hemorrhage | 0 (Absent) | 0 | 4 | 4 | -[#] | 3 | 3 | EMD | -[#] |
| | 1 (Present) | 12 | 0 | 0 | -[#] | 0 | 0 | CH | $p > 0.05$ |
| *Comparison among groups* | | $p < 0.0001$* EMD × CH = $p < 0.05$*; EMD × ZOE = $p < 0.05$*; CH × ZOE = $p > 0.05$ | | | $p > 0.05$ | | | ZOE | $p > 0.05$ |
| Focal osteodentinogenesis | 0 (Absent) | 4 | 4 | 4 | -[#] | 3 | 3 | EMD | -[#] |
| | 1 (Present) | 6 | 0 | 0 | -[#] | 0 | 0 | CH | $p > 0.05$ |
| | Not evaluated[$] | 2 | 0 | 0 | 0 | 0 | 0 | ZOE | $p > 0.05$ |
| *Comparison among groups* | | $p < 0.0001$* EMD × CH = $p < 0.05$*; EMD × ZOE = $p < 0.05$*; CH × ZOE = $p > 0.05$ | | | $p > 0.05$ | | | | |
| Pulpal necrosis | 0 (Absent) | 12 | 4 | 4 | 0 | 3 | 3 | EMD | $p < 0.001$* |
| | 1 (Present) | 0 | 0 | 0 | 12 | 0 | 0 | CH | $p > 0.05$ |
| *Comparison among groups* | | $p > 0.05$ | | | $p < 0.0001$* EMD × CH = $p < 0.05$*; EMD × ZOE = $p < 0.05$*; CH × ZOE = $p > 0.05$ | | | ZOE | $p > 0.05$ |
| External root resorption | 0 (Absent) | 12 | 4 | 4 | 1 | 3 | 1 | EMD | $p < 0.0001$* |
| | 1 (Present) | 0 | 0 | 0 | 11 | 0 | 2 | CH | $p > 0.05$ |
| *Comparison among groups* | | $p > 0.05$ | | | $p = 0.0004$ EMD × CH = $p < 0.05$*; EMD × ZOE = $p > 0.05$; CH × ZOE = $p < 0.05$* | | | ZOE | $p < 0.0025$* |
| Periodontal ligament thickness | 0 (None) | 12 | 4 | 4 | 0 | 2 | 0 | EMD | $p < 0.001$* |
| | 1 (Mild) | 0 | 0 | 0 | 2 | 1 | 1 | CH | $p > 0.3123$ |
| | 2 (Moderate) | 0 | 0 | 0 | 7 | 0 | 2 | ZOE | $p < 0.006$* |
| | 3 (Severe) | 0 | 0 | 0 | 3 | 0 | 0 | | |
| | Not evaluated[$] | 0 | 0 | 0 | 0 | 0 | 0 | | |
| *Comparison among groups* | | $p > 0.05$ | | | $p = 0.0007$ EMD × CH = $p < 0.05$*; EMD × ZOE = $p > 0.05$; CH × ZOE = $p < 0.05$* | | | | |

*Note: [&] tooth lost during histological preparation; [$] tooth not evaluated due to incorrect histological sectioning; -[#] pulpal necrosis; parameter could not be evaluated; *statistically significant; EMD (enamel matrix derivative, CH (calcium hydroxide), ZOE (zinc oxide and eugenol cement).*

The following materials were used as capping agents: Groups I and IV: Enamel matrix derivative (Emdogain® - Biore AB - Malmö - Sweden), available in the form of a gel containing 30 mg / ml EMD in PGA recovered with gutta-percha; Groups II and V: 0.5 g calcium hydroxide p.a. (Calcium Hydroxide zur Analyse; Merck, Darmstadt, Germany) mixed with 0.5 mL saline recovered with a calcium hydroxide cement layer (Dycal®; Dentsply Indústria e Comércio Ltda;Brazil); Groups III and VI: zinc oxide and eugenol cement (IRM®; Dentsply Indústria e Comércio Ltda,Brazil;1 scoop of powder zinc oxide mixed with 1 drop of eugenol). In all groups the access cavity was restored with amalgam (Velvalloy; SS White Dental Articles Ltda, Rio de Janeiro, Brazil).

The dogs were euthanized by anesthetic overdose 7 days (Groups I, II, and III) and 70 days (Groups IV, V, and VI) after pulpotomy. The maxillas and mandibles were removed and the anatomic pieces containing the teeth were sectioned using water-cooled diamond disks.

## Histological processing

The pieces were fixed in buffered 10% formalin for 72 hours at room temperature and demineralized in an etilenediaminetetracetic acid (EDTA)-based solution activated in a microwave oven (Sharp Carousel; São Paulo, SP, Brazil). After demineralization, the pieces were neutralized in 5% sodium sulfate (JT Baker, Xalostoc, Mexico), washed in running water for 24 hours, dehydrated in ascending ethanol grades, cleared in xylol and embedded in paraffin, according to the standard processing.

The blocks were serially sectioned and 5-µm-thick longitudinal cuts were obtained and stained with hematoxylin and eosin (HE), Mallory's Trichrome and Brown & Brenn staining technique for histological analysis under optical microscopy by one blind examiner. Slides were analyzed subjectively and semi-quantification evaluation was performed according to presence of dentin barrier, inflammatory response, pulpal hemorrhage, focal osteodentinogenesis, pulpal necrosis, external root resorption and periodontal ligament thickness. Scores were attributed to each parameter, according to our research group previously (Chart 1), and data were analyzed by means of Kruskal-Wallis and Dunn's post test or Mann-Whitney test ($\alpha$=0.05), using Graph Pad Prism 5.0 Software (San Diego, EUA).[23,24,25]

# RESULTS

## Group I (7 days) - Emdogain®

At the interface with the material, the pulp tissue presented a mixed inflammatory infiltrate composed of polymorphonuclear neutrophils and mononuclear inflammatory cells. Inside some cells, granules of a dark material were found, indicating that macrophages migrated to the pulp tissue to phagocyte the material. No signal of dentinogenesis and dentine barrier were found, even in the lateral walls in the middle third of the root canal pulp tissue, away from the cut surface. In some specimens, foci of osteodentin, characterized by bone matrix permeated by osteoblast-like cells, were irregularly distributed, creating an area similar to a primary immature bone. In the middle third of the root pulp tissue, it was observed an intense hemorrhage with exuberant erythrocytes irregularly and diffusely distributed throughout extracellular spaces. Close to the apex, the cementum surface was regular presenting cementoblasts throughout its extension in addition to fibers and absence of resorption areas (Figure 1).

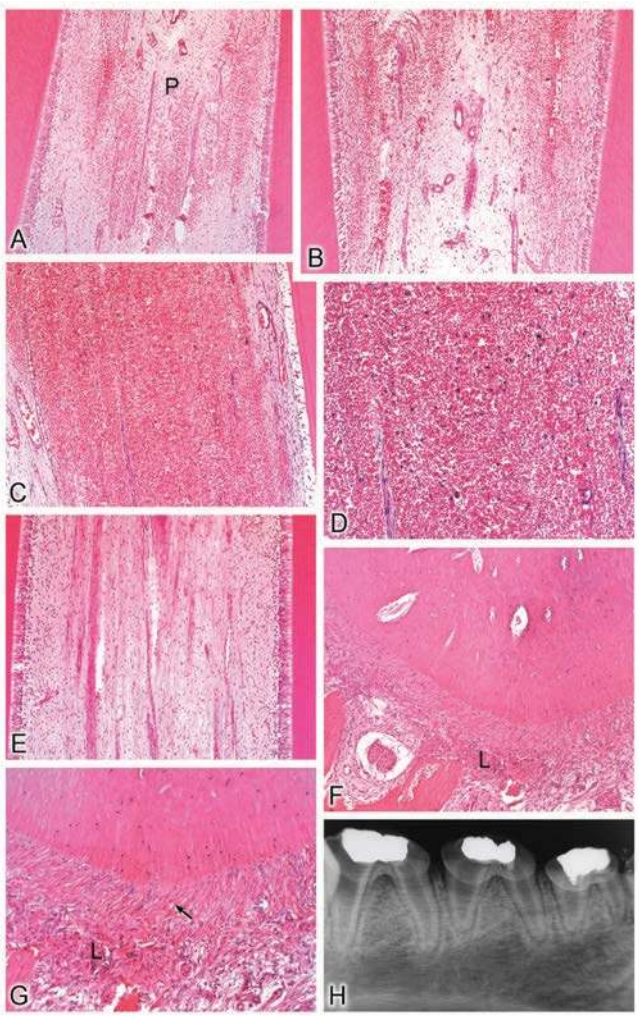


***Figure 1**: Emdogain® (7 days). (A, B) Cervical and medium third of the root canal demonstrating hemorrhagic dental pulp tissue (20×). (C, D) Higher magnification of A and B (40 and 60×). (E) Apical third demonstrating intact odontoblastic layer and periapical area (20×). (F, G) Normal periodontal ligament: absence of inflammatory cells and intense presence of fibers (20 and 40×) (L- periodontal ligament; P- pulp; Arrow (Sharpey fiber).(H) Conventional periapical radiographic showing intact lamina dura and bone tissue.*

## Group II (7 days) – Calcium hydroxide

At the interface of the material with the pulp tissue it was observed a zone of coagulative necrosis. The pulp tissue presented an infiltration of neutrophils and mononuclear leukocytes in some specimens. In others, the pulp tissue presented a new odontoblastic layer, with odontoblastic cells aligned with dentin walls, although no dentin barrier formation had been observed. Pulp tissue adjacent to the material presented a slight mononuclear inflammatory infiltrate and a slightly increased number of vessels. In some areas a new advanced organization of odontoblastic layer was found. The periodontal ligament was intact. There were no areas of alveolar bone resorption and a large number of osteoblasts were observed.

## Group III (7 days) – Zinc oxide and eugenol cement

Pulp tissue close to the material presented a concentrated mononuclear inflammatory cell infiltrate with few areas of edema. Root canal pulp tissue presented congested vessels and accentuated vessel proliferation and no dentin barrier formation. At the root apex, the apical delta canals were widened and filled with intact connective tissue. There were no resorption areas on the cementum surface. Periodontal ligament showed a large number of collagen fibers and intense angioblastic proliferation.

## Group IV (70 days) - Emdogain®

In this period, all specimens showed necrosis of the pulp tissue and apical periodontitis. No dentin bridge was observed in any specimen of this group and odontoblastic layer was absent along dentin walls. Cementum surface was irregular due to resorption areas, with resorption lacunae containing or not clastic cells. In the periodontal ligament, inflammatory cells of mononuclear and polymorphonuclear type were more concentrated close to the apex, forming one or more foci. Generalized edema and scarce presence of cells was observed. Alveolar bone resorption areas determined an increase in apical periodontal ligament thickness (Figure 2).

## Group V (70 days) – Calcium hydroxide

The pulp at the interface with the material presented normal characteristics, with an organized and mature odontoblastic layer and production of reparative dentin, well organized in its deeper layers. In the superficial layers of the dentin barrier, there was some cellular inclusions and

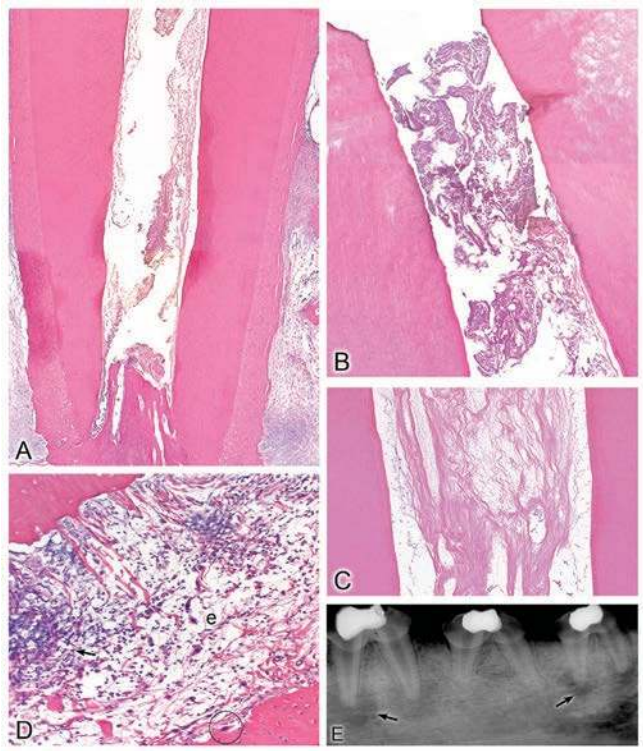


***Figure 2**: Emdogain® (70 days). (A, B) Dental pulp tissue with necrosis and no dentin bridge formation (20 and 40×). (C) Medium third of the root canal demonstrating tissue necrosis (20×). (D) Apical and periapical areas showing a widened periodontal ligament with inflammatory cells, generalized edema and fibrous dissociation. Bone and cementum present areas of resorption with clastic cells (circle) (60×). (E) Conventional periapical radiograph showing disruption of lamina dura and presence of radioluscent areas indicating apical periodontitis.*

invagination of pulp tissue. At the apical and periapical regions, cementum was regular; periodontal ligament showed a dense connective tissue, no inflammatory cells and intense presence of collagen fibers. The alveolar bone showed high presence of osteoblasts aligned on its surface.

## Group VI (70 days) – Zinc oxide and eugenol cement

In this group, formation of mineralized tissue bridge was not observed in any specimen. The pulp tissue was inflamed with moderate number of mononuclear inflammatory cells in all roots. Areas of fibers dissociation were frequently observed along the extension of the root pulp tissue, concomitantly with edema and areas of necrosis. Apical cementum surface presented non-repaired resorption areas. The apical foramina were widened and contained inflamed tissue remnants. The periodontal ligament thickness was increased with presence of moderate inflammatory infiltrate and generalized edema. Alveolar bone was resorbed and non-repaired.

## DISCUSSION

Our results, comparing the effects of enamel matrix derivative and calcium hydroxide on the pulp tissue in pulpotomy are similar to those reported by Olsson et al.[17] and Darwish et al. [19] and divergent to results found by Nakamura et al. [6]

At 7 days, there was no sign of dentinogenesis in teeth treated with Emdogain®, although foci of osteodentin, characterized by bone matrix permeated by osteoblast-like cells, was irregularly distributed creating an area similar to primary immature bone. Likewise, in enamel matrix derivative-treated teeth it has been reported that mineralized tissue forms as isolated masses inside the dental pulp. [2, 20] These authors reported that islands of hard tissue that formed in response to enamel matrix derivative, at 12 weeks after pulpotomy is unlikely to provide a structural barrier to protect the pulp as those bridge-like structures formed in calcium hydroxide-treated teeth. This difference may in part be due to the vehicle (PGA) used, since this material is a gel and does not leave a solid coating over the amputated dental pulp as would be done by calcium hydroxide.

However, we observed severe hemorrhage in the pulp tissue in contact with Emdogain® within 7 days following pulpotomy. Possible reason for that is the consistency of the gel, which facilitates its diffusion into the extracellular matrix, causing bleeding in the pulp tissue by diapedesis. Also, it has been speculated that PGA as vehicle may not be appropriate for pulp capping procedure due to it physical nature. [17] Total lack of pulpal healing could be seen at 70 days, when we observed the necrotic pulp tissue and apical periodontitis in all specimens. Although EMD induced early dentin bridge formation, pulpal inflammation followed by tissue necrosis were observed later on (at 3 months).[19]

On the other hand, in all specimens of the calcium hydroxide groups (II and V), there was mild inflammatory infiltrate in the pulp tissue in the 7-day experimental period and formation of dentin bridge obliterating the pulp exposure in the 70-day period, as previously demonstrated.[19,26-32] These findings are consistent with those of previous studies that used calcium hydroxide as a capping material after pulpotomy and also had results within the standard of normality. [26-32]

Overall, the unsatisfactory results obtained with zinc oxide and eugenol in our study are in agreement with the literature, [19, 30-32] as was demonstrated by the absence of dentin bridge formation in most specimens, the moderate inflammatory infiltrate in the pulp tissue, the periodontal ligament thickness moderately increased, and the resorption of cementum and bone.

Our results show that enamel matrix derivative in PGA vehicle (Emdogain®) did not show either satisfactory apical and periapical response or capacity of inducing mineralized tissue deposition when used to recover the root canal pulp remnant after pulpotomy.

### Acknowledgments

The authors knowledge the Fundação de Amparo à Pesquisa do Estado de São Paulo for Financial Support (2007/08284-7) .The authors deny any conflicts of interest.

## REFERENCES

1.Kaida H, Hamachi T, Anan H, Maedak K. Wound healing process of injured pulp tissues with Emdogain gel. J Endod 2008;34(1):26-30.
2.Fransson H, Petersson K, Davies JR. Dentine sialoprotein and collagen I expression after experimental pulp capping in humans using Emdogain gel. Int Endod J 2010 (In Press).
3.Ishizaki NT, Matsumoto K, Kimura Y, Wang X, Yamashita A. Histopathological study of dental pulp tissue capped with enamel matrix derivative. J Endod 2003;29(3):176-9.
4.Nakamura Y, Slaby I, Matsumoto K, Ritchie HH, Lyngstadaas SP. Immunohistochemical characterization of rapid dentin formation induced by enamel matrix derivative. Calcif Tissue Int 2004;75:243-52.
5.Nakamura Y, Hammarström L, Lundberg E, Ekdahl H, Matsumoto K, Gestrelius S, Lyngstadaas SP. Enamel matrix derivative promotes reparative processes in the dental pulp. Adv Dent Res 2001;15:105-7.
6.Nakamura Y, Hammarström L, Matsumoto K, Lyngstadaas SP. The induction of reparative dentine by enamel proteins. Int Endod J 2002;35(5):407-17.
7.Heijl L, Heden G, Svärdström G, Ostgren A. Enamel matrix derivative (Emdogain) in the treatment of intrabony periodontal defects. J Clin Periodontol 1997;24:705-14.
8.Rasperini G, Ricci G, Silvestri M. Surgical technique for treatment of infrabony defects with enamel matrix derivative (Emdogain): 3 case reports. Int J Periodontics Restorative Dent 1999;19(6):578-87.
9.Nagano T, Iwata T, Ogata Y, Tanabe T, Gomi K, Fukae M, Arai T, Oida S. Effect of heat treatment on bioactivities of enamel matrix derivatives in human periodontal ligament (HPDL) cells. J Periodontal Res 2004;39(4):249-56.
10.Hammarström L. Enamel matrix, cementum development and regeneration. J Clin Periodontol 1997;24:658-68.
11.Mellonig JT. Enamel matrix derivative for periodontal reconstructive surgery: technique and clinical and histologic case report. Int J Periodontics Restorative Dent 1999;19(1):8-19.
12.Aimetti M, Romano F, Pigella E, Piemontese M. Clinical evaluation of the effectiveness of enamel matrix proteins

and autologous bone graft in the treatment of mandibular Class II furcation defects: a series of 11 patients. Int J Periodontics Restorative Dent 2007;27(5):441-7.

13.Saito A, Hayakawa H, Ota K, Fujinami K, Nikaido M, Makiishi T. Treatment of periodontal defects with enamel matrix derivate: clinical evaluation at early healing stages. Bull Tokyo Dent Coll 2010;51(2):85-93.

14.Sculean A, Schwarz F, Becker J, Brecx M. The application of an enamel matrix protein derivative (Emdogain) in regenerative periodontal therapy: a review. Med Princ Pract 2007;16(3):167-80.

15.Sculean A, Schwarz F, Chiantella GC, Arweiler NB, Becker J. Nine-year results following treatment of intrabony periodontal defects with an enamel matrix derivative: report of 26 cases. Int J Periodontics Restorative Dent 2007;27(3):221-9.

16.Igarashi R, Sahara T, Shimizu-Ishiura M, Sasaki T. Porcine enamel matrix derivative enhances the formation of reparative dentine and dentine bridges during wound healing of amputated rat molars. J Electron Microsc (Tokyo) 2003;52(2):227-36.

17.Olsson H, Davies JR, Holst KE, Schröder U, Petersson K. Dental pulp capping: effect of Emdogain gel on experimentally exposed human pulps. Int Endod J 2005;38(3):186-94.

18.Wang HH, Sarmast ND, Shadmehr E, Angelov N, Shabahang S, Torabinejad M. Application of Enamel Matrix Derivative (Emdogain) in Endodontic Therapy: A Comprehensive Literature Review. J Endod. 2018;44(7):1066-79.

19.Darwish SS, Abd El Meguid SH, Wahba NA, Mohamed AA, Chrzanowski W, Abou Neel EA. Root maturation and dentin-pulp response to enamel matrix derivative in pulpotomized permanent teeth. J Tissue Eng. 2014; 5:2041731414521707.

20.Kiatwateeratana T, Kintarak S, Piwat S, Chankanka O, Kamaolmatyakul S, Thearmontree A. Partial pulpotomy on caries-free teeth using enamel matrix derivative or calcium hydroxide: a randomized controlled trial. Int Endod J 2009;42(7):584-92.

21.International Organization for Standardization (ISO). ISO 7405: Dentistry – Preclinical evaluation of biocompatibility of medical devices used in dentistry – Test methods for dental materials. Switzerland; 2008.

22.Cordeiro RCL, Leonardo MR, Silva LAB, Cerri PS. Desenvolvimento de um dispositivo para padronização de tomadas radiográficas em cães. RPG 1995;2:138-40.

23.Queiroz AM. Expressão de metaloproteinases da matriz e resposta tecidual frente a agentes cimentantes. Estudo no tecido conjuntivo subcutâneo de camundongos e no complexo dentino-pulpar de dentes de cães. Ribeirão Preto, 2011. 129 p. Tese de Livre-Docência: Faculdade de Odontologia de Ribeirão Preto/USP.

24.Queiroz AM, Assed S, Consolaro A, Nelson-Filho P, Leonardo MR, Silva RA, Silva LA. Subcutaneous connective tissue response to primary root canal filling materials. Braz Dent J 2011;22(3):203-11.

25.Silva LA, Azevedo LU, Consolaro A, Barnett F, Xu Y, Battaglino RA, Cañadas PS, de Oliveira KM, Silva RA. Novel endodontic sealers induce cell cytotoxicity and apoptosis in a dose-dependent behavior and favorable response in mice subcutaneous tissue. Clin Oral Investig 2017. In press.

26.Nosrat IV, Nosrat CA. Reparative hard tissue formation following calcium hydroxide application after partial pulpotomy in cariously exposed pulps of permanent teeth. Int Endod J 1998;31:221-6.

27.Silva LAB, de Paula e Silva FW, Leonardo MR, Assed S. Pulpal and periapical response of dogs' teeth after pulpotomy and use of recombinant human bone morphogenetic protein-7 as a capping agent. J Dent Child 2007;74(2):79-84.

28.Silva LAB, Leonardo MR, Nelson-Filho P, Medeiros AS, Rossi MA. Pulp response of anionic lyophilized collagen matrix with or without hydroxyapatite after pulpotomy in dog's teeth. Mat Res 2006;9(2):175-180.

29.Six N, Lasfargues JJ, Goldberg M. Differential repair responses in the coronal and radicular areas of the exposed rat molar pulp induced by recombinant human bone morphogenetic protein 7 (osteogenic protein 1). Arch Oral Biol 2002;47:177-87.

30.Fadavi S, Anderson AW. A comparison of the pulpal response to freeze-dried bone, calcium hydroxide, and zinc oxide-eugenol in primary teeth in two cynomolgus monkeys. Pediatr Dent 1996;18:52-6.

31.Holland R, Souza V, Mello W, Nery MJ, Bernabé PFE, Otoboni-Filho JA. The influence of the sealing material in the healing process of inflamed pulps capped with calcium hydroxide or zinc oxide-eugenol cement. Acta Odontol Pediatr 1981;2:5-9.

32.Watts A, Paterson RC. Pulpal response to a zinc oxide-eugenol cement. Int Endod J 1987;20:82-6.

# PARENTS AND CAREGIVERS' KNOWLEDGE AND ATTITUDES TOWARD CHILDREN'S TOOTHBRUSHING

Naiara Oliveira **Carvalho**[1], Hilda Lara Prado **Vasconcelos**[1], Cristiane Tomaz **Rocha**[1], Beatriz Gonçalves **Neves**[1*]

[1]School of Dentistry, Federal University of Ceará, Sobral, CE, Brazil

**Palavras-chave**: Criança. Cárie Dentária. Fluoretos. Cremes Dentais. Conhecimento. Pais.

**RESUMO**

**Introdução:** O flúor pode prevenir a cárie dentária, porém, especialmente em crianças menores, é importante equilibrar o efeito anticárie dos dentifrícios fluoretados versus o risco de fluorose dentária. **Objetivo:** O objetivo deste estudo foi analisar o conhecimento e atitudes de pais e cuidadores sobre os hábitos de escovação de seus filhos de 12 a 71 meses de idade, bem como verificar seu conhecimento sobre flúor e quantidade utilizada de creme dental. **Métodos:** Um roteiro de entrevista semi-estruturado foi aplicado a uma amostra de conveniência de pais e cuidadores (n=63) na Clínica de Odontopediatria de uma universidade pública. Solicitou-se que os entrevistados simulassem a quantidade de creme dental utilizada na escovação de seus filhos. Os resultados foram apresentados de forma descritiva com frequências absolutas e relativas. **Resultados:** Quanto à supervisão da escovação, 49,2% realizavam a higienização de seus filhos; 31,7% mencionaram que as próprias crianças escovavam sob supervisão de um adulto, e 19,1% responderam que seus filhos escovavam sozinhos. Quando perguntados como aprenderam a dispensar dentifrício na escova, 54% afirmaram que nunca foram orientados. Em 74,6% dos casos, a quantidade dispensada superou a dose recomendada para pré-escolares. Ademais, 57,1% relataram que o dentifrício fica ao alcance da criança. Dos entrevistados, 66,7% apontaram o papel do flúor na prevenção da cárie e 73% desconheciam sua toxicidade. **Conclusão:** Em geral, os entrevistados praticavam bons hábitos de escovação em seus filhos. Entretanto, a maioria da amostra estudada não utilizou a quantidade apropriada de dentifrício para a idade e desconhecia a toxicidade do flúor, apesar de identificar sua finalidade.

**Keywords**: Child. Dental Caries. Fluorides. Toothpastes. Knowledge. Parents.

**ABSTRACT**

**Introduction**: Fluoride prevents tooth decay, but especially in young children, it is important to balance the anticaries effect of fluoride toothpastes versus the risk of dental fluorosis. **Objective**: The aim of this study was to analyze parents' and caregivers' knowledge and attitudes toward their children's toothbrushing habits from 12 to 71 months of age, as well as to verify their knowledge about fluoride and toothpastes' dispensed amount. **Methods**: A semi-structured interview script was applied to a convenience sample of parents and caregivers (n = 63) at the Pediatric Dentistry Clinic of a public university. Respondents were asked to simulate the amount of toothpaste used in their children's brushing. Results were presented with absolute and relative frequencies. **Results**: Regarding their children's toothbrushing, 49.2% performed oral hygiene of their children; 31.7% mentioned that their children brushed under adult supervision; and 19.1% said their children brushed alone. When asked if they had already received guidance regarding the adequate amount of toothpaste to be dispensed, 54% stated they were never oriented. In 74.6% of cases, the amount dispensed exceeded the recommended dose for preschoolers. In addition, 57.1% reported that the toothpaste is within the reach of the child. Of the respondents, 66.7% pointed out the role of fluoride in caries prevention, and 73% were unaware of its toxicity. **Conclusion**: In general, parents had good oral hygiene practices with their children. However, most respondents did not use the appropriate amount of toothpaste for their children's age and were unaware of fluoride toxicity, although they could identify its purpose.

Submitted: March May 19, 2019
Modification: August 6, 2019
Accepted: August 13, 2019

***Correspondence to**:
Beatriz Gonçalves Neves
Address: Universidade Federal do Ceará, Campus Sobral.
Rua Conselheiro José Júlio, S/N. Centro, Sobral, Ceará- Brazil,
Zip code: 62010-820
Telephone number: +55 (88) 3695- 4611
E-mail: beatrizgneves@gmail.com

# INTRODUCTION

Dental caries is a biofilm-mediated, sugar-dependent disorder that results from dysbiosis of the oral microbiota and is driven by multiple factors, being characterized by the demineralization of dental hard tissues.[1] Frequent exposure to dietary carbohydrates can lead to the production of acids, driving a selection of acidogenic and acid-tolerant bacteria.[2] This disorder remains a significant oral public health problem in several countries[3] and is considered one of the most common chronic childhood diseases worldwide.[4]

Fluorides have been widely demonstrated in several delivery forms to control and prevent dental caries since the first half of the 20th century.[5] The presence of fluoride in the oral fluids has been demonstrated to interfere with the dynamics of the caries process by reducing enamel demineralization and increasing its remineralization.[5] In the presence of fluoride, early stages of the caries process can be reversed or arrested, and the progression of more advanced lesions can be slowed down.[1]

Among the individual methods of fluoride use, fluoridated toothpastes are the most rational means of fluoride source, since with this method, the fluoride is available in the oral environment at the same time that removal and disorganization of the dental biofilm occurs.[6] There is considerable evidence that fluoride dentifrices have successful effects on caries control,[7] as revealed by the overall global decline of caries worldwide over recent decades.[1]

Standard fluoridated toothpastes are effective in reducing dental caries in primary teeth of preschool children, and therefore, these products should be recommended for this age.[8] In Brazil, since 2009, fluoride dentifrice has been officially indicated soon after the eruption of the first tooth.[9]

For the management of early childhood caries, besides preventive measures such as mechanical biofilm removal and rationale sugar consumption, the use of fluoridated toothpaste in an amount no more than a "smear" or the size of a grain of rice for children under three years of age and no more than a "pea-sized" amount for children three to six years old twice daily should be recommended.[10] In addition, although fluoride products are effective for caries prevention and control, young children may involuntarily swallow a certain amount of fluoride while their permanent teeth are forming when brushing their teeth, thereby increasing the risk of dental fluorosis.[11] The most important risk factor for fluorosis is the total fluoride consumed from all sources during the critical period of dental development.[12]

Overall, the type, frequency and amount of toothpaste children use are based purely on parental preferences.[13] Some studies have investigated patterns of toothbrushing and toothpaste usage among children who were below six years of age and the level of parental knowledge about their children's oral health care,[14,15] as well as how parents perform oral hygiene practices.[16,17] However, there is limited literature about this topic. More researches are necessary to guide parents in relationship to children's brushing.

Especially during early childhood, it is extremely important to balance the anticaries effect of fluoride toothpastes and the risk of dental fluorosis.[18] In this context, the aim of this study was to analyze parents' and caregivers' knowledge and attitudes toward their children's toothbrushing habits from 12 to 71 months of age and to verify their knowledge about fluoride and the dispensed amount of toothpaste.

# MATERIALS AND METHODS

## Ethical Aspects

This study was approved by the Ethics Committee of School of Medicine, Federal University of Ceará (89138918.2.0000.5054) in compliance with Resolution 466/12 of the National Health Council.

## Study design

A quantitative, descriptive and cross-sectional study was conducted among parents and caregivers of preschool children by interviews based on a questionnaire.

## Selection of Sample

A convenience sample (n=63) was used for this study. Parents and caregivers who accompanied the treatment of children from 12 to 71 months of age in the Pediatric Dentistry Clinic of the Federal University of Ceará were invited to participate in this study. All participants signed the informed written consent.

Inclusion criteria were parents and caregivers who had at least 30 minutes to respond to the questionnaire and those who were able to understand the purposes, risks and benefits of this study. Only parents and caregivers who had children from 12 to 71 months were included in this study and also parents who had children with one or more teeth. Parents and caregivers who were unaware of the child's routine and were unable to answer the interview questions were excluded.

Data collection was performed at the Pediatric Dentistry Clinic of UFC-Campus Sobral from May 2018 to November 2018. The clinic offers dental care to children aged 0 to 12 years of Sobral and neighboring municipalities.

## Interview Process

The participants of this study were interviewed by two undergraduate students in their last year of study at the School of Dentistry in a reserved area of the Pediatric Dentistry Clinic. The students were previously trained. The data collection instrument was a semi-structured individual form containing questions regarding the knowledge of parents and caregivers about the use of dentifrices in children, as well as an evaluation of the amount of toothpaste used in their children's brushing.

For a proper information collection, a pre-test was carried out to verify whether participants understood the questions. The parents and caregivers interviewed (n=12) at this phase of the study were not included in the final sample.

Initially, a toothbrush and commercially available toothpaste (Colgate Tandy®, Colgate-Palmolive Industrial LTDA, São Bernardo do Campo, SP, Brazil) were given to parents and caregivers, who were asked to simulate the amount of toothpaste they usually dispensed during children's brushing. The dentifrice used was 1,100 ppm sodium fluoride, and the toothbrushes were small and commercially available for children (Oral B®, Gillette do Brasil Ltda., Manaus, AM, Brazil), according to the age range of the sample. After simulation of the amount of fluoride dentifrice used by parents/caregivers, a photograph of the toothbrush and the amount dispensed was taken. The amount of dentifrice dispensed was compared by the researcher with images of toothbrushes with different amounts of dentifrice. The image that most closely resembled the simulation of the amount of dentifrice dispensed by interviewee was recorded, based on a previous study.[14]

After the parents and caregivers put toothpaste on the toothbrushes, interviews based on a questionnaire were conducted with them that included a total of 22 open and closed questions that were structured into three parts: the first part containing specific data about the child and parents/caregivers such as age, gender, the city of the child's birth and socioeconomic data; the second part containing questions on the child's toothbrushing habits addressing the beginning of the child's oral hygiene, the child's access to toothpaste, toothbrush size, the child's brushing frequency, use of fluoride toothpaste, toothpaste flavor and composition; and the third part containing questions about knowledge about fluoride's role and its toxicity. This questionnaire was designed by the authors and based on previous studies.[14-17]

Then, the interviewees were informed about fluoride use and its applications in caries prevention. In addition, they were advised about toothpaste disposal recommendations according to the age range of the child and care they should take with fluoride toothpaste storage.

## Data Analysis

All answers of open questions were reorganized into categories of analysis. Data were entered into a spreadsheet (Microsoft Excel, Microsoft Corp, WA, USA) and then analyzed using SPSS Version 22.0 (IBM Corp., Armonk, NY, USA). Descriptive statistics was used to describe the study participants from their absolute and relative frequencies.

# RESULTS

The study included 63 parents and caregivers of preschool children who attended the Pediatric Dentistry Clinic of a public university. The average age of the interviewees ranged from 18 to 58 years, with a mean of 31.6 years (± 8.2 years). Table 1 shows the distribution of the sample with socioeconomic data of all respondents and of children's ages. Many participants (30.2%) had completed only high school education, whereas only 9.5% had college degrees or higher. The great majority (95.2%) presented a family income of up to 3 minimum wages.

When asked if they have received anticipatory guidance about children's oral health during pregnancy, most of the interviewees (57.1%, n=36) answered that they did not receive any information. In relation to when parents started brushing their child's teeth, 38.1% (n=24) of parents and caregivers mentioned that it started before the eruption of the teeth, 31.7% (n=20) said shortly after eruption of the first tooth and 30.2% (n=19) only started after eruption of several teeth. When asked if their child brushed their teeth before going to sleep, some parents (38.1%) reported brushing their children's teeth in the evening only few days a week, and 6.3% never brushed their child's teeth in the evening before going to bed (Table 2).

Most parents (49.2%) reported performing oral hygiene of their children, 31.7% of the participants mentioned that their child brushed on their own under an adult's supervision, followed by 19.1% (n=12) of the respondents who answered that their child brushed by themselves (Table 2). Sample distribution by children's age regarding who performed children's toothbrushing is described in more detail in Table 3. The great majority (77.8%) of the respondents mentioned that they placed the toothpaste on the child's toothbrush. This result was observed regardless of children's age (Table 4).

All participants answered that they use fluoride toothpaste in their children's brushing. The main brands of toothpaste used by children were *Colgate Tripla Ação*® (Colgate-Palmolive Industrial LTDA, São Bernardo do Campo, SP, Brazil) (28,6%, n=18), *Colgate Tandy*® (Colgate-Palmolive Industrial LTDA, São Bernardo do Campo, SP, Brazil) (25,4%, n=16) and *Sorriso* (Colgate-Palmolive Industrial LTDA, São

***Table 1***: *Distribution of sample according to socioeconomic data, Sobral, 2018.*

| Variable | N | % |
|---|---|---|
| Gender | | |
| Female | 59 | 93.7 |
| Male | 4 | 6.3 |
| **Family income** | | |
| Zero to three minimum wages | 60 | 95.2 |
| Three to five minimum wages | 1 | 1.6 |
| Five to ten minimum wages | 2 | 3.2 |
| **Level of education** | | |
| Incomplete middle education | 9 | 14.3 |
| Complete middle education | 6 | 9.5 |
| Incomplete high school | 17 | 27 |
| Complete high school | 19 | 30.2 |
| Incomplete higher education | 6 | 9.5 |
| Complete higher education | 5 | 7.9 |
| Complete postgraduate | 1 | 1.6 |
| **Respondents' age by age group** | | |
| 18 – 25 years | 17 | 27 |
| 26- 32 years | 19 | 30.2 |
| 33- 39 years | 16 | 25.4 |
| 40- 46 years | 8 | 12.7 |
| 47- 58 years | 3 | 4.8 |
| **Child's age by month** | | |
| 12 – 24 months | 5 | 7.9 |
| 25- 36 months | 6 | 9.5 |
| 37- 48 months | 16 | 25.4 |
| 49- 60 months | 16 | 25.4 |
| 61- 71 months | 20 | 31.7 |

***Table 2:*** *Child's tooth brushing habits performed by parents or caregivers, Sobral, 2018 (n=63).*

| Variables | N | % |
|---|---|---|
| **When started child's oral hygiene** | | |
| Before appearance (eruption) of the first tooth | 24 | 38.1 |
| Soon after appearance (eruption) of the first tooth | 20 | 31.7 |
| After appearance (eruption) of several teeth | 19 | 30.2 |
| **The child brushes their teeth before bed** | | |
| Always (every day) | 35 | 55.6 |
| Sometimes (in few days) | 24 | 38.1 |
| Never | 4 | 6.3 |
| **Who performs child's brushing** | | |
| Parents/caregivers | 31 | 49.2 |
| The child under an adult's supervision | 20 | 31.7 |
| The child brushes teeth alone | 12 | 19.1 |
| **Who places the toothpaste in the child's brush** | | |
| Parents/caregivers | 49 | 77.8 |
| The child under the supervision of a person | 7 | 11.1 |
| The child puts the toothpaste by herself | 7 | 11.1 |
| **Frequency of brushing per day** | | |
| Once | 6 | 9.5 |
| Twice | 27 | 42.9 |
| Three times or more during the day | 29 | 46.0 |
| Does not brush everyday | 1 | 1.6 |

Bernardo do Campo, SP, Brazil) (14,3%, n=9). The majority of parents and caregivers (57.1%, n=36) stated that dentifrice is within reach of the child. When asked if they had already received guidance about how to place the toothpaste on the toothbrush, 54% (n=34) parents or caregivers reported that they had never received this orientation (Table 5).

Among the interviewees, (74.6%, n=47) knew or had heard about fluoride. However, most participants (73%, n=46) are unaware of fluoride toxicity. According to the analysis of the photos about the amount of dentifrice dispensed by parents and caregivers, it was found that the great majority 74.6% (n=47) placed an amount of dentifrice of more than "pea-sized" (Table 6).

***Table 3***: *Sample distribution regarding who performed children's toothbrushing.*

| Age | Parents or caregivers | Children under adult supervision | Children by themselves |
|---|---|---|---|
| **12-24 months** | 5 (100%) | — | — |
| **25 -36 months** | 4 (66.6%) | 1 (16.6%) | 1 (16.6%) |
| **37-48 months** | 8 (50%) | 7 (43.8%) | 1 (6.25%) |
| **49-60 months** | 5 (31.2%) | 6 (37.5%) | 5 (31.2%) |
| **61-71 months** | 9 (45%) | 6 (30%) | 5 (25%) |
| **Total** | 31 (49.2%) | 20 (31.7%) | 12 (19.1%) |

***Table 4***: *Sample distribution regarding who places the toothpaste in the child's toothbrush.*

| Age | Parents or caregivers | Children under adult supervision | Children by themselves |
|---|---|---|---|
| **12-24 months** | 5 (100%) | — | — |
| **25 -36 months** | 6 (100%) | — | — |
| **37-48 months** | 11 (68.7%) | 4 (25%) | 1 (6.2%) |
| **49-60 months** | 13 (81.2%) | — | 3 (4.8%) |
| **61-71 months** | 14 (70%) | 3 (15%) | 3 (15%) |
| **Total** | 49 (77.8%) | 7 (11.1%) | 7 (11.1%) |

***Table 5:*** *Characteristics about the use of fluoride dentifrice in the interviewees' residence, Sobral, 2018 (n = 63).*

| Variables | N | % |
|---|---|---|
| **Size of toothbrush used by child** | | |
| Conventional / Adult Size | 5 | 7.9 |
| Child size | 58 | 92.1 |
| **The toothpaste has a pleasant taste** | | |
| Yes | 44 | 68.5 |
| No | 17 | 27 |
| No sure | 2 | 4.5 |
| **The toothpaste is within reach of the child** | | |
| Yes | 36 | 57.1 |
| No | 27 | 42.9 |
| **How did you learn the quantity of toothpaste to be placed on the child's toothbrush?** | | |
| Television / Advertising | 4 | 6.3 |
| Family or friends | 7 | 11.1 |
| Dentist | 18 | 28.6 |
| "Nobody taught, I believe it's that way" | 34 | 54.0 |

***Table 6:*** *Knowledge about fluoride and sample distribution according to comparison of pictures[14] with simulation of amount of dentifrice dispensed by interviewees, Sobral, 2018 (n = 63).*

| Variables | N | % |
|---|---|---|
| **Role of fluoride** | | |
| Teeth whitening | 7 | 11.1 |
| Avoid tooth decay | 42 | 66.7 |
| Do not know the usefulness of fluoride | 14 | 22.2 |
| **Knowledge about fluoride toxicity** | | |
| Yes | 46 | 73 |
| No | 17 | 27 |
| **Representative pictures for comparison** | | |
|  | 1 | 1.6 |
|  | 3 | 4.8 |
|  | 2 | 19 |
|  | 20 | 31.7 |
|  | 19 | 30.2 |
|  | 8 | 12.7 |

# DISCUSSION

An important factor for studying parents' and caregivers' knowledge, attitudes and actions regarding children's oral health habits is to improve our understanding of the influence of parents' decisions on oral preventive practices.

The socioeconomic profile of this study corresponded mostly to women, aged between 18 and 58 years, with family income of up to 3 minimum wages and incomplete/complete high school education. Studies point out that mothers are mainly responsible for bringing children for dental care and for oral hygiene of children,[16,19] corroborating with the fact that the university's dental clinic is usually attended by women of lower socioeconomic level who seek dental care for their children, nephews and nieces or grandchildren.

Regarding the initial period of toothbrushing with the fluoride dentifrice, approximately 70% of the parents reported that they began their child's toothbrushing before or shortly after the eruption of the first tooth, which is not in agreement with findings of other studies.[17,20] However, this result is in accordance with the actual recommendations that the child's oral hygiene should be started as soon as the child's first tooth erupts, around six or eight months of age.[6,21]

In this study, most interviewees mentioned that their children´s brushing is performed by an adult or by the child with an adult's help. According to the literature, parents should be instructed to perform child's brushing until the age of 3 years. From 3 to 6 years of age, children begin to have more ability, but the greater responsibility still lies with the parents. From the age of 6 years, oral hygiene can be performed by the child under parental supervision.[22,23]

It was also observed in this study that a large proportion of children's uses dentifrices with concentrations up to 1,450 ppm. Toothpastes containing NaF/$SiO_2$ (1,100 ppm F) are the most used by children of higher socioeconomic level, and those containing MFP/$CaCO_3$ (1,450 ppm F) are used by children of lower socioeconomic level because they are used by the whole family.[24] Most parents interviewed mentioned using fluoride

toothpastes for their child's toothbrushing routine, which was not expected because of the strong marketing of fluoride-free toothpaste to preschool children.[25] On the other hand, it has been reported that the use of dentifrices in high concentrations may increase the risk of dental fluorosis.[26] Moreover, there is no evidence to support the use of low-fluoride dentifrices for caries prevention in primary dentition in children younger than 7 years.[5] The current recommendation is that conventional fluoride dentifrices (1,000-1,500 ppm F) for prevention and control of dental caries should also be used in preschool children.[6]

In relation to access of toothpaste, 57.1% of children have access to dentifrice. It should be noted that children of the studied age range are at risk of high intake of dentifrice. In addition, studies indicate that children use more than the recommended dose of dentifrices when they are not supervised, especially if the dentifrice has a palatable taste.[15,20,23] However, according to a systematic review, there is evidence that flavored toothpaste does not increase fluoride intake in young children.[27] Parents should be aware that fluoride dentifrice is considered a medicine, a preventive and a therapeutic agent against caries and should not be available to the child.[6-7,21] It is worth noting that ingestion of a "pea-sized" amount or more of fluoride dentifrice can lead to risk of developing mild dental fluorosis.[28]

This study finds that 54% of the interviewees did not obtain any instruction regarding the use of dentifrice. They confirmed that they placed it in the way they believe to be correct. The amount of dentifrice that most parents interviewed use with their children exceeds the amount recommended for preschool children. However, an important limitation of this study is that it was not verified whether the parents/caregivers who place a large amount of toothpaste in their children's toothbrushes are those who did not receive guidance on the use of toothpaste in children. Lack of information is one of the main reasons for the risk of dental fluorosis. The most effective measure to minimize the risk of fluorosis may be reducing the amount of toothpaste placed on the toothbrush.[9,29]

Most parents/caregivers reported supervising the child's brushing and disposing of toothpaste on the toothbrush, but the findings indicate that they do not use the recommended dose according to the child's age, suggesting that their children are exposed to high intake of fluoride dentifrices, especially those who have easy access to the dentifrice in their homes. Many participants in this study pointed out that fluoride is important for its protective effect against dental caries. However, this subject was not asked as an open question, which may generate non-spontaneous responses, thus limiting the evaluation of this knowledge in relation to fluoride. In fact, interviewees seem to know the main benefit of fluoride to oral health, but fluoride toxicity is unknown to most of them, which can lead to cases of fluorosis or severe acute intoxication in young children.

Overall, the findings of this study point out that parents/caregivers should be better educated, since there is still lack of awareness of appropriate guidance for the selection and use of toothpastes in children. Additional researches are needed to identify the most effective way to instruct parents and caregivers about the amount of fluoride toothpaste used in young children to optimize caries control and safety.

In general, according to the responses from this sample, the parents seem to have good oral hygiene practices with their children. However, most respondents did not use the appropriate amount of toothpaste for their children's age, as shown by the placement of the toothpaste, and they were unaware of fluoride toxicity, despite identifying its purpose.

## REFERENCES

1. Pitts NB, Zero DT, Marsh PD, Ekstrand K, Weintraub JA, Ramos-Gomez F, et. al. Dental caries. Nat Rev Dis Primers. 2017 May 25;3:17030. doi: 10.1038/nrdp.2017.30.

2. Marsh PD. Ecological events in oral health and disease: new opportunities for prevention and disease control? J Calif Dent Assoc. 2017;45: 525–37.

3. Kassebaum NJ, Smith AGC, Bernabé E, Fleming TD, Reynolds AE, Vos T, Murray CJL, Marcenes W; GBD 2015 Oral Health Collaborators. Global, Regional, and National Prevalence, Incidence, and Disability-Adjusted Life Years for Oral Conditions for 195 Countries, 1990-2015: A Systematic Analysis for the Global Burden of Diseases, Injuries, and Risk Factors. J Dent Res. 2017 Apr;96(4):380-387. doi: 10.1177/0022034517693566.

4. Hajishengallis E, Parsaei Y, Klein MI, Koo H. Advances in the microbial etiology and pathogenesis of early childhood caries. Mol Oral Microbiol. 2017 Feb;32(1):24-34. doi: 10.1111/omi.12152. Epub 2016 Feb 4.

5. Buzalaf MAR. Review of Fluoride Intake and Appropriateness of Current Guidelines. Adv Dent Res. 2018 Mar;29(2):157-166. doi: 10.1177/0022034517750850.

6. Cury JA, Tenuta LMA. Evidence-based recommendation on toothpaste use. Braz Oral Res. 2014; 28 Spec No:1-7. doi: 10.1590/S1806-83242014.50000001.

7. Tenuta LM, Cury JA. Fluoride: its role in dentistry. Braz Oral Res. 2010;24 Suppl 1:9-17.

8. Santos AP, Oliveira BH, Nadanovsky P. Effects of low and standard fluoride toothpastes on caries and fluorosis: systematic review and meta-analysis. Caries Res. 2013;47(5):382-390. doi: 10.1159/000348492.

9. Brasil. Ministério da Saúde (MS). Secretaria de Atenção à Saúde. Departamento de Atenção Básica. Guia de Recomendações para uso de fluoretos no Brasil Brasília: MS; 2009.
10. American Academy of Pediatric Dentistry: Policy on Early Childhood Caries (ECC): classifications, consequences and preventive strategies. Reference Manual. Pediatric Dentistry 2016;38(6):52-54.
11. Cury JA, Tenuta LMA. Riscos do uso do dentifrício fluoretado na prevenção e controle de cárie na primeira infância. Rev Fac Odontol Porto Alegre 2012;53 (3): 21-27.
12. Buzalaf M, Levy SM. Fluoride intake of children: considerations for dental caries and dental fluorosis. Monogr Oral Sci. 2011;22:1-19. doi: 10.1159/000325101.
13. Bennadi D, Kshetrimayum N, Sibyl S, Reddy CV. Toothpaste Utilization Profiles among Preschool Children. J Clin Diagn Res. 2014 Mar;8(3):212-5. doi: 10.7860/JCDR/2014/7309.4165.
14. Bhuridej P, Levy SM, Warren JJ, Islam M, McGrady JA. Effects of toothbrush size and dentifrice type/brand on pea-sized and larger amounts of dentifrice. Int Dent J. 2007 Apr;57(2):71-6.
15. Creeth J, Bosma ML, Govier K. How much is a 'peasized amount'? A study of dentifrice dosing by parents in three countries. Int Dent J. 2013 Dec; 63 Suppl 2:25-30. doi: 10.1111/idj.12074.
16. Dabawala S, Suprabha BS, Shenoy R, Rao A, Shah N. Parenting style and oral health practices in early childhood caries: a case–control study. Int J Paediatr Dent. 2017 Mar;27(2):135-144. doi: 10.1111/ipd.12235.
17. Prietto NR, Portela AR, Almeida LH, Possebon APR, Azevedo MS, Torriani DD. Atitudes e conhecimento dos pais quanto ao uso de dentifrícios fluoretados em crianças de um a 65 meses de idade. RFO UPF. 2015;20(2):216-221.
18. Walsh T, Worthington HV, Glenny AM, Marinho VC, Jeroncic A. Fluoride toothpastes of different concentrations for preventing dental caries. Cochrane Database Syst Rev. 2019 Mar;4;3:CD007868. doi: 10.1002/14651858.CD007868.pub3.
19. Jacobsson B, Ho Thi T, Hoang Ngoc C, Hugoson A. Sociodemographic conditions, knowledge of dental diseases, dental care, and dietary habits. J Public Health Dent. 2015 Fall;75(4):308-16. doi: 10.1111/jphd.12101.
20. Jagher AC, Ripplinger T, Pinto GC, Lchardosim LR. Avaliação da utilização de dentifrício fluoretado em crianças. RFO UPF. 2016;21(1):38-42.
21. Oliveira BH, Santos APP, Nadanovsky P. Uso de dentifrícios fluoretados por pré-escolares: o que os pediatras precisam saber? Res Ped. 2012;2(2):12-9.
22. Polk DE, Geng M, Levy S, Koerber A, Flay BR. Frequency of daily tooth brushing: predictors of change in 9- to 11-year old US children. Community Dent Health. 2014 Sep;31(3):136-40.
23. Damião LS, Abrão LSO, Lopes PP, Castro AM, Oliveira FS. Uso de dentifrício fluoretado e hábitos de escovação em crianças de 6 a 36 meses de idade. Rev Odontol Bras Central 2010;19(51):295-300.
24. Martins CC, Oliveira MJ, Pordeus IA, Cury JA, Paiva SM. Association between socioeconomic factors and the choice of dentifrice and fluoride intake by children. Int J Environ Res Public Health 2011 Nov;8(11):4284-99. doi: 10.3390/ijerph8114284.
25. Martin M, Rosales G, Sandoval A, Lee H, Pugach O, Avenetti D, et. al. What really happens in the home: a comparison of parent-reported and observed tooth brushing behaviors for young children. BMC Oral Health. 2019 Feb 21;19(1):35. doi: 10.1186/s12903-019-0725-5.
26. Wong MC, Glenny AM, Tsang BW, Lo EC, Worthington HV, Marinho VC. Topical fluoride as a cause of dental fluorosis in children. Cochrane Databases System Rev. 2010 Jan 20;(1):CD007693. doi: 10.1002/14651858.CD007693.
27. Vieira TI, Mangabeira A, Alexandria AK, Ferreira DMTP, Fidalgo TKDS, Valença AMG, et. al. Does flavoured dentifrice increase fluoride intake compared with regular toothpaste in children? A systematic review and meta-analysis. Int J Paediatr Dent. 2018 May;28(3):279-290. doi: 10.1111/ipd.12354.
28. Wright JT, Hanson N, Ristic H, Whall CW, Estrich CG, Zentz RR. Fluoride toothpaste efficacy and safety in children younger than 6 years: a systematic review. J Am Dent Assoc. 2014 Feb;145(2):182-9. doi: 10.14219/jada.2013.37.
29. Daly JM, Levy SM, Xu Y, Jackson RD, Eckert GJ, Levy BT, et. al. Factors associated with parents' perceptions of their infants' oral health care. J Prim Care Community Health. 2016 Jul;7(3):180-187. doi: 10.1177/2150131916630524.

# MAXILLARY DENTAL MIDLINE DEVIATION IN THE PATIENT PERSPECTIVE

Thaís Magalhães **Galindo**[1], Licínio Esmeraldo da **Silva**[2], Andréa Fonseca Jardim da **Motta**[1], Adriana de Alcantara **Cury-Saramago**[1*]

[1]Department of Odontoclinic, Discipline of Orthodontics, School of Dentistry at Universidade Federal Fluminense, Niterói, RJ, Brasil.
[2]Department of Statistics, School of Mathematics at Universidade Federal Fluminense, Niterói, RJ, Brasil.

**Palavras-chave**: Estética Dental. Sorriso. Ortodontia.

**RESUMO**

**Objetivo**: O objetivo foi avaliar a percepção estética do desvio da linha média dentária por pacientes ortodônticos; influência de estruturas adjacentes ao sorriso na percepção de desvios; e diferença de percepção entre pacientes tratados em Universidade e consultório particular. **Métodos**: Neste estudo comparativo observacional transversal uma fotografia de mulher sorrindo foi modificada digitalmente com desvios da linha média para a esquerda em relação à face. Doze fotografias foram recortadas para obter o grupo LCN incluindo lábios, queixo e 2/3 nariz; e grupo L incluindo lábios. O teste não paramétrico de Friedman ($\alpha$= 0.05), seguido pelo de Wilcoxon, corrigido pelo teste de Bonferroni ($\alpha$ = 0.0033) foram utilizados para comparações múltiplas. O teste de Mann-Whitney foi aplicado para comparar grupos LCN e L, verificando a influência das estruturas adjacentes ao sorriso. O coeficiente de Pearson foi usado para correlação e regressão dos desvios sobre a estética do sorriso, adotando nível de significância de 5%.**Resultados**: Desvios de 2 mm foram identificados. Comparando grupos LCN e L houve diferença estatisticamente significante nos desvios de 2 e 3 mm. Entre pacientes da universidade e do consultório houve diferença significativa ao comparar fotografias no grupo LCN, sem desvio e desvios de 2, 4 e 5 mm. **Conclusões**: pacientes ortodônticos são capazes de detectar desvio da linha média dentária maxilar de 2 mm. Estruturas adjacentes ao sorriso influenciaram na percepção do desvio para os pacientes privados. Os pacientes da Universidade foram mais críticos do que os de consultório particular.

**Keywords:** Dental Esthetics. Smiling. Orthodontics.

**ABSTRACT**

**Objective:** This study aimed to determine aesthetic perceptions of midline deviations by orthodontic patients; influence of adjacent structures to smile in the perception of deviations; and difference between patients treated in University and in private practice. **Methods:** In this observational comparative cross-sectional study a smiling woman photograph was digitally modified, producing left maxillary dental midline deviations relative to facial midline. Twelve photographs were cropped in Group LCN including lips, chin and 2/3 of the nose; and group L including the lips. Non-parametric Friedman test ($\alpha$ = 0.05), followed by Wilcoxon test corrected by Bonferroni test ($\alpha$ = 0.0033) were used for multiple comparisons. Pearson correlation coefficient was used to study of the correlation and regression of the degree of smile esthetics on the midline deviations, adopting a significance level of 5%. **Results:** Patients were able to identify deviations from 2 mm. Among the groups of photos there was statistically significant difference in deviations of 2 and 3 mm. Comparing patients from University and private there was significant difference when comparing the photos in group LCN, without deviation and deviation of 2, 4 and 5 mm. **Conclusions:** Orthodontic patients are able to detect maxillary dental midline deviation from 2 mm. There was influence of viewing structures adjacent to smile in the perception of deviation for the private patients. University patients were more critical than private patients.

Submitted: February 22, 2019
Modification: June 26, 2019
Accepted: July 8, 2019

***Correspondence to:**
Adriana de Alcantara Cury-Saramago
Address: Rua Mário Santos Braga 30 – 2º andar, sala 214, Campus do Valonguinho, Centro, Niterói/Rio de Janeiro.
Zip code: 24020-140.
Telephone number:+55 (21) 2622-1621
E-mail: adrianacury@id.uff.br

## INTRODUCTION

The main individual motivation to seek orthodontic treatment is to improve smile esthetics, as currently, having good appearance is an important factor both in the professional and social field. Knowing this, orthodontists worldwide are increasingly committed to the expectations of their patients in relation to treatment.[1-3]

Scientific studies have shown reproducible and reliable methods to evaluate the smile esthetics ´, allowing the evaluation of aspects considered subjective. Such studies intend to get an understanding of the factors that improve or worsen the attractiveness of the smile, and try to create norms from scientific data to guide orthodontists regarding diagnosis and treatment plan.[4,5]

An esthetically pleasing smile includes factors like symmetry, proportion of tooth size, small gingival exposure when smiling, moderate buccal corridor, smiling curve following the curvature of the lower lip, proper vertical overlap and absence of diastemas.[1,6-10]

One feature that contributes to facial and smile symmetry is the dental midline. Although a subtle asymmetry between the facial and tooth midlines is acceptable, a significant discrepancy can be harmful.[11,12] Often orthodontists encounter malocclusions where there is discrepancy between dental and facial midlines, and its main causes are mandibular displacement caused by crossbite, asymmetric arches, discrepancy in the size of the teeth, displacement of the upper incisors and/or lower, isolated mandibular displacement or combination of these factors.[13-15]

In some cases, the correction of the discrepancy between the dental and facial midline is not simple and may increase the complexity and duration of treatment.[15] Therefore studies have been conducted in order to evaluate the perception of lay individuals,[1,4-6,12,14,15] dentists[4-6] and orthodontists[1,4,5,14,15] in relation to the influence of the deviation of the maxillary dental midline in smile esthetics, so that treatment planning reach the expectations of the patient,[1,2] avoiding unnecessary measures that prolong its completion. Threfore, not many studies assessed the perception of dental midline deviation by orthodontic patients. In the Beyer and Lindauer[4] study, patients and their parents participated as evaluators. They found statistically significant differences between orthodontists, dentists, patients and parents, with the orthodontists being the most critical ones and the patients the less critical.

For our study, we felt that it was consistent to consider the difference in perception between patients treated in the University and patients from a private practice.

The aim of this research was to evaluate the esthetic perception of the upper midline deviation by undergoing orthodontic treatment; the influence of structures adjacent to smile in the perception of deviation; and the difference of perception between patients treated at the Federal Fluminense University (UFF) and in private practice.

## MATERIALS AND METHODS

This comparative and observational cross-sectional research project was submitted to the Research Ethics Committee of the Faculty of Medicine of the Federal Fluminense University, Niterói, Rio de Janeiro, Brazil,[11] and was approved with the number 19883013.1.0000.5243, with the protocol number 422 820, and all participants signed a Consent and Informed form.

The digital photograph of a woman presenting well-aligned teeth was digitally modified with Adobe Photoshop Elements 2.0® software (Adobe Systems Inc., San Jose, California, USA) in order to produce progressive shifts of the maxillary dental midline in relation to facial midline 1 mm by 1 mm, from 0 to 5 mm. Adjacent tissue was kept in position once the entire upper arch was shifted to the left.[12]

To evaluate the influence of adjacent structures, the photos were cropped to obtain photographs in two configurations: Group LCN - including lips, chin and 2/3 of the nose; and Group L - including lips. We used [13] images for review, two of them without midline shift and [11] digitally altered. All photos were standardized reproducing the smile on the original patient ´s size.[12]

The 12 photographs (6 from group LCN and 6 from group L) were coded, printed and arranged randomly in an album to be submitted for review by the evaluators. The first part was assembled with the photographs from group LCN and the second part with the photographs from group L.[12]

The group of evaluators was composed by 104 lay in dentistry individuals that were in any fase of their orthodontic treatment in the clinic of post-graduation in orthodontics at UFF (n= 53), or in a private office (n= 51), including only adults (inclusion criteria). The mean age of the University sample was 23,18 years (18-44,7y) and for the private practice patients was a mean of 33,92 years (18-74,8y). The type of sample was based on cluster randomization where the evaluators were approached by the researcher when they got in the University or the private office for their appointment. They had complete freedom to choose whether to participate or not.

Before the evaluation of photographs was performed, two leveling photographs were showed to the evaluators: the original, without midline shift and another featuring 6 mm of deviation to the left side. It was delivered to the evaluator the album with the coded pictures and a form with 12 visual analogue scales (VAS),[16,17] a scale for each picture, numbered from zero to one hundred, the lowest

value assigned to the least esthetic smile and the greatest value to more esthetic. The time limit for the observation of each photograph was 20 seconds with an interval of 10 seconds between observation of a photograph and another. It was advised to the evaluator not to return to the previous album page. The same operator (T.M.G.) approached the patients, gave the instructions, handed the album and controlled the time of each evaluation.

After marking the values on their respective scales, measurements were performed by a single operator (T.M.G.), with the aid of a digital caliper (Starrett Indústria e Comércio Ltda., Itu, São Paulo, serial number 001296) calibrated to VAS, positioned in the point equal to zero and extended to the mark made by the evaluator. The values were recorded in tables so they could be analyzed statistically.

The sample size calculation was based on data from a doctoral thesis in Orthodontics, Dental School, Federal University of Rio de Janeiro.[11,12] For a 90% in power and 95% confidence interval ($\alpha = 0.05$) and considering difference of 10 in the VAS estimated sample size was 92 evaluators.

For evaluation of the method error, 20 examiners were randomly selected and requested to repeat the evaluation with three weeks apart. For the analysis of intra-examiner systematic error we used Student's t-test for paired samples and to determine the random error was used the calculation of the proposed error by Dahlberg.[18]

The minimum, the maximum, median and interquartile range were used where for achieving descriptive statistical data in all evaluations proposed.

The normality of the data relating to the esthetic evaluation of the midline changes, and the comparison between patients from UFF and private practice was evaluated by the statistical test of Kolmogorov-Smirnov.

To evaluate the influence of the change of the dental midline in the perception of smile esthetics, we used the non-parametric Friedman test, at a significance level of 5% ($\alpha = 0.05$), followed by the Wilcoxon test considering the significance level corrected by Bonferroni test ($\alpha = 0.0033$) for multiple comparisons.

It was adopted a 5% significance level for all tests described below.

Interference from adjacent structures to smile was evaluated using the non-parametric Friedman test , followed by the Wilcoxon test.[19]

The study of the correlation and regression of the degree of smile esthetics on the midline deviations was done using the Pearson correlation coefficient.

Statistical analysis was performed using the Statistical Package Computer program for Social Science © (SPSS Inc. Chicago, Illinois, USA), belonging to the Department of Statistics at the Mathematics Faculty of the Federal Fluminense University.

# RESULTS

The calculation result for intra-examiner error made by the Student test showed no statistically significant difference between the evaluations at a significance level of $p>0.05$, confirming the absence of systematic errors. According to the calculation results to random error assessment, acceptable values were obtained.

***Table 1***: *- The amount of manipulated shift, median and, interquartile range (iqr) of data assigned by the University patients evaluators (n= 53). Comparison of degrees of shift between photo LCN and photo L ($p < 0.05$).*

| | Deviation | median | iqr |
|---|---|---|---|
| **Group LCN** | No shift | 75.65 | 19.74 |
| | 1 mm | 81.28 | 19.51 |
| | 2 mm | 70.98 | 28.27 |
| | 3 mm | 66.78 | 24.06 |
| | 4 mm | 57.66 | 24.24 |
| | 5 mm | 50.40 | 24.05 |
| **Group L** | No shift | 79.74 | 21.43 |
| | 1 mm | 76.62 | 18.15 |
| | 2 mm | 73.17 | 28.07 |
| | 3 mm | 64.99 | 18.94 |
| | 4 mm | 63.49 | 26.71 |
| | 5 mm | 52.02 | 29.14 |
| | | **Mann-Whitney Test** | |
| | | | **p-value** |
| **LCN x L** | | No shift | 0.706 (ns) |
| | | 1 mm | 0.257 (ns) |
| | | 2 mm | 0.731 (ns) |
| | | 3 mm | 0.598 (ns) |
| | | 4 mm | 0.728 (ns) |
| | | 5 mm | 0.765 (ns) |

*Note: (ns) = no statistically significant difference*

Table 1 shows the central tendency and dispersion of the scores given by the evaluators from University. It can be seen that the highest grades were attributed to smiles without deviation and with 1 mm deviation, with the lowest scores awarded to the photos of smiles with 4 or 5 mm deviation, both in group LCN and group L. Mann-Whitney test was applied for comparisons between photos in group LCN and L, to verify the interference of adjacent structures to the smile. The results showed no statistically significant difference in valuation of University patients for both groups.

The Kolmogorov-Smirnov test was applied to verify the normality of the data and showed that they were not normal in some deviations in group LCN and in group L. The Wilcoxon test, at a significance level of 0.0033 after Bonferroni correction, indicates evidence of statistically significant difference between the deviation groups

***Table 2***: *- Application of the Wilcoxon test for multiple comparisons of the values assigned to each amount of shift of the groups LCN and L from University patients evaluators.*

| | Deviation | 1 mm | 2 mm | 3 mm | 4 mm | 5 mm |
|---|---|---|---|---|---|---|
| **Group LCN** | No shift | p = 0.501 | p <0.0001* | p <0.0001* | p <0.0001* | p <0.0001* |
| | 1 mm | | p <0.0001* | p <0.0001* | p <0.0001* | p <0.0001* |
| | 2 mm | | | p = 0.067 | p <0.0001* | p <0.0001* |
| | 3 mm | | | | p <0.0001* | p <0.0001* |
| | 4 mm | | | | | p <0.0001* |
| **Group L** | No shift | p = 0.789 | p = 0.014 | p = 0.0004* | p < 0.0001* | p < 0.0001* |
| | 1 mm | | p = 0.009 | p < 0.0001* | p < 0.0001* | p < 0.0001* |
| | 2 mm | | | p = 0.071 | p < 0.0001* | p < 0.0001* |
| | 3 mm | | | | p = 0.015 | p < 0.0001* |
| | 4 mm | | | | | p = 0.0004* |

*Note: * - Statistically significant (α = 0.05), adjusted by the Bonferroni test (α = 0.0033)*

***Table 3***: *- The amount of manipulated shift, median and interquartile range (iqr) of data private assigned by practice patients evaluators (n= 51). Comparison of degrees of shift between photo LCN and photo L (p < 0.05).*

| | Deviation | median | iqr |
|---|---|---|---|
| **Group LCN** | No shift | 84.17 | 20.16 |
| | 1 mm | 82.63 | 16.02 |
| | 2 mm | 80.61 | 13.64 |
| | 3 mm | 75.60 | 18.27 |
| | 4 mm | 71.42 | 21.84 |
| | 5 mm | 61.88 | 15.08 |
| **Group L** | No shift | 85.07 | 15.18 |
| | 1 mm | 76.69 | 19.06 |
| | 2 mm | 75.00 | 23.4 |
| | 3 mm | 68.04 | 19.29 |
| | 4 mm | 66.38 | 28.14 |
| | 5 mm | 60.12 | 18.91 |
| | | **Mann-Whitney Test** | |
| **LCN x L** | | | p-value |
| | | No shift | 0.621(ns) |
| | | 1 mm | 0.556(ns) |
| | | 2 mm | 0.490(ns) |
| | | 3 mm | 0.070(ns) |
| | | 4 mm | 0.366(ns) |
| | | 5 mm | 0.926(ns) |

*Note: (ns) = no statistically significant difference*

***Table 4:*** *- Application of the Wilcoxon test for multiple comparisons of the values assigned to each branch of the groups LCN and L from private practice patients.*

| | Deviation | 1 mm | 2 mm | 3 mm | 4 mm | 5 mm |
|---|---|---|---|---|---|---|
| **Group LCN** | No shift | p = 0.689 | p = 0.002* | p = 0.001* | p <0.0001* | p <0.0001* |
| | 1 mm | | p = 0.0033* | p <0.0001* | p <0.0001* | p <0.0001* |
| | 2 mm | | | p = 0.164 | p <0.0001* | p <0.0001* |
| | 3 mm | | | | p = 0.001* | p <0.0001* |
| | 4 mm | | | | | p = 0.0005* |
| **Group L** | No shift | p = 0.009 | p <0.0001* | p <0.0001* | p <0.0001* | p <0.0001* |
| | 1 mm | | p = 0.001* | p <0.0001* | p <0.0001* | p <0.0001* |
| | 2 mm | | | p = 0.269 | p <0.0001* | p <0.0001* |
| | 3 mm | | | | p = 0.005 | p <0.0001* |
| | 4 mm | | | | | p <0.0001* |

*Note:* - Statistically significant (α= 0.05), adjusted by the Bonferroni test (α= 0.0033)*

**Table 5**: Comparison between the segments in each of the shifts of the images of the group LCN.

| Deviation | Segment | Test Result |
|---|---|---|
| No deviation | University<br>Private practice | p = 0.008* |
| 1 mm | University<br>Private practice | p = 0.175 |
| 2 mm | University<br>Private practice | p = 0.002* |
| 3 mm | University<br>Private practice | p = 0.123 |
| 4 mm | University<br>Private practice | p = 0.001* |
| 5 mm | University<br>Private practice | p = 0.011* |

*Note:* - Statistically significant (α= 0.05)*

***Table 6:*** *Comparison between the segments in each of the shifts of the images of the group L.*

| Deviation | Segment | Test Result |
|---|---|---|
| No deviation | University<br>Private practice | p = 0.109(ns) |
| 1 mm | University<br>Private practice | p = 0.828(ns) |
| 2 mm | University<br>Private practice | p = 0.904(ns) |
| 3 mm | University<br>Private practice | p = 0.601(ns) |
| 4 mm | University<br>Private practice | p = 0.344(ns) |
| 5 mm | University<br>Private practice | p = 0.318(ns) |

*Note: (ns) No statistically significant difference*




***Figure 1**: – Group LCN photographs. The number in each picture indicates the amount of the midline shift in millimeters.12*




***Figure 2**: - Group L photographs. The number in each photograph indicates the amount of midline shift in millimeters.12*

The analysis of the correlation between the deviations shown on the images of group LCN and group L and average grades achieved by the evaluators found a strong correlation between the two variables, the Pearson correlation coefficient was r = 0.8663 and r = 0, 9777, respectively (Figure 1).

Table 3 presents the central tendency and dispersion of the scores given to the photographs by private patients. The highest grades were attributed to smiles without deviation, with 1 and 2 mm deviation of the maxillary dental midline, with the lowest scores awarded photos of smiles with 3, 4 or 5 mm deviation, both in group LCN and in group L. Mann-Whitney test was applied to comparisons between group LCN and Group L to verify the interference of adjacent structures to smile. The results showed no statistically significant difference in the evaluation of private patients for any deviation of the maxillary dental midline.

Kolmogorov-Smirnov test was applied to verify the normality of the data and showed that they were not normal

in some deviations. Wilcoxon test, at a significance level of 0.0033 after Bonferroni correction, indicates evidence of statistically significant difference between the groups deviation (Table 4).

The analysis of the correlation between the deviations shown on the image of photos LCN and L and average grades achieved by the evaluators found a strong correlation between the two variables, the Pearson correlation coefficient was r = 0.9751 and r = 0, 9891, respectively (Figure 2).

Comparisons were made between the assessments made by patients of University and private practice. Student's t test was used when there was normality of the data and the Mann-Whitney test was used when there was no normality. There was significant difference when comparing the photos in group LCN, without deviation and deviation of 2, 4 and 5 mm (Table 5).

Again, comparisons were made between the assessments made by patients of University and private practice. Mann-Whitney test was used and there are no differences when comparing all photos in group L (Table 6).

## DISCUSSION

Although the correction of functional and esthetic dental problems is the goal of orthodontic treatment, it is also important to consider the expectations of the patient. Therefore the evaluation of the perception of different individuals about smile features is subject of studies.[1,3-8,13,14] From this work, it was possible to qualify the perception of individuals in orthodontic treatment of the deviation of the maxillary dental midline in smile esthetics.

The evaluators were anable to detect 1 mm deviation, since there was no statistically significant difference between the values awarded to smiles without deviation and with 1 mm deviation, but there was difference in the comparison of smiles without deviation and deviation of 2 mm. All deviations greater than 2 mm were considered statistically significant when compared to photos without deviation.

It was not adopted here the use of full-face photographs, especially for the chance of confusing and dispersing the reviewer.[15]

In addition, it was planned to select only the smile feature related to the maxillary dental midline. The validity and reliability of the use of photographs and VAS as a methodological resource for the evaluation of dental and facial esthetics were proven in other studies.[17,18,20,21]

The concept of what can be a beautiful smile is personal, however, the perception of beauty for orthodontists, dentists and patients is essential to provide scientific data suitable for diagnosis and orthodontic planning.

Most studies used orthodontists, dentists and laypeople as evaluators in research on the midline shifts,[5,6,14,15] however it is wise to know the opinion of the patients[4], since they are the recipients of the benefits of treatment. It is known that the perception of the esthetic by dentists, in particular, the orthodontists is more accurate than the one from laypeople[1,4-,6] but it is believed that patients with the course of treatment, repair increasingly in smile details and supposedly become more critical then laypeople.

The research from Kokich et al[6] which used laypeople in dentistry as evaluators of smile esthetics, attested they were not able to detect midline deviations of up to 4 mm, Pinho et al[5] concluded that the laypeople were not able to notice any deviation in the midline.

On the other hand, An et al[22] compared the esthetic perception of laypeople with no orthodontic treatment history, laypeople with orthodontic treatment history and dentists on aspects that influence the esthetics of the smile and concluded that laypeople with previous experience had the most critical esthetic perception than those who have never been treated orthodontically, agreeing with our hypothesis.

Our results showed no statistically significant difference in evaluation of University patients of group LCN and group L . However there was statistically significant difference in the evaluation of private patients when the deviation of the maxillary dental midline was 2 mm and when the deviation was 3 mm between the photos of group LCN and group L. The photos of group L, received lower scores on average, indicating that the closer the smile appears in the image, the more critical will be the evaluation. The research of Normando et al[14] meets our study when only shows a small difference, but statisticallysignificant, between photos more or less approximate, on the other hand in this case the photos including the nose and the lip philtrum, scored lower values.

Evaluations performed by patients from University and private practice were compared. All the average scores of University evaluators were lower than the average of private practice patients. In addition, there was a statistically significant difference when comparing the photos in group LCN, without deviation and deviation of 2, 4 and 5 mm. This result can be explained by the amount of information received during their queries. Patients from an educational institution regularly hear the instructions of teachers to students during treatment and can absorb more knowledge than a private practice patient

## CONCLUSIONS

According to the methodology used and the results obtained:

Lay in dentistry individuals who are undergoing orthodontic treatment are able to detect the maxillary dental midline deviation from 2 mm;

Viewing structures adjacent to smile affected the perception of deviation of the midline by the private practice patients;

Orthodontic patients from University were more critical then private practice patients.

## REFERENCES

1. Machado AW, Moon W, Luiz Gonzaga Gandini J. Influence of maxillary incisor edge asymmetries on the perception of smile esthetics among orthodontists and laypersons. Am J Orthod Dentofacial Orthop. 2013;143(5):658-64.

2. Câmara CA. Estética em Ortodontia: seis linhas horizontais do sorriso. Dental Press J Orthod. 2010;15:118-31.

3. De-Marchi LM, Pini NIP, Ramos AL, Pascotto RC. Smile attractiveness of patients treated for congenitally missing maxillary lateral incisors as rated by dentists, laypersons, and the patients themselves. J Prosthet Dent. 2014;112:540-6.

4. Beyer JW, Lindauer SJ. Evaluation of Dental Midline Position. Semin Orthod. 1998;4:146-52.

5. Pinho S, Ciriaco C, Faber J, Lenza MA. Impact of dental asymmetries on the perception of smile esthetics. Am J Orthod Orthop. 2007;132(6):748-53.

6. Kokich VO, Kiyak HA, Shapiro PA. Comparing the Perception of Dentists and Lay People to Altered Dental Esthetics. J Esthet Dent. 1999;11:311-24.

7. Sarver DM. Principles of cosmetic dentistry in orthodontics: Part 1. Shape and proportionality of anterior teeth. Am J Orthod Orthop. 2004;126(6):749-53.

8. Zachrisson BU. Esthetic Factors Involved in Anterior Tooth Display and the Smile: Vertical Dimension. J Clin Orthod. 1998;32:432-45.

9. Sarver DM. The importance of incisor positioning in the esthetic smile: The smile arc. Am J Orthod Dentofacial Orthop. 2001;120:98-111.

10. Noureddine A, Fron Chabouis H, Parenton S, Lasserre J-F. Laypersons' esthetic perception of various computer-generated diastemas: A pilot study. J Prosthet Dent. 2014;112:914-20.

11. Motta AFJ. A influência de diferentes componentes dentários na estética do sorriso. Rio de Janeiro: Universidade Federal do Rio de Janeiro; 2009.

12. Ferreira JB, Silva LE, Caetano MTO, Motta AFJ, Cury-Saramago AA, Mucha JN. Perception of midline deviations in smile esthetics by laypersons. Dental Press J Orthod. 2016;21(6):51-7.

13. Lewis PD. The Deviated Midline. Am J Orthod. 1976;(70):601-16.

14. Normando ADC, Azevedo LA, Paixão PN. Quanto de desvio da linha média dentária superior ortodontistas e leigos conseguem perceber? Dental Press J Orthod. 2009;14:73-80.

15. Johnston CD, Burden DJ, Stevenson MR. The influence of dental to facial midline discrepancies on dental attractiveness ratings. Eur J Orthod. 1999;21:517-22.

16. Howells DJ, Shaw WC. The validity and reliability of ratings of dental and facial attractiveness for epidemiologic use. Am J Orthod. 1985;88(5):402-8.

17. Phillips C, Tulloch C, Dann C. Rating of facial attractiveness. Community Dent Oral Epidemiol 1992;20:214-20.

18. Houston WJB. The analysis of errors in orthodontic measurements. Am J Orthod 1983;83:382-90.

19. Spiegel MR. Estatística. São Paulo: Makron Books; 1993.

20. Pithon MM et al. Esthetic perception of black spaces between maxillary central incisors by different age groups. Am J Orthod Dentofacial Orthop 2013;143:371-5.

21. R. M. A. Kiekens, J. C. Maltha, M. Avan't Hof, and A. M. Kuijpers-Jagtman (2006) Objective Measures as Indicators for Facial Esthetics in White Adolescents. The Angle Orthodontist: July 2006, Vol. 76, No. 4, pp. 551-556.

22. An S-M, Choi S-Y, Chung Y-W, Jang T-H, Kang K-H. Comparing esthetic smile perceptions among laypersons with and without orthodontic treatment experience and dentists. Korean J Orthod 2014;44:294-303.

# *MYOSIN 1H* AND THE SOFT TISSUE PROFILE OF AFRICAN AMERICAN FEMALES WITH MANDIBULAR PROGNATHISM

John **Burnheimer**[1*], Kathleen **Deeley**[2], Alexandre R. **Vieira**[2]

[1]Department of Orthodontics and Dentofacial Orthopedics, University of Pittsburgh, Pittsburgh, USA.
[2]Department of Oral Biology, University of Pittsburgh, Pittsburgh, USA.

**Palavras-chave**: Miosina 1H. Perfil de Tecido Mole. Prognatismo.

**RESUMO**

**Introduçâo**: O objetivo desse estudo foi determinar a influência da miosina 1H nos tecidos moles de mulheres americanas negras. **Métodos**: Foram estudadas quatorze mulheres americanas negras participantes do projeto Dental Registry and DNA Repository da Faculdade de Odontologia da Universidade de Pittsburgh com o genótipo comum GG do marcador rs10850110, localizado no lócus 12q24.11. Medidas de onze parâmetros que compõem a análise de tecidos moles de Holdaway foram utilizadas. Diferenças entre etnicidade e medidas normais correspondentes, foram exploradas através do teste t de Student de amostras independentes para todas as medidas faciais. O teste *t* de Student para médias independentes foi usado para determinar diferenças em comparação à medidas normais. A significância foi estabelecida em p<0,05. **Resultados**: Houve uma diferença estatisticamente significante entre quatro das onze medidas de Holdaway. A convexidade média da mulher americana negra foi de 1,0 mm a menos que o valor normal de 5.7 mm (p>0.000). Em contraste, o ângulo H das mulheres americanas negras foi maior que o valor normal. **Conclusões**: O nosso estudo confirma resultados anteriores que a miosina 1H contribui para o prognatismo mandibular. Nossos resultados concordam com a ideia de que a miosina 1H tem menor influência nos tecidos moles da maxila. Entender a influência genética no crescimento dos tecidos moles irá possivelmente permitir melhorar as abordagens de tratamento e prevenção atuais.

**Keywords**: Myosin 1H. Soft Tissue Profile. Prognathism.

**ABSTRACT**

**Introduction**: The aim of this study was to explore the influence of Myosin 1H on the soft tissue profile of African American females. **Methods**: Fourteen African American females from the University of Pittsburgh School of Dental Medicine Dental Registry and DNA Repository with the ancestral genotype GG, marker rs10850110, locus 12q24.11 were analyzed. For this investigation, measurements were taken of the eleven items that comprise the Holdaway soft tissue analysis. Profile differences between ethnicity and corresponding normative values were explored by independent-sample t tests for all facial profile measurements. Student's *t* test for independent means was used to determine differences with accepted norms. Significance was set a p<0.05. **Results**: There were significant differences between four of the eleven Holdaway values and the reported values for African Americans. The mean convexity value of the African American female group was 1.0 mm less the normative value of 5.7 mm (p>0.000). In contrast, the H angle of the African American females was larger than the normative value. **Conclusions:** Our study confirms previous research that Myosin 1H contributes to mandibular prognathism. It agrees with the idea that Myosin 1H is less influential in the maxillary soft tissue complex. Understanding the genetic influence of soft tissue growth would allow improved therapies and prevention approaches.

Submitted: May 5, 2019
Modification: September 23, 2019
Accepted: September 27, 2019

***Correspondence to:**
John Burnheimer
Address: University of Pittsburgh, 3501 Terrace Street, Pittsburgh, USA.
Zip code: 15260
Telephone number: (412) 648-8689
E-mail: jmb334@pitt.edu

## INTRODUCTION

In contemporary orthodontics, predicting mandibular growth continues to be one of the most difficult aspects of treating younger patients. The clinical aspects of a Class III malocclusion can be recognized in childhood and become progressively more evident with growth, contributing to disturbances in both function and esthetics.[1] It has been well documented that there is a substantial link between mandibular prognathism and genetics.[2] Tassopoulou-Fishell et al[3] and da Fontoura et al4 showed evidence that a polymorphism in Myosin 1H (MYO1H) was associated with mandibular prognathism. . Additionally, in a study of Japanese people, a genome-wide association study showed [2] loci (1p32.2 and 1p22.3) susceptible to mandibular prognathism.

We have demonstrated that type II muscle fiber occupancy correlates with malocclusion[6] and MYO1H in particular was associated with mandibular prognathism in humans[3,4,7-9] and zebrafish.10 Unlike Class II myosin heavy chains, which are responsible for muscle contraction and are the basis for classification of skeletal muscle types, Class I is an unconventional myosin group of single-headed monomers involved in cellular signaling mechanisms that regulate membrane dynamics, intracellular vesicle transport and auditory mechanotransduction. The specific molecular functions of MYO1H are yet to be discovered, but defects in the gene lead to jaw cartilage defects.[6,10] To continue to elucidate the underlying mechanism that MYO1H is involved and that leads to mandibular prognathism, this study focused on an analysis of African American women, who have lower third facial lengths higher than their White counterparts.[11]

Whereas many previous studies have focused on a hard tissue analysis, little is known of the influence of MYO1H on the soft tissue profile. One tool that can be utilized to assess soft tissue profiles is the Holdaway soft-tissue cephalometric analysis.

The Holdaway soft tissue analysis has been utilized in several studies to compare different ethnicities to the accepted Holdaway norms. For example, in both Anatolian Turkish and Chinese adults, the skeletal profile convexity value is smaller indicating straighter profile with a tendency to the concave, whereas the Japanese adults exhibit a larger convexity value indicating a more convex profile. The H angle also varies with the ethnicity with the Anatolian Turks closer to the established norm of Holdaway and the Japanese and Chinese exhibiting an increased angle.[13-15]

The Holdaway analysis consists of [11] measurements which are utilized to study the soft tissue profile. The purpose of this study was to compare the characteristics of the soft tissue profile Class III female African American patients (genotype GG, marker rs10850110) to population cephalometric norms.

## MATERIAL AND METHODS

The subjects in this study were orthodontic patients from the Department of Orthodontics and Dentofacial Orthopedics of the School of Dental Medicine at the University of Pittsburgh, who were identified through the Dental Registry and DNA Repository project. Beginning in September 2006, people seeking treatment at the

University of Pittsburgh, School of Dental Medicine are invited to participate in this registry. After informed consent authorizing the use of data from their dental records, saliva samples were obtained from which DNA can be extracted. These samples were stored in Oragen DNA self-collection kits (DNA Genotek, Ottawa, Ontario, Canada) at room temperature until processing. No centrifugation was performed on the samples prior to the DNA extraction and the processing was completed per manufacturer's instructions. This project was approved by the University of Pittsburgh Institutional Review Board (IRB # 0606091).

The WITS appraisal was use to select the participants for this study because this value indicates the relationship of the maxillary and mandibular jaws regardless of intracranial relationship. Our sample included 160 African American females with a negative WITS value. Subjects were excluded if presenting with any abnormal anterior cranial base defects, any facial clefting, or any midfacial growth abnormalities

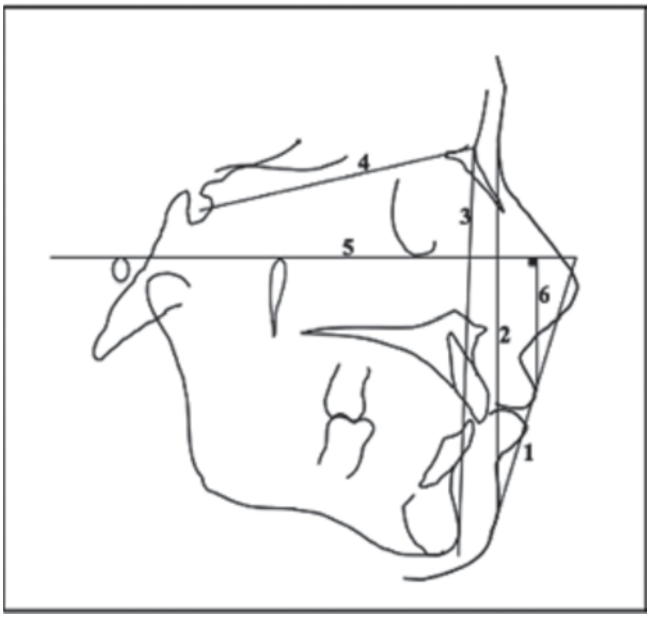


***Figure 1**: Reference lines used in this study 1, The H line drawn tangent to the soft tissue chin and the upper lip; 2, a soft tissue facial line from soft tissue nasion to the point of the soft tissue chin overlaying Ricketts' suprapogonion; 3, the hard tissue facial plane from nasion to pogonion; 4, the sella-nasion line; 5, Frankfort horizontal plane; 6, a line running at a right angle to the Frankfort plane down tangent to the vermilion border of the upper lip.*

caused by cysts, tumors or trauma. After this process, [14] African American females with the ancestral allele GG, marker rs10850110, locus 12q24.[11] were analyzed. The cephalometric radiographs had been previously uploaded into Dolphin Imaging Software. The landmarks of all subjects were digitized by one examiner using Dolphin Imaging Software (version 11.8; Dolphin Imaging and Management Software, Chatsworth, California). For this investigation, measurements were taken of the eleven items that comprise the Holdaway soft tissue analysis and were compared to the software normative values. The reference lines used are shown in Figure 1.[13] The definitions for the linear and angular measurements used are as follows:

1. Skeletal profile convexity (convexity): the distance from point A to the hard tissue line Nasion–Pogonion (Na–Pog).
2. Lower lip to H line (LL-H line): the distance from the lower lip to H line (a tangent drawn from the tip of the chin to the vermilion).
3. Soft tissue facial angle (face angle): the inner angle formed by the intersection of soft tissue nasion–soft tissue suprapogonion line with the Frankfort horizontal plane.
4. Superior sulcus depth (SS depth): the distance between the upper lip sulcus and a perpendicular line drawn from the vermilion to Frankfort plane.
5. Soft tissue subnasale to H line (sub-H line): the distance from subnasale to H line.
6. Basic upper lip thickness (UL-A point): the distance from a point about 3 mm below point A to the drape of the upper lip.
7. Upper lip thickness (UL-vermilion): the distance from the labial surface of upper incisors to the vermilion border of the upper lip.
8. H angle (H angle): the angular measurement of the H line to the soft tissue facial plane.
9. Inferior sulcus to the H line (IS-H line): the distance at the point of maximum curvature on the lower lip and the H line.
10. Soft tissue chin thickness (chin thick): the distance between the two vertical lines representing the hard tissue and soft tissue facial planes at the level of Ricketts' suprapogonion.[16]
11. Nose prominence (nose prom): the distance from a line perpendicular to Frankfort horizontal and running tangent to the vermillion border of the upper lip t the tip of the nose.

All cephalometric radiographs were retraced 2 weeks after the initial assessment by the same examiner and interrater intrarater reliability coefficients were calculated indicating excellent reliability. Descriptive summary of the soft tissue measurements is listed in Table 1.

***Table 1**: Descriptive statistics of sample measurements*

| | Minimun | Maximun | Mean | SD |
|---|---|---|---|---|
| Convexity (mm) | -7.1 | 9.9 | 1.0 | 3.7 |
| LL-H line (mm) | 3.3 | 9.4 | 6.0 | 1.7 |
| Facial angle (°) | 92.6 | 106.7 | 98.5 | 4.8 |
| SS depth (mm) | 4.1 | 9.3 | 6.4 | 1.8 |
| Sub-H line (mm) | 3.3 | 13.5 | 9.6 | 2.9 |
| UL-A point (mm) | 10.9 | 21.2 | 15.2 | 2.4 |
| UL-vermillion (mm) | 11.7 | 16.8 | 14.1 | 1.5 |
| H angle (°) | 4.4 | 20.6 | 15.6 | 3.9 |
| IS-H line (mm) | 0.2 | 4.5 | 1.9 | 1.2 |
| Chin thick (mm) | 11.6 | 21.2 | 14.1 | 2.6 |
| Nasal prom (mm) | -1.2 | 8.9 | 4.6 | 2.7 |

Note*: n=14*

***Table 2**: Comparison of facial profile measurements to established ethnic values*

| | A. A. Females | | | | |
|---|---|---|---|---|---|
| | **Mean** | **SD** | **Norms** | **SD** | **p values** |
| Convexity (mm) | 1.0 | 3.7 | 5.7 | 2 | 0.000 * |
| LL-H line (mm) | 6.0 | 1.7 | 2.9 | 2 | 0.000 * |
| Facial angle (°) | 98.5 | 4.9 | 98 | 7 | 0.715 |
| SS depth (mm) | 6.3 | 1.8 | 5.5 | 1 | 0.093 |
| Sub-H line (mm) | 9.6 | 2.9 | 10 | 2 | 0.581 |
| UL-A point (mm) | 15.2 | 2.4 | 16 | 3 | 0.263 |
| UL-vermillion (mm) | 14.1 | 1.5 | 13.6 | 3 | 0.204 |
| H angle (°) | 15.6 | 4.1 | 10 | 4 | 0.000 * |
| IS-H line (mm) | 1.9 | 1.3 | 3.9 | 2 | 0.000 * |
| Chin thick (mm) | 14.1 | 2.6 | 14.7 | 3.5 | 0.425 |
| Nasal prom (mm) | 4.6 | 2.8 | 5.7 | 3 | 0.154 |

### STATISTICAL ANALYSIS

JMP Pro (SAS Institute Inc., Cary, North Carolina, USA) was used for data analysis. Descriptive statistics comprising means and standard deviations were obtained. Profile differences between ethnicity and corresponding normative values were explored by

independent-sample t tests for all facial profile measurements. Student's t test for independent means was used to determine differences with accepted norms. Significance was set a $p<0.05$.

## RESULTS

Descriptive statistics of the sample measurements of the fourteen African American females are shown in Table 1.

Regarding the soft tissue profile measurements, there were significant differences between four of the eleven Holdaway values and the reported values for African Americans (Table 2).

In this study, the mean convexity value of the African American female group was 1.0 mm, a significantly smaller value, when compared to the normative value of 5.7 mm ($p>0.001$). In contrast, the H angle of the African American females was significantly larger than the normative value.

Two other soft tissue characteristics were significant in this sample and both are located in the lower facial third. The inferior sulcus to the H line was less deep, and the lower lip to the H line significantly more protrusive than normative values.

Of the seven Holdaway values that are not significant, the mean facial angle is nearly identical (98.5° v. 98°) to the normative value and many of the linear measurements are within 1.0 mm of the established values.

## DISCUSSION

The present research aimed to investigate the variation in soft profile tissue of fourteen African American females with the ancestral allele of a marker near MYO1H (rs10850110).

The contribution of MYO1H on mandibular prognathism as assessed by hard tissue metrics has been previously documented.[3,8,17]

MYO1H is a class 1 myosin, but in a different protein grouping than those heavy chain isoforms found in skeletal muscle.[3] However, the influence of muscles on facial growth is well recognized.

Previous studies have indicated that MYO1H has a role in mandibular prognathism when using bony skeletal landmarks, [3,8] however its role in soft tissue profile has not been established.

According to the values presented in Table 1 (min, max and SD) there was great variation for some measures.

The selected sample was not homogeneous in relation to the cephalometric characteristics evaluated. Even though Class III patients were selected, the phenotypic variation of this condition is large. The risk of bias is high, since different conditions could be considered as equal: Class III by mandibular prognathism; Class III by maxillary retrognathism; or Class III by the two conditions.

In this study, when the mean value for each of the eleven Holdaway variables were compared, statistically significant differences were associated with four variables. The skeletal profile convexity, the H angle, the lower lip to H line and inferior sulcus to H line were all statistically different from the established values.

The skeletal profile convexity mean was 4.7 mm less than the norm, indicating a more concave soft tissue profile. This is in contrast to the study of Sushner[18], who in a photographic study of the African American population, found both Class I males and females to be more convex. Similarly, Fonseca and Klein[19], in a cephalometric study of African America women, and Bacon et al.[20], in a study of African Bantu males, found a more convex soft tissue profile. In these studies, patients were selected who had Class I occlusions and either considered attractive or with no obvious facial abnormalities. This difference could be explained by the fact that our subjects exhibited Class III profile charateristics.

Whereas convexity was less than the norm in our sample, the H angle mean was greater than the established African American norms. This compares favorably with the norms reported for Chinese, Saudi and Anatolian Turkish populations.[13, 14, 21] The H angle can be influenced by the position of either the mandible or chin, individually, or in combination.

Ideally, the skeletal profile convexity moves in tandem with the H angle for a harmonious soft tissue profile.[7] Typically, a higher angle correlates with greater convexity. However, our sample showed a higher value for the H angle in relation to the norms, which would indicate more convexity, that is, a more Class II profile. Nonetheless, in mandibular prognathic patients, the influence of MYO1H may have a different effect on the soft tissue development, primarily an increased upper lip thickness as opposed to its effects on the hard tissue.6 Extreme values of the H angle are shown in Figure 2.



***Figure 2**: Example of extreme values of H angle*

Two other soft tissue profile areas, both in the lower facial third, had values significantly different than accepted norms for African Americans.

Significant protrusion of the lower lip to H line (LL-H line) was found in our sample of African American females. This is in agreement with Fonseca and Klein[19] who found that the projection of the lower lip to be significantly greater in American Black women, but in contrast to other research which found the lower lip in better proportion to the soft

tissue profile.[18,21] Farrow et al.[22] surveyed 465 people and found that all groups preferred an African American soft tissue profile that was slightly convex with lips anteriorly placed. Perhaps, the most likely explanation for what appears to clinically be an increase in lip thickness is actually an increased eversion of the lower lip tissue between the upper and lower vermillion borders. While there is no significant difference in chin thickness from the normative values, the influence of MYO1H on this area of the soft tissue profile cannot be excluded.

Surprisingly, the inferior sulcus to the H line (IS-H line) was found to be significantly shallower when compared to the African American norms. Other research has found that the inferior sulcus depth is deeper.[21] Typically, as the protrusion of the lower lip rolls out beyond the H line, the inferior sulcus becomes deeper, not shallower.[7] Once again, this may be under the influence of MYO1H.[8]

Other researchers have shown that in Saudi and Anatolian Turkish adults, both the superior sulcus depth and the UL-vermillion border values were less than our sample.[21] Additionally, Sushner[18] found in his sample of attractive looking North American blacks that the soft tissue of the upper lip was tending to either straight or convex.

In this study, the deeper sulcus depth could partially be attributed to retrusive A- point and a thinner than normal upper lip thickness in conjunction with a slightly thicker lip at the vermillion border. If the vermillion border area were thinner in comparison to the UL-A point area, this would be indicative of lip strain.[7] This was not apparent in our sample.

The facial angle was nearly identical (98.5° v. 98.0°) indicating chin prominence of this sample is nearly identical when compared to the African American norms. The facial angle for both the Saudi and Anatolian Turkish norms compare favorably to the original norms of Holdaway.[13,21] This is somewhat surprising as the mandible exhibits the greatest variation in size and form of all the bones that make up the face.[12]

Nasal prominence was 1mm less than the African American norm. This is in agreement with Fonseca[19] and Isiekwe[23] who also found the nasal tip projection to be shorter in their evaluation of a population of African descent. Similarly, in studies involving Saudi and Anatolian Turks, the Saudi nasal prominence is reduced when compared to the Anatolian Turkish norms.[21] However, both are larger than the African American nasal prominence in this study.

Our study would advance the idea MYO1H may influence variations in the soft tissue profile characteristics in Class III female African American patients (genotype GG, marker rs10850110). Once again, supporting the work of Subtelny24 that not all areas of the face follow the underlying structures. Certainly, a better understanding the genetic influence of soft tissue growth would allow improved therapies and preventive strategies, especially in younger patients with developing mandibular prognathism.

Since our sample size was modest, one cannot discount the possibility that other genes play a role in the variation of the soft tissue profile. Given that a post hoc power analysis would suggest the study was under powered, the main objective of this research was to compare these findings to normative values. Even though these variations in the soft tissue could be found in any other sample of Class III patients, we hypothesize that the differences are influenced by MYO1H, but more conclusive evidence would arise from a comparison with individuals without the genetic variant. Future research would need to consider all genes in the family as candidates for a role in the soft tissue profile variation in mandibular prognathism of African American females.

## CONCLUSIONS

In this study of African American females with the ancestral allele of MYO1H who exhibit mandibular prognathism, four of the eleven Holdaway soft tissue values were significantly different from the established norms for African Americans. The suggestion that muscle function, as related to MYO1H, may have a role in the development of the soft tissue profile in mandibular prognathism is intriguing. Certainly, with this modest sample size, replication of these findings and expansion to other populations is indicated.

## REFERENCES

1.Stenvik A, Espeland L, Berg RE. A 57-year follow-up of occlusal changes, oral health, and attitudes toward teeth. Am J Orthod Dentofacial Orthop 2011;139:102-8

2.Watanabe M, Suda N, Ohyama K. Mandibular prognathism in Japanese families ascertained through orthognathically treated patients. Am J Orthod Dentofacial Orthop 2005;128:466-70.doi.org/10.1016/j.ajodo.2004.09.018

3.Tassopoulou-Fishell M, Deeley K, Harvey EM, Sciote J, Vieira AR. Genetic variation in myosin 1 H contributes to mandibular prognathism. Am J Orthod Dentofacial Orthop 2012;141:51-9.doi.org/10.1016/j.ajodo.2011.06.033

4.da Fontoura CSG, Miller SF, Wehby GL, Amendt BA, Holton NE, Southard TE, et al. Candidate gene analyses of skeletal variation in malocclusion. J Dent Res 2015;94:913-20
5.Ikuno K, Kajii TS, Oka A, Inoko H, Ishikawa H, Iida J. Microsatellite genome-wide association study for mandibular prognathism. Am J Orthod Dentofacial Orthop 2014;145:757-62.
6.Desh H, Gray SL, Horton MJ, Raoul G, Rowlerson AM, Ferri J, Vieira AR, Sciote JJ. Molecular motor MYO1C, acetyltransferase KAT6B and osteogenetic transcription factor RUNX2 expression in human masseter muscle contributes to development of malocclusion. Arch Oral Biol. 2014 Jun;59(6):601-7.
7. Arun RM, Lakkakula BV, Chitharanjan AB. Role of myosin 1H gene polymorphisms in mandibular retrognathism. Am J Orthod Dentofacial Orthop. 2016 May;149(5):699-704.
8. Cruz CV, Mattos CT, Maia JM, Granjeiro JM, Reis MF, Mucha JN, Vilella B, Ruellas AC, Luiz RR, Costa MC Vieira AR. Genetic polymorphisms underlying the skeletal Class III phenotype. Am J Orthod Dentofacial Orthop 2017;151:700-7. doi.org/10.1016/j.ajodo.2016.09.013
9. Cunha A, Nelson-Filho P, Marañón-Vásquez GA, Ramos AGC, Dantas B, Sebastiani AM, Silvério F, Omori MA, Rodrigues AS, Teixeira EC, Levy SC, Araújo MC, Matsumoto MAN, Romano FL, Antunes LAA, Costa DJD, Scariot R, Antunes LS, Vieira AR, Küchler EC. Genetic variants in ACTN3 and MYO1H are associated with sagittal and vertical craniofacial skeletal patterns. Arch Oral Biol. 2019 Jan;97:85-90.
10. Sun R, Wang Y, Jin M, Chen L, Cao Y, Chen F. Identification and Functional Studies of MYO1H for Mandibular Prognathism. J Dent Res. 2018 Dec;97(13):1501-1509
11. Porter JP, Olson KL. Anthropometric facial analysis of the African American woman. Arch Facial Plast Surg. 2001;3(3):191-197.
12.Holdaway RA. A soft-tissue cephalometric analysis and its use in orthodontic treatment planning. Part 1. Am J Orthod 1983;84:1-28.doi.org/10.1016/0002-9416(83)90144-6
13.Basciftci FA, Uysal T, Buyukerkmen A. Determination of Holdaway soft tissue norms in Anatolian Turkish adults. Am J Orthod Dentofacial Orthop 2003;123:395-400. doi.org/10.1067/mod.2003.139
14.Lew KK, Ho KK, Keng SB, Ho KH. Soft-tissue cephalometric norms in Chinese adults with esthetic facial profiles. J Oral Maxillofac Surg 1992;50:1184-9. doi.org/10.1016/0278-2391(92)90151-O
15.Alcalde RE, Jinno T, Orsini MG, Sasaki A, Sugiyama RM, Matsumura T. Soft tissue cephalometric norms in Japanese adults. Am J Orthod Dentofacial Orthop 2000;118:84-9.doi.org/10.1067/mod.2000.104411
16.Ricketts RM. Planning treatment on the basis of the facial pattern and an estimate of its growth. Angle Orthod 1957;27:14-37.
17.Moreno Uribe LM, Vela KC, Kummet C, Dawson DV, Southard TE. Phenotypic diversity in white adults with moderate to severe Class III malocclusion. Am J Orthod Dentofacial Orthop 2013;144:32-42.doi.org/10.1016/j.ajodo.2013.02.019
18.Sushner NI. A photographic study of the soft-tissue profile of the Negro population. Am J Orthod 1977;72:373-85.doi.org/10.1016/0002-9416(77)90350-5
19.Fonseca RJ, Klein WD. A cephalometric evaluation of American Negro women. Am J Orthod 1978;73:152-60.doi.org/10.1016/0002-9416(78)90185-9
20.Bacon W, Girardin P, Turlot JC. A comparison of cephalometric norms for the African Bantu and caucasoid population. Eur J Orthod 1983;5:233-240. doi.org/10.1093/ejo/5.3.233
21.ALBarakati SF, Bindayel NA. Holdaway soft tissue cephalometric standards for Saudi Adults. King Saud Univ J Dent Sci 2012;3:27-32.
22.Farrow AL, Zarrinnia K, Azizi K. Bimaxillary protrusion in black Americans-an esthetic evaluation and the treatment consideration. Am J Orthod Dentofacial Orthop 1993;104:240-50.doi.org/10.1016/S0889-5406(05)81725-1
23.Isiekwe GI, daCosta OO, Utomi IL, Sanu OO. Holdaway's analysis of the nose prominence of an adult Nigerian population. Niger J Clin Pract 2015;18:548-552.
24.Subtelny JD. A longitudinal study of soft tissue facial structures and their profile characteristics, defined in relation to underlaying skeletal structures. Am J Orthod 1959;45:481-507.doi.org/10.1016/0002-9416(59)90014-4

# ORAL FINDINGS IN ROBINOW SYNDROME: A CASE REPORT IN PEDIATRIC PATIENT

Camila **Nassur**[1], Adílis Kalina **Alexandria**[2*], Luciana **Pomarico**[1], Gloria Fernanda Barbosa de Araújo **Castro**[1]

[1]Department of Pediatric Dentistry and Orthodontics, School of Dentistry, Federal University of Rio de Janeiro (UFRJ), Rio de Janeiro, RJ, Brazil
[2]Department of Preventive and Community Dentistry, Rio de Janeiro State University (UERJ), Rio de Janeiro, RJ, Brazil

**Palavras-chave:** Odontopediatria. Saúde Oral.Tratamento Dentário.

**RESUMO**

**Objetivo:** O objetivo deste artigo foi descrever um caso de síndrome de Robinow em um paciente pediátrico. **Relato de Caso**: Clinicamente, o paciente apresentava bossas frontais, perfil facial plano com macrocefalia, hipoplasia da face média, hipertelorismo, fissuras palpebrais amplas, boca triangular, nariz curto, filtro curto, anquiloglossia, retenção prolongada de dentes decíduos e dentes desalinhados. Os exames radiográficos indicaram a presença de três elementos supranumerários permanentes impactados, agenesia de oito dentes permanentes e encurtamento radicular de todos os dentes permanentes. O tratamento proposto foi a extração de todos os dentes decíduos retidos e os elementos supranumerários, instruções de higiene bucal e dietética e tratamento ortodôntico. Além disso, aspectos importantes para evitar complicações associadas à síndrome de Robinow são discutidos. **Conclusão**: Este caso descreve achados orais incomuns e alguns aspectos importantes para evitar complicações associadas à síndrome de Robinow. Aconselhamento profissional precoce, tratamento e acompanhamento periódico podem melhorar a qualidade de vida desses pacientes.

**Keywords:** Pediatric Dentistry. Oral Health. Dental Treatment.

**ABSTRACT**

**Objective:** The aim of this article was to describe a case of Robinow syndrome in a pediatric patient. **Case Report:** Clinically, the patient had frontal bossing, flat facial profile with macrocephaly, midfacial hypoplasia, hypertelorism, wide palpebral fissures, triangular mouth, short upturned nose, short philtrum, ankyloglossia, prolonged retention of primary teeth and abnormal aligment of teeth. The radiographic exams indicated the presence of three impacted permanent supernumerary teeth, agenesis of eight permanent teeth and dental root shortening of all permanent teeth. The treatment proposed was the extraction of all retained primary teeth and the supernumerary teeth, dietary and oral hygiene instructions and orthodontic treatment. Also, important aspects to avoid complications associated with Robinow syndrome were discussed. **Conclusion:** This case describes uncommon oral findings and some important aspects to avoid complications associated with the Robinow syndrome. Early professional advice, treatment, and periodical follow-ups can improve the quality of life of these patients.

Submitted: June 7, 2019
Modification: September 6, 2019
Accepted: September 9, 2019

***Correspondence to:**
Adílis Kalina Alexandria
Address: Departamento de Odontologia Preventiva e Comunitária, Faculdade de Odontologia, Universidade do Estado do Rio de Janeiro, Pavilhão Mario Franco Barroso 2º andar. Av. 28 de Setembro, 157 - Vila Isabel, Rio de Janeiro, RJ, Brazil.
Zip code: 20551-030
E-mail: adilis.alexandria@gmail.com.br

## INTRODUCTION

The Robinow syndrome (RS) is a rare genetic disorder as a syndrome characterized by a fetal face, orodental abnormalities, mesomelic dwarfism and genital hypoplasia. [1] The syndrome is classified into dominant or recessive type and the recessive form has more severe symptomology. [2-3] Affected in equal frequency males and females and occur in 1:500.000 births, the prevalence is low, because due cardiac problems, 5–10% of the children die in infancy. [4] The gene for the autosomal recessive Robinow syndrome was mapped and first localized to chromosome 9q22. [5] Facial and oral findings are important to diagnosis, management and planning of dental treatment for Robinow syndrome patients.

Cardiovascular, craniofacial and renal tract abnormalities were reported, skeletal abnormalities as wide forehead, hypertelorism, midface hypoplasia, depressed nasal bridge, compressed and enlarged nose, low-set ears, micrognathia and triangular mouth were observed. [6-8] Usual oral findings comprise dental anomalies and dental crowding, gingival hyperplasia and tongue abnormalities. [6,9] The aim of this article is to present a case of a child with autosomal recessive Robinow syndrome and describe the facial and dental abnormalities.

## CASE REPORT

A 13 year old male, leucoderma, was diagnosed with Robinow syndrome and was referred by his pediatric doctor to the Pediatric Dentistry Department of a public university in Rio de Janeiro, Brazil, for a dental appointment.

During anamnesis, the mother reported an uneventful pregnancy, and hospitalization of the patient for 28 days at birth was due to septic arthritis. According to his medical history, the patient was diagnosed at birth as having the




***Figure 1**: (A) Frontal extraoral aspect of patient. (B) Lateral extraoral aspect of patient.*




***Figure 2**: (A) Intraoral aspect of mouth. (B) Upper arch aspect and (C) Lower arch **aspect.***




***Figure 3**: Orthopantographic radiograph: dental root shortening of all permanent teeth.*



**Figure 4**: *Orthodontic treatment using a fixed orthodontic appliance.*

Robinow syndrome with the autosomal recessive form (diagnosis based on clinical features alone), as he had characteristic facial dysmorphism (fetal facies), genital hypoplasia, and mesomelic brachymelia.

The family history was negative for even the mildest manifestations of the Robinow syndrome and revealed the absence of parental consanguinity; also the patient´s elder sibling showed none of the clinical aspects typical of the syndrome. At the age of 6, he underwent a surgical procedure to evaginate his micropenis. He exhibited a normal intelligence, and no congenital heart disease was diagnosed.

Extraoral examination revealed frontal bossing, flat facial profile with large head, long philtrum, lower lip deficiency, midfacial hypoplasia, hypertelorism, wide palpebral fissures, ear abnormality, small and lower set, triangular mouth, short upturned nose and broad nasal bridge (Figure 1A and 1B).

Intraoral examination revealed shortened and bifid tongue, gingival hyperplasia, and ankyloglossia. Also, the exam showed a prolonged retention of four primary canines, the primary upper central incisors and the primary lower and upper first molars. Good oral hygiene was observed and no caries were found but there were misaligned teeth (Figure 2A, 2B and 2C).

The radiographic exams indicated the presence of another two impacted permanent supernumerary elements in the pre-maxilla region and one supernumerary tooth near the upper right first premolar, agenesis of the four second premolars, lower permanent second and third molars. Furthermore, panoramic radiograph showed dental root shortening of all permanent teeth (Figure 3).

The treatment proposed extraction of all retained primary teeth and the supernumerary elements, dietary and oral hygiene instruction. The treatment of patient was planned after medical approval. The patient was referred for orthodontic treatment and, is using a fixed orthodontic appliance since one year ago (Figure 4).

# DISCUSSION

Robinow syndrome is a genetic disorder characterized by facial dysmorphisms, genital hypoplasia, and orodental abnormalities. [1] The autosomal recessive form is caused by variants in ROR2 at 9q22 and encodes a tyrosine kinase receptor involved in cell growth and differentiation. [5-6]

Recognize facial and oral findings is important to planning dental treatment and some common findings in a Robnow syndrome patient were also observed in our clinical case as short stature, mesomelic limb shortening, short and broad fingers, macrocephaly and a dysmorphic face with prominent eyes, flat nasal bridge, frontal bossing, hypertelorism, short noses and dental anomalies. [6,8,9] According to Mazzeu *et al.,* [7] over 79% of patients with RS present these characteristic facial features. Other associated malformations include cleft lip and palate, syndactyly and heart defects [6,7] that were not observed in the patient.

In relation to orofacial manifestations of the Robinow syndrome, Basman *et al.* [9] described a case with a boy that presented tongue tip absence, ankyloglossia, arched palate and delayed tooth eruption. In our case, these findings were also present, except the arched palate. Others findings that coincide with our case were also recognized by Altunkas *et al.* [10] as new syndrome features and include: short tooth roots and narrow and thick-oored pulp chambers. However, some features described in our case are rarely described in a case of RS, including prolonged retention of primary teeth, supernumerary teeth and the absence of permanent teeth. Although facial dysmorphism is evident, intraoral aspects are little explored in literature, so we emphasize the importance of reporting such findings and proposing treatments that may bring quality of life for these patients.

Mazzeu *et al.* [7] described supernumerary teeth exclusively in patients with the dominant form, only in 10.3% of these patients. The problems most commonly associated with supernumerary teeth include impairment of the chronology of eruption, rotation and crowding, resorption of adjacent teeth and cyst formation. [7,11] Prolonged retention of deciduous teeth can be also associated with dental crowding, that are prevalent in patients with RS. The severity of the dental crowding contributes to increase the appearance of gingival hyperplasia and alveolar deformity. [7,11] Despite dental crowding, there isn't necessarily a lack of space, and the diastemas which can be observed are a result of hypodontia. [11] Shift in the normal midline, difficulty in dental hygiene, severe anterior open bite, deep bite, anterior and posterior crossbite were frequently found in these patients. [7,12] Though, no specific malocclusion characterizes this syndrome [8,12] early diagnosis and treatment are essential to prevent or minimize complications.

Most of the patients with Robinow syndrome have normal intelligence and accept treatment, however, they often require surgical interventions due to bone deformities and the need for dental extractions. [4] Hypertension, heart and kidney disease are frequent findings associated to RS and may represent complicating factors for surgeries. [9,11] Our patient did not report any systemic problem during anamnesis, despite that, medical authorization were requested before the extraction of supernumerary and retained primary teeth. Cardiac, renal disease, hypertension and vertebral anomalies have been reported in older patients, [9,11,13] it seems that such problems may arise in childhood or later. But no reports of surgical complications were found in RS patients.

A disabled person most often presents some difficulties or a delay in their psychomotor development, speech acquisition and other skills, thus, often the dental treatment provided is less than the real needs. However, when the patient has the ability to cooperate during dental treatment, which was the case with our patient, the treatment can be performed more efficiently. The good behavior of our patient allowed extractions under local anesthesia and then the orthodontic treatment to promote dental alignment, improving aesthetics and facilitating patient oral hygiene. The patient is still undergoing orthodontic treatment, but this could be performed as usual. Other articles cited the need for gingival and orthodontic corrections in patients with RS, successfully performing common treatment. [9,13] Only one case has been found reporting severe hyperplastic gingival tissue impeding both normal tooth eruption as well as orthodontic movement, probably caused by the use of growth hormone. [8]

This case describes uncommon oral findings and some important aspects to avoid complications associated with the Robinow syndrome. Early professional advice, treatment, and periodical follow-ups can improve the quality of life of these patients.

## REFERENCES

1. Robinow M. The Robinow (fetal face) syndrome: a continuing puzzle. Clin Dysmorphol. 1993, 2(3):189-98.

2. Jain PS, Gupte TS, Jetpurwala AM, Dedhia SP. Robinow Syndrome and Fusion of Primary Teeth. Contemp Clin Dent. 2017, 8(3):479-481.

3. Kamath BM, Bason L, Piccoli DA, Krantz ID, Spinner NB. Consequences of JAG1 mutations. J Med Genet. 2003, 40(12):891-5.

4. Hosalkar HS, Gerardi J, Shaw BA. Robinow syndrome. J Postgrad Med. 2002, 48(1):50-1.

5. Soman C, Lingappa A. Robinow Syndrome: A Rare Case Report and Review of Literature. Int J Clin Pediatr Dent. 2015, 8(2):149-152.

6. Mishra S, Agarwalla SK, Pradhan S. Robinow Syndrome: A Rare Diagnosis. J Clin Diagn Res. 2015, 9(12):SD04-5.

7. Mazzeu JF, Pardono E, Vianna-Morgante AM, Richieri-Costa A, Kim C, Brunoni D, Martelli L, de Andrade CE, Colin G, Otto PA. Clinical characterization of autosomal dominant and recessive variants of Robinow syndrome. Am J Med Genet. 2007, 143(4):320-5.

8. Grothe R, Anderson-Cermin C, Beiraghi S. Autosomal recessive Robinow syndrome: a case report. J Dent Child. 2008, 75(1):48-54.

9. Basman A, Akay G, Peker I, Gungor K, Akarslan Z, Ozcan S, Ucok CO. Dental management and orofacial manifestations of a patient with Robinow Syndrome. J Istanb Univ Fac Dent. 2017, 51(2):43-48.

10. Altunkas A, Sarikaya B, Aktas F, Ozmen Z, Sonmezgoz F, Acu B, Pinarbasili T, Firat MM. Vertebral anomalies accompanying Robinow syndrome. Spine J. 2016, 16(5):e341-2.

11. Beiraghi S, Leon-Salazar V, Larson BE, John MT, Cunningham ML, Petryk A, Lohr JL. Craniofacial and intraoral phenotype of Robinow syndrome forms. Clin Genet. 2011, 80:15-24.

12. Cerqueira DF, de Souza IP. Orofacial manifestations of Robinow's syndrome: a case report in a pediatric patient. Oral Surg Oral Med Oral Pathol Oral Radiol Endod. 2008, 105(3):353-357.

13. Tufan F, Cefle K, Türkmen S, Türkmen A, Zorba U, Memduh D, Ozturk S, Palanduz S, Ecder T, Mundlos S, Horn D. Clinical and molecular characterization of two adults with autosomal recessive Robinow syndrome. American Journal of Medical Genetics. 2005, 136A:185-189.

# DEVELOPMENT OF ODONTOMA IN THE PERMANENT DENTITION AFTER INTRUSION OF PRIMARY INCISORS: CASE REPORT

Daniela Maria Carvalho **Pugliesi**[1]*, Valdeci Elias dos Santos **Junior**[1], Camila Maria Beder **Ribeiro**[1], Lisa Danielly Curcino **Araujo**[1], Pedro Jorge Cavalcante **Costa**[1], Guilherme Costa do **Amaral**[2]

[1]School of Dentistry, Federal University of Alagoas, Maceió, AL, Brazil.
[2]Faculty of Dentistry of the University Center Cesmac, Maceió, AL, Brazil.

**Palavras-chave**: Traumatismos Dentários. Luxação Intrusiva. Odontoma.

**RESUMO**

**Introdução**: O traumatismo dentário na infância é uma intercorrência grave, de incidência alta devido principalmente a fase de descobertas, com o início dos primeiros passos, sem ter coordenação motora adequada, tornando as crianças mais propensas a quedas. Um trauma em um dente decíduo pode deixar sequelas em razão da proximidade anatômica ao germe do dente sucessor permanente. **Objetivo:** O objetivo deste trabalho foi relatar um caso de intrusão grave em bebê de 10 meses, com surgimento de Odontoma após trauma dentário. **Relato de Caso:** Paciente de 9 anos de idade, acompanhada pela responsável, procurou atendimento pelo atraso na esfoliação dos dentes decíduos. Durante a anamneses foi constatado traumatismo na dentição decídua aos 10 meses de idade, e em seguida realizado o exame clínico e radiográfico, demostrando a presença de odontoma nos dentes 11 e 21. O plano de tratamento multidisciplinar compreendeu a cirurgia para remoção do odontoma, com posterior tratamento ortodôntico reabilitador. **Conclusão:** O trauma na dentição decídua pode gerar diversas consequências para a dentição permanente. Desse modo é necessário um atendimento odontológico logo após o incidente e um proservação do caso, para avaliar possíveis sequelas.

**Keywords**: Dental Injuries. Intrusive Dislocation. Odontoma.

**ABSTRACT**

**Introduction:** Dental trauma in childhood is a serious and high incidence complication, mostly due to the discovery phase. This is when the first steps begin, without adequate motor coordination, making children more prone to falls. Trauma to a deciduous tooth can leave sequelae owing to the anatomical proximity to the permanent successor tooth germ. **Objective**: This study aimed to report a case of severe intrusion in a 10-month-old baby with the emergence of odontoma after dental trauma. **Case Report:** A 9-year-old patient, accompanied by the guardian, sought attendance for delayed primary teeth exfoliation. During anamnesis, the trauma to the deciduous dentition was found in a 10-month old child, followed by clinical and radiographic examination, showing the presence of odontoma in teeth 11 and 21. The multidisciplinary treatment plan included surgery to remove the odontoma, with subsequent rehabilitation. **Conclusion**: Trauma to primary dentition can have several consequences for permanent dentition. Thus, dental care is required soon after the incident, besides careful follow-up to evaluate possible sequelae.

Submitted: June 27, 2019
Modification: August 21, 2019
Accepted: September 6, 2019

***Correspondence to**:
Daniela Maria Carvalho Pugliesi
Address: Av Lourival Melo Mota, S / N, the Martins Board, Maceió, AL, Brazil. Zip code: 57072-970.
Telephone number: 55 (82) 99993-9933
E-mail: dpugliesi@hotmail.com

## INTRODUCTION

Traumatic injuries in primary teeth are common events in early childhood, with prevalence around 30%, from a very early age, considering children are learning to walk and discover everything around and are more likely to suffer traumatic injuries.[1,2]Curiosity and restlessness, behavioral characteristics of this age group, cause the child to explore the environment surrounding it. However, because they do not have sufficiently mature motor skills to prevent falls and to promote self-protection, they are potential subjects to mouth[3]trauma.[4]

Note that, as in very young patients, trauma is not only physical. There is the children's emotional involvement and that of their companions, who often come forward with an immediate solution.[5,6] Dentists should be prepared to receive and to solve the treatment needs of each type of dental trauma, transmitting security and reassuring the family.[7-9]

About 90% of the injuries affect the maxilla and, as a result of the anatomical arrangement, the upper central incisor teeth are the most often involved. The dislocation type of injury is the most common in deciduous teeth, constituting more than 88% of the different types of traumas affecting these teeth. This is due to the higher porosity and resilience of the alveolar bone in this age group, which favors displacements, contrary to what occurs in permanent teeth, which are prevalent fractures .[5-10,11]

Among the dislocations affecting the deciduous teeth, intrusive trauma occurs at a frequency that varies from 15 to 23%. [9-14] The intrusions are the result of a direct impact, accident in the incisal edge in an axial direction by moving the tooth towards the interior of its cavity, producing a maximum damage to the pulp and the tooth support structures. [2,4,9-10, 12-14]

In addition to the epidemiological relevance, importance determined by other injuries to primary teeth, is the potential to cause disturbances in the germs of the permanent teeth which are developing.[6,7,10,14] Thus, the care of children with trauma in the primary dentition requires a different approach from that to permanent ones, since the anatomical relationship between both dentitions is considered a risk factor in the onset of damage to permanent odontogenesis. [6,7,9, 10-15]

In this sense, intrusion again emerges as the type of dental injury that occurs to primary dentition and more often leads to damage to the germs of permanent teeth, with a prevalence ranging between 18 and 69%. [5-7, 9-12,14,15-17] The sort and severity of the development changes caused at the time of the traumatic impact depend on several factors, including the type of trauma in primary teeth, direction and severity of tooth displacement, the child's age at the time of trauma and type of treatment used. [2,4-7,10-12,16-20]

One of the most serious consequences observed after the intrusion of primary teeth is the development of odontomas involving the permanent successor germs. This kind of defect is considered a benign odontogenic tumor, in which all dental tissues are represented[21]. The histogenesis of the lesion is currently considered a developmental disorder and, as such, can occur under the influence of several causative agents. [22-24]

Clinically, they are most commonly detected in the first two decades of life, with a predilection for females. [21-24].Their pathogenesis is an investigated aspect, albeit undetermined so far. The most accepted etiology is related to trauma, infection or pressure, causing disturbance in the genetic control mechanism and tooth development. [20-27]

Regarding dental trauma, this change is believed to be due to a severe dental injury affecting 1 to 3-year old children, [20-23] when at the time of impact, the deciduous tooth root invades the follicle germ of the permanent tooth in the early stage of its training, fragmenting it. This fragmentation can result in the formation of a mass composed of separate tooth tissue structures. [21-24, 25,26-29]

Thus, the purpose of this study is to report a case of severe intrusive luxation of teeth 51 and 61 in a 10-month old baby with their consequent re-eruption after 5 months. However, at 9 years of age, due to the non-exfoliation thereof, we performed a routine radiographic examination and found odontoma-like malformations involving the central incisors permanent successors.

## CASE REPORT

A 9-year old female patient came for dental treatment accompanied by her mother, who reported that "my daughter's teeth were not replaced." During anamnesis, we did not observe any systemic disease but, in an intraoral-physical examination, the preceding prolonged retention of deciduous incisors, and multiple carious lesions in other elements were observed (Figure 1A and 1B). In the image examination, panoramic radiographs showed the presence of two radiopaque calcified lesions in the anterior maxilla, impacting the eruption of the permanent successors, suggesting odontoma (Figure 1C).

The mother reported that her daughter tumbled off the crib at 10 months, and the child hit its mouth against the ground, causing a severe intrusive luxation of teeth 51 and 61. Also according to the mother, after five months, the same re-eruption was uneventful. A CT scan was requested (CT), using cone beam jaw (3D CT scanner Cranex), to close the complete diagnosis of the case. The tomographic report revealed the presence of a two-compound included odontoma, located below the crowns of teeth 11 and 21, interfering with their eruption (Figure 1D).

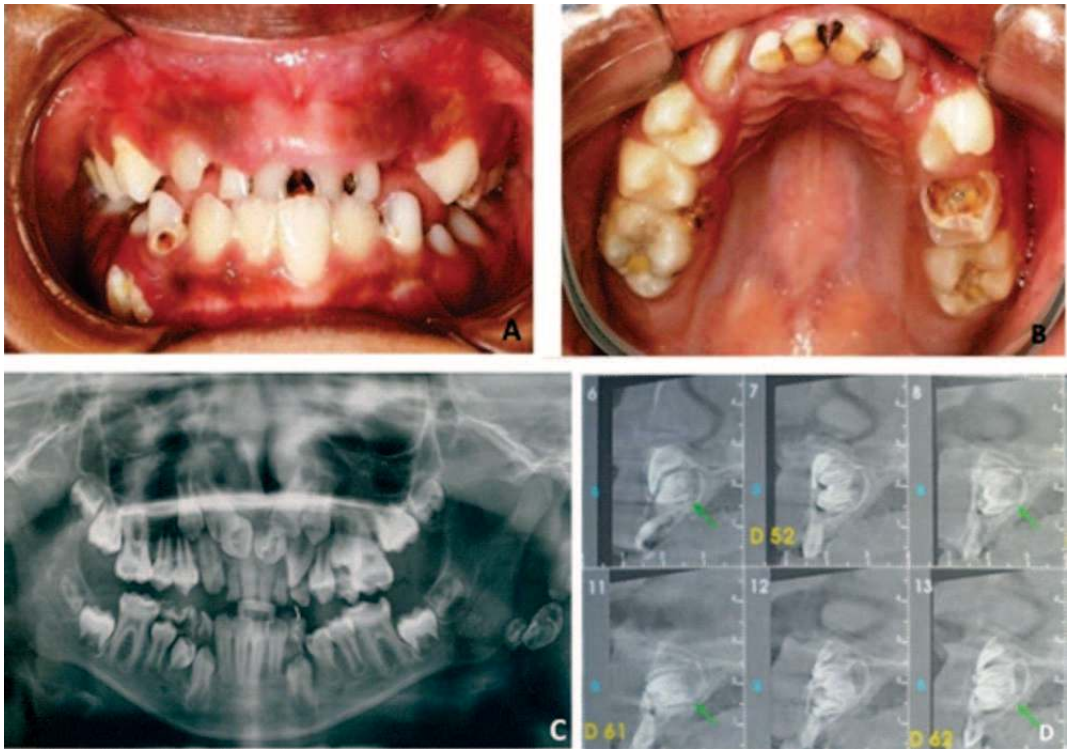


***Figure 1**: (A) Intraoral appearance showing prolonged retention of the foregoing upper deciduous incisors; (B) Intraoral appearance showing extensive carious lesions; (C) Panoramic X-ray image showing retention associated with radiopaque lesions suggesting odontoma; (D) CT image demonstrating sequences of parasagittal sections showing primary elements of the fasteners associated with the presence of odontoma.*

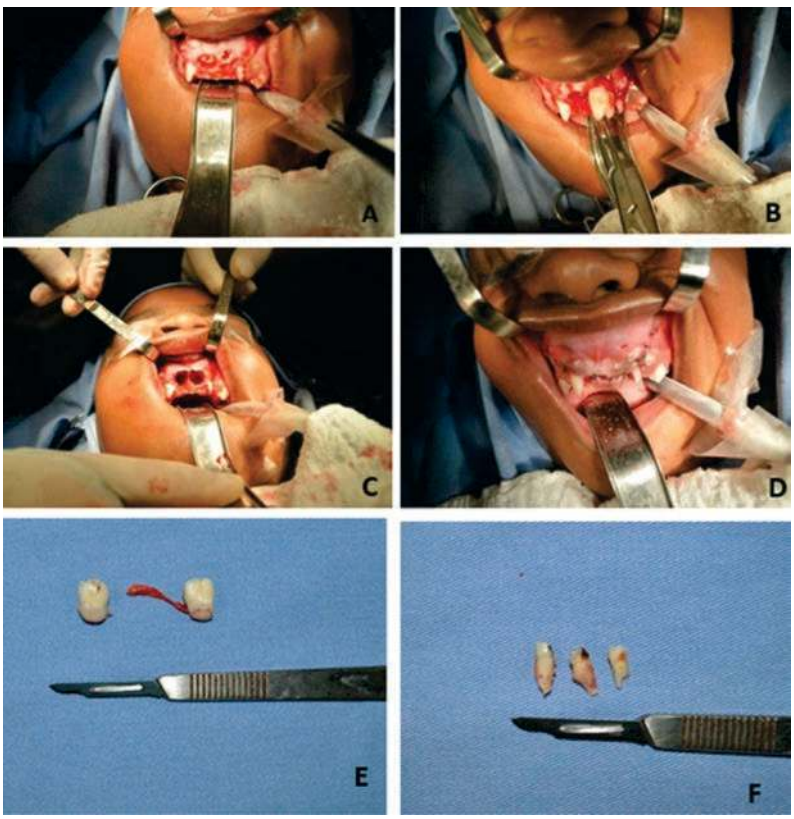


***Figure 2**: (A) Ostectomies and exposure of odontomas right and left; (B) Removing the top left; (C) Intraoral appearance of the front view of the surgical sites; (D) Retail repositioned and isolated simple point suture; (E) Macroscopic aspects of odontomas sent for histopathological examination; (F) Deciduous extracted elements.*

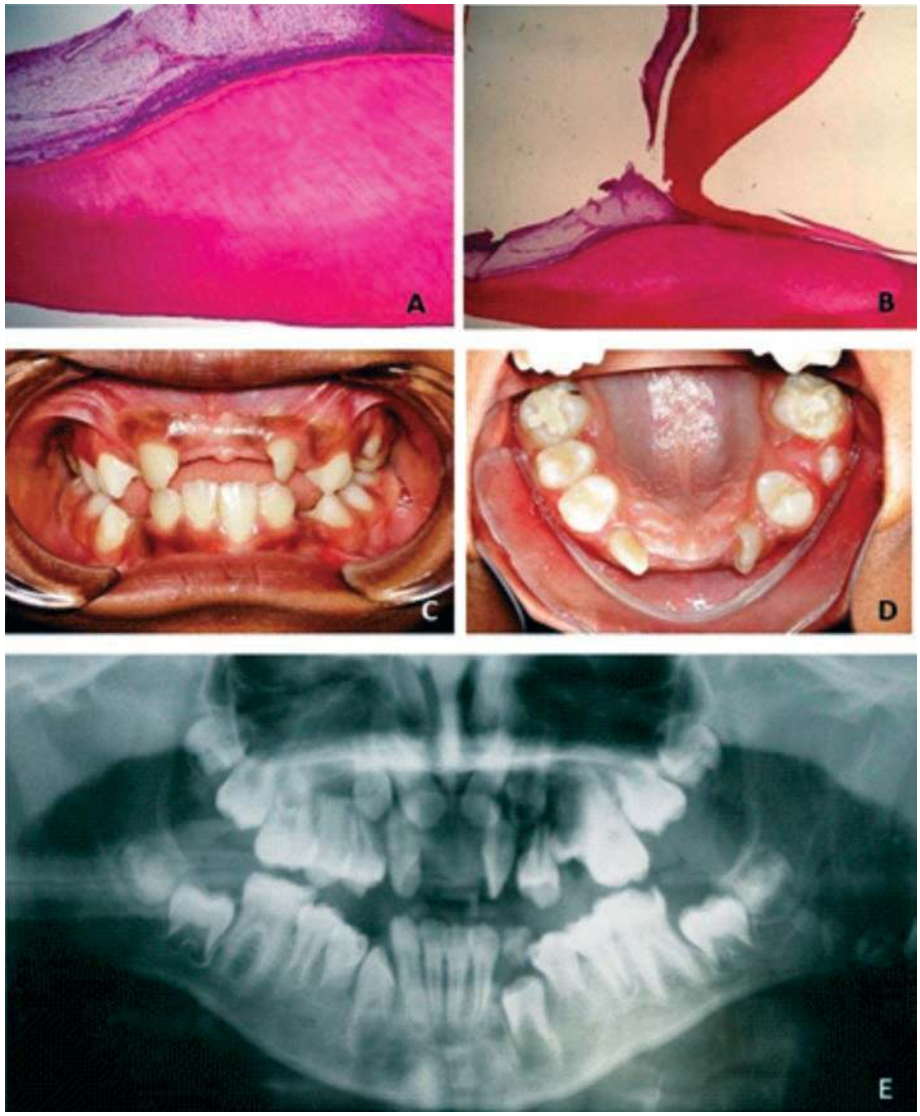


***Figure 3**: (A) Light microscopy 100x HE stains, descaling blade showing the tubular dentin and dentin pre-dental pulp; (B) 40X light microscopy HE stains, descaling blade showing the tubular dentin and dentin pre-dental pulp; (C) Intra-oral findings presenting normality; (D) Intra-oral findings presenting normality;(E) Panoramic postoperative image after 1 month and 15 days during follow-up queries.*

With clinical and imaging diagnosis compatible with odontoma compounds, we carried out the planning of the treatment. We decided for surgical removal, under general anesthesia with intubation. The surgical protocol consisted of extra and intraoral antisepsis with 2% chlorhexidine gluconate. A buccal access was made, after the removal of the primary elements. We performed the Newman incision modified type, two relaxant incisions extending between elements 13 and 23. The mucoperiosteal flap folding apical to the odontoma presented equidistant crowns of elements 11 and 21, not favoring palatal access for the removal. Ostectomy was performed with surgical spherical drill number 6 with micromotor and straight piece, enabling access to both odontomas, which were removed with the aid of curved and straight lifts.

The bony window was curetted and irrigated with 0.9% saline solution. The flap was repositioned, and sutures performed with simple isolated spots (Figure 2). The patient was instructed about the postoperative care and treated with antibiotic, analgesic, anti-inflammatory and targeted hygiene mouthwash without alcohol. There were no major complications in the postoperative period following the surgical procedure.

Odontomas were sent for histopathologic examination at the University Center CESMAC and the primary teeth were extracted, reporting that macroscopic bone fragments had the same oval shapes, lobulated, of hard consistency and whitish; the microscopy histological sections revealed fragments of dental structures, such as dentin and pulp, which confirmed the histologic diagnosis of compound odontoma (Figures 3A and B).

Seven days after the odontomas surgical removal, there was favorable healing, and the suture was in position without signs of infection. The patient has been followed clinically and radiographically, showing no signs of recurrence and bone structures showing normal characteristics (Figure 3C, D and E). After 3 months, a CT scan for postoperative evaluation was performed, and it was possible to observe the movement of the permanent central incisors, to the operating space, where they occupied the odontomas place.

# DISCUSSION

In 1970, Andreasen[30] stated that the periapical region of deciduous incisors is separated from the bone crypt permanent successors by a thin connective tissue membrane. This membrane, however, is not resistant to root displacement of deciduous teeth, as in cases of traumatic injury. Hence, any trauma to temporary teeth can lead to odontogenesis disturbances in the permanent dentition. Therefore, less or more severe defects can be observed in the morphology of this dentition, both clinically and radiographically.

An intruded primary tooth is strongly related to damage to the permanent successors, as there is a high possibility of physical contact between the traumatized tooth and successor germs. The intrusive force is applied by moving the root of the primary tooth to the palate, by contacting the permanent follicle germ in development. [2,5-7,15,20-24]

One of the consequences that can be observed in the permanent teeth after trauma, particularly in intrusions in deciduous predecessors, is the formation of odontomas. Although their etiology is not yet fully elucidated, dental trauma is suggested to be responsible for their formation; the injury to deciduous root causes a change in odontogenesis germ-forming, causing fragmentation. [21,23, 25-27]

In the reported case, the 10-month old child, who was still in the early development of successor germs, fell from the cradle, causing teeth 51 and 61 to suffer severe intrusion. The earlier the stage of odontogenesis, the more severe the consequences for the teeth in formation are known to be.[25] This episode is believed to have accounted for causing these anomalies involving the successors. Thus, there is a direct relationship between the age at which the patient suffered the trauma, the type of trauma and the consequences for the permanent successor tooth.

Odontoma can be defined as an odontogenic tumor that consists of epithelial and mesenchymal cells.[20-26] According to Tommasi,[21] odontoma is classified into complex and compound. The complex one is formed by a spherical or oval dental tissue mass and is irregularly distributed. The compound one was defined as an injury in which all the dental tissue is shown in an orderly manner, with at least a surface anatomic similarity to normal teeth often presented in the form of denticles. [21,25-27]The effect of the compound odontoma corresponds to 67% of the cases, while the complex one has a prevalence of 33%. Both more often affect females, children and adolescents [21,25-27] and are more frequently located in the anterior maxillary region, involving central incisors, lateral and permanent canines. [7,15,21,25-27]

As previously reported, the clinical case is in line with several previous works: the compound odontoma type (most common), affected a female (9-year old) child and reached the anterior maxilla (permanent central incisors).The radiographic image of the pathognomonic compound odontoma consists of 2 or more denticles, which simulate small teeth as having a disordered conglomerate radiopaque areas mediated by the assembly being surrounded by a radiolucent area. [21,22,25-27] In panoramic radiography, we observed the presence of two opaque calcified masses in the anterior maxilla, which impacted the eruption of the permanent successors.

The presence of odontoma can cause great inconvenience, and highlight the problems related to interference with the teeth eruption process, slowing or preventing normal eruption movements. For these reasons, most authors recommend that once this anomaly is detected, it must be surgically removed. The treatment is its total surgical excision, with favorable prognosis, adequate bone repair, and rare cases of recurrence. [18,25-27,29]

In the reported case, the patient was taken to hospital for having the lesions removed. Odontomas were entirely removed. When the child first came to rehabilitation treatment, it featured several teeth rather compromised by caries. Orthodontic treatment also required applying orthodontic traction to teeth 11, 21, which were included. However, both teeth are now free of the mechanical obstacle that prevented their satisfactory eruptions.

Until the last radiographic and tomographic examinations, there were no complications and / or relapse. According to the tomographic reports, teeth 11 and 21 are included in oblique position with the crown positioned labially with open apex, showing the elements which are following their eruption axis. Due to the decrease of the arch perimeter conditioned by prolonged retention of the deciduous teeth, orthodontic harmony accompaniment to the return of arches and auxiliary eruption is required.

## Acknowledgments

This study would have been impossible without the support of the Faculty of Dentistry of University Center CESMAC.

## REFERENCES:

1.Joho JP, Marechaux SC. Trauma in the primary dentition: a clinical presentation. ASDC J Dent Child. 1980; 47(3): p. 167-174.
2.Andreasen JO, Andreasen FM. Textbook and color atlas of traumatic injuries to the teeth. 3ª Edn.Mosby, Copenhagen. 1994.
3.Walter LRF, Ferelle A, Issao M. Odontologia para o bebê: odontopediatria do nascimento aos 3 anos. São Paulo: Artes Médicas; 1997.
4.Cardoso M, Rocha MJC. Traumatized primary teeth in children assisted at the Federal University of Santa Catarina, Brazil. Dent Traumatol. 2002; 18(3): p. 129-133.
5.Fried I, Erickson P. Anterior tooth trauma in the primary dentition: incidence, classification, treatment, methods and sequelae: a review of the literature. ASDC J Dent Child. 1995; 62(4): p. 256-261.
6.Conti G, Franchi L, Camporesi M, Defraia E. Treatment protocol for the impaction of deciduous maxillary anterior teeth due to compound odontoma. Eur J Paediatr Dent 2012; 13: 337-41.
7.Andreasen JO, Ravn JJ. The effect of traumatic injuries to primary teeth on their permanent successors. II. A clinical and radiographic follow-up study of 213 teeth. Scand J Dent Res. 1971; 79(4): p. 284-294.
8.Bastone EB, Freer TJ, McNamara JR. Epidemiology of dental trauma: a review of the literature. Aust Dent J. 2000; 45(1): p. 2-9.
9.Cunha RF, Pugliesi DMC, Correa MG, Assuit DM. Early treatment of an intruded primary tooth: a case report. J Clin Pediatr Dent. 2001; 25(3): p. 199-202.
10.Cunha RF, Delbem AC, Vieira AEM, Pugliesi DMC. Treatment of a severe dental lateral luxation associated with extrusion in an 8-month-old baby: a conservative approach. Dent Traumatol. 2005; 21(1): p. 54-56.
11.Fried I, Erickson P, Schwartz S, Keenan K. Subluxation injuries of maxillary primary anterior teeth: epidemiology and prognosis of 207 traumatized teeth. Pediatr Dent. 1996; 18(2): p. 145-151.
12.Lombardi SM, Sheller B, Williams BJ. Diagnosis and treatment of dental trauma in a children's hospital. Pediatr Dent. 1998; 20(2): p. 112-120.
13.Mackie IC, Blinkhorn AS. Dental trauma: 1. General history, examination and management of trauma to the primary dentition. Dent Update. 1996; 23(2): p. 69-71.
14.Pugliesi DMC, Cunha RF, Delbem AC, Sundefeld MLMM. Influence of the type of dental trauma on the pulp vitality and the time elapsed until treatment: a study in patients aged 0-3 years. Dent Traumatol. 2004; 20(3): p. 139-42.
15.Van Gool AV. Injury to the permanent tooth germ after trauma to the deciduos predecessor. Oral Surg Oral Med Oral Pathol. 1973; 35(1): p. 2-12.
16.Bennett DT. Traumatised anterior teeth. Br Dent J. 1964; 116(1): p. 52-55.
17. Bardellini E, Amadori F, Pasini S, Majorana A. Dental Anomalies in Permanent Teeth after Trauma in Primary Dentition. The Journal of Clinical Pediatric Dentistry 2017; 41(1): 5-9.
18.Tekkesin MS, Tuna EB, Olgac, V, Aksakallý N, Alatlý C. Odontogenic lesions in a pediatric population: Review of the literature and presentation of 745 cases. International journal of pediatric otorhinolaryngology 2016; 86:196-199.
19. AmaralFreitas G, Brasileiro CB, Pereira de Araújo Zarzar PM, Ferreira FM. Rare dental developmental disturbance in primary and permanent teeth following trauma prior to tooth eruption: Case report. Dental Traumatology.2019; doi: 10.1111/edt.12500. [Epub ahead of print].
20.Amorim LFG, Estrela C, Costa LRRS. Effects of traumatic dental injuries to primary teeth on permanent teeth – a clinical follow-up study. Dent Traumatol 2011; 27: 117-121.
21.Tommasi, A. F. Diagnóstico em patologia bucal. 3.ed. São Paulo: Pancast, 1998. p. 664.
22.Küchler EC, Fidalgo TKS, Farinhas JA, Costa MC. Developmental dental alterations in permanent teeth after intrusion of the predecessors: clinical and microscopic evaluation. Dent Traumatol 2010; 26: p. 505-508.
23.Scerri E, Gatt G, Camilleri S, Mupparapu M. Morphologic and developmental disturbance of permanent teeth following trauma to primary dentition in a selected group of Maltese children. Quintessence International 2010; 41(9): p. 717-725.
24.Gondim JO, Giro EMA, Neto JJSM, Coldebella CR, Bolini PDA, Gaspar AMM. Sequelas em dentes permanentes após trauma nos predecessores decíduos e sua implicação clínica.RGO – Rev. Gaúcha Odontol., Porto Alegre 2011, v.59, suplemento O, p. 113-120.
25. Lenzi MM, Alexandria AK, Ferreira DM, Maia LC. Does trauma in the primary dentition cause sequel in permanent successors? A systematic review. Dent Traumatol. 2015; 31:79-88.
26. Costa VP, Goettems ML, Baldissera EZ, Bertoldi AD, Torriani DD.Clinical and radiographic sequelae to primary teeth affected by dental trauma: a 9-year retrospective study. Braz Oral Res. 2016;30(1). pii: S1806-83242016000100702.
27.Padmanabhan MY, Pandey RK, Aparana R. Erupted composite odontoma associated with malformed teeth – unusual dental aberrations following maxillofacial trauma. Rom J Morphol Embryol 2013, 54(4): p. 1153-1156.
28.Carvalho V, Jacomo DR, Campos V. Frequency of intrusive luxation in deciduous teeth and its effects. Dent Traumatol 2010; 26: p. 304-307.
29. Fang QG, Shi S, Sun CF. Odontogenic lesions in pediatric patients. J Craniofac Surg. 2014; 25(3):248-251.
30.Andreasen JO. Etiology and pathogenesis of traumatic dental injuries: a clinical study of 1298 cases. Scand J Dent Res. 1970; 78(4): 329-342.

# DENTOMAXILLOFACIAL SEQUELAE RESULTING FROM A CHEMORADIOTHERAPY AGAINST RHABDOMYOSARCOMA: 6-YEAR FOLLOW-UP

Adilis Kalina **Alexandria**[1,3*], Patricia Nivoloni **Tannure**[2], Camila **Nassur**[3], Gloria Fernanda Barbosa de Araújo **Castro**[3], Ivete Pomarico Ribeiro de **Souza**[3]

[1]Department of Preventive and Community Dentistry, Rio de Janeiro State University (UERJ), Rio de Janeiro, RJ, Brazil
[2]Veiga de Almeida University (UVA), São Leopoldo Mandic University, Rio de Janeiro, RJ, Brazil
[3]Department of Pediatric Dentistry and Orthodontics, Faculty of Dentistry, Federal University of Rio de Janeiro (UFRJ), Rio de Janeiro, RJ, Brazil

**Palavras-chave:** Rabdomiossarcoma. Quimioterapia de Manutenção. Protocolos Antineoplásicos.

**RESUMO**

**Introdução**: O rabdomiossarcoma é uma neoplasia maligna agressiva de tecido mole de células mesenquimais imaturas tratadas com cirurgia e quimioradioterapia. Os efeitos da quimioradioterapia na cabeça induzem uma série de sequelas na cavidade oral e no desenvolvimento do crescimento. **Objetivo**: Relatar o caso de uma criança em tratamento de rabdomiossarcoma cujos efeitos no desenvolvimento dento-maxilofacial foram cuidados a fim de salvaguardar a qualidade de vida do paciente. **Relato de caso**: Descreve um caso de defeitos dento-maxilo-faciais graves resultante de quimioradioterapia para rabdomiossarcoma embrionário em uma criança, bem como o manejo realizado. Clinicamente, a paciente apresentava gengivite, severa mobilidade dos dentes permanentes, hipossalivação, mucosite e trismo severo. Os exames radiográficos mostraram interrupção da formação radicular de todos os dentes permanentes e retenção dos dentes decíduos. Análises cefalométricas revelaram hipoplasia mandibular e maxilar. **Resultados**: Foi realizada a extração dos dentes decíduos retidos associado a um programa profilático e uso de saliva artificial devido à hipossalivação, a fim de melhorar a qualidade de vida do paciente. Após 6 anos de acompanhamento odontológico e fonoaudiológico, sua abertura bucal aumentou e as dificuldades de mastigação e deglutição diminuíram, não há gengivite ou mucosite e ela permaneceu livre de doenças recorrentes ou metastáticas 11 anos após o diagnóstico inicial. **Conclusão**: Nosso relato enfatiza a importância do tratamento odontológico com um programa de prevenção e acompanhamento para pacientes submetidos a terapias antineoplásicas.

**Keywords:** Rhabdomyosarcoma. Maintenance Chemotherapy. Antineoplastic Protocols.

**ABSTRACT**

**Introduction**: Rhabdomyosarcoma is an aggressive malignant soft tissue neoplasm of immature mesenchymal cells treated with surgery and chemoradiotherapy. The effects of chemoradiotherapy in head induce a series of sequelae on oral cavity and growth development. **Objectives**: Report the case of a child undergoing treatment for rhabdomyosarcoma whose effects on the dento-maxillofacial development were cared for in order to safe guard the patient's quality of life. **Case report**: Describes a case of severe dento-maxillofacial defects resulting from chemoradiation therapy for embryonal rhabdomyosarcoma in a child as well as the dental management performed. Clinically, the patient had gingivitis, severe mobility of permanent teeth, hyposalivation, mucositis and severe trismus. The radiologic exams showed interruption of root formation of all permanent teeth and over-retention of primary teeth. Cephalometric analyses revealed mandibular and maxillary hypoplasia. **Results**: Was made extraction of the over-retained primary teeth associated with a prophylactic program and use of artificial saliva due to hyposalivation in order to improve the quality of life of the patient. After 6 years of dental and phonoaudiologic follow-up her oral opening has increased and chewing and swallowing difficulties have decreased, there is no gingivitis or mucositis and she has remained free of recurrent or metastatic diseases 11 years after the initial diagnosis. **Conclusion**: Our report emphasizes the importance of dental treatment with a program of prevention and follow-up for patients undergoing anticancer therapies.

Submitted: April 18, 2019
Modification: July 22, 2019
Accepted: July 24, 2019

***Correspondence to:**
Adilis Kalina Alexandria
Address: Departamento de Odontologia Preventiva e Comunitária, UFRJ, Pavilhão Mario Franco Barroso 2º andar, Rio de Janeiro, RJ, Brasil.
Zip code: 21941-971.
Telephone number: +55 (21) 3938-2101
E-mail: adilis.alexandria@gmail.com.br

## INTRODUCTION

Rhabdomyosarcoma (RMS) is an aggressive malignant soft tissue neoplasm of immature mesenchymal cells. [1-3] It is the most common soft-tissue sarcoma of childhood and adolescence involving the head and neck, [1,3] with prevalence of 35–40% of all cases. [3] The signs and symptoms are usually non-specific and depend on both location and size [1,4] [Soule et al., 1968; Chen et al., 1995]. Treatment consists of chemotherapy (CT) and radiotherapy (RT) with or without surgery. [1,5,6] The effects of chemo-radiotherapy induces a series of tong-term side effects on teeth and growth development, as well as other adverse sequelae in the oral cavity.[7-9] The severity of these abnormalities depends on the stage of dental development and the radiation dose delivered.[6,7] This report presents the case of a child undergoing treatment for rhabdomyosarcoma whose effects on the dento-maxillofacial development were cared for in order to safe guard the patient's quality of life.

## CASE REPORT

An 8 year-old girl was referred to the Pediatric Dental Clinic at the Universidade Federal do Rio de Janeiro, Brazil, for dental treatment due to hyposalivation and retention of primary teeth. Medical history revealed that the patient was diagnosed for RMS involving the head and neck region when she was 3 years old. On that occasion the patient was submitted to a combined multi-drug chemotherapy and the resection of the tumor mass. Also 14 weeks after the surgery the patient received complementary radiotherapy (4500 cGy) over a 5-week period.

The child had an ischemic stroke during the chemo-radiotherapy treatment and developed left paresthesia. She also developed hypothyroidism and since then receives thyroid hormone supplements and anticonvulsant drugs. Also, she took growth hormone supplements for 4 years but stopped as no positive results were observed.

The extra and intraoral examinations revealed a marked micrognathia, a Class II facial profile with considerable loss of vertical dimension. The face appeared triangular or V-shaped but symmetric, the profile was convex and retrognathic with a pronounced nose (Figure 1a and 1b). The clinical intraoral exam showed that she was in mixed dentition with poor oral hygiene, gingivitis, hyposalivation, mucositis and severe trismus with a constricted oral opening, over-retained primary teeth, severe mobility of permanent teeth and dental crowding (Figure 1c and 1d). The cephalometric analysis confirmed maxillary and mandibular hypoplasia for the patient's age (Figure 2a). Orthopantographic radiograph showed interruption of root formation of all permanent teeth, and absence of tooth germs of the second permanent premolars (Figure 2b).

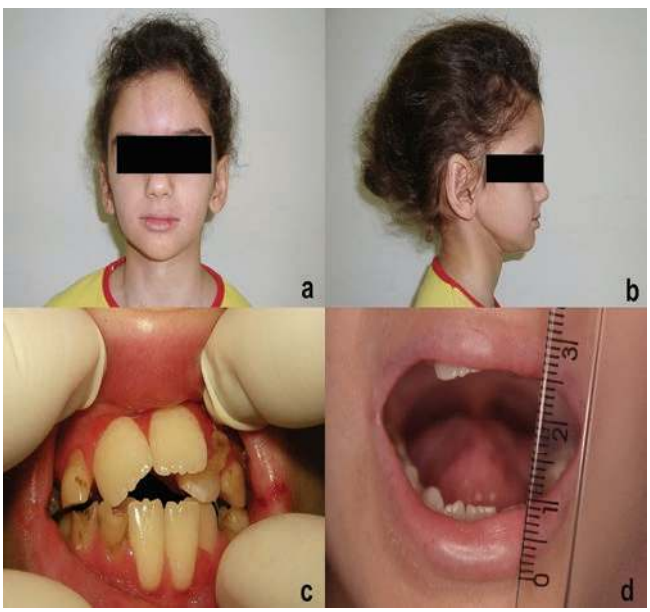


***Figure 1***: *(a) Frontal view shows triangular aspect of face with a pronounced nose, and a marked micrognathia. (b) Lateral view shows convex profile and retrognathic. (c) Intra-oral view shows poor oral hygiene, gingivitis, primary teeth over-retained and mucositis. (d) Severe trismus with constricted oral opening.*

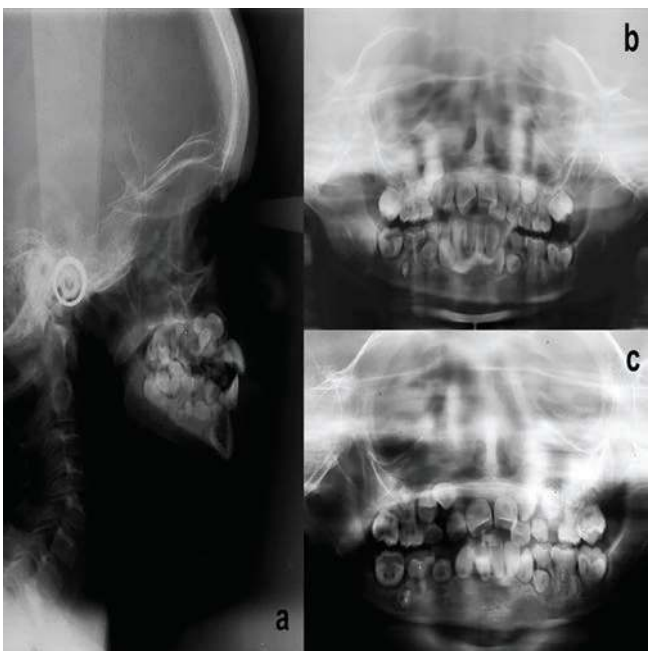


***Figure 2:*** *(a) Orthopantographics radiographs showing over-retention of primary teeth, dental root shortening of all permanent teeth and retarded tooth development. (b) Lateral skull roentgenogram with cephalometric tracing shows mandibular and maxillary hypoplasia when the patient was 8 years old. (c) Present day orthopantomographic radiograph of the patient at 14 years old showing dental root shortening of all permanent teeth, retarded tooth development and tight space for the teeth in the arches.*

The treatment plan called for extractions of over-retained primary teeth after medical approval, and, regular use of artificial saliva due to hyposalivation. The prophylactic program consisted of dental prophylaxis with fluoride gel applications every 6 months, dental hygiene instructions, rinsing with chlorhexidine for 14 days due to gingivitis, nutritional counseling, and six-monthly follow-ups. The patient's doctor gave his medical opinion allowing teeth extractions and other dental procedures. Also, the patient was referred to phonoaudiologic treatment due to severe trismus and deficient communication.

The primary teeth extracted were: 54, 53, 52, 62, 64, 73, 83 and 84. Extraction was necessary as these elements were disabled and many were only root fragments. Extraction was relatively easy as the teeth were only retained in mucosa. Due to the absence of permanent roots and the severe mobility of all permanent teeth, the child's parents were informed about the need for prosthetic rehabilitation treatment in the future.

Now, 6 years after she was first was referred to the UFRJ Pediatric Dental Clinic, she is 14 years old and she has already lost the permanent incisive lower right tooth due to extreme mobility. Orthopantographic radiograph show the absence of tooth (Figure 2c).

After 6 years of dental and phonoaudiologic follow-up her oral opening has increased and chewing and swallowing difficulties have decreased. Her oral hygiene has improved significantly; there is no gingivitis or mucositis. Also she has remained free of recurrent or metastatic diseases 11 years after the initial diagnosis.

## DISCUSSION

The clinical form of RMS may vary from a small cutaneous nodule on the face to an extensive fast growing facial swelling [1] associated with pain, trismus, paresthesia, facial palsy, aural or nasal discharge. [8] RMS treatment consists of chemotherapy, radiotherapy and surgery. [1, 6] However multi-modality therapy for tumors in the head and neck region has a significant effect on maxillofacial skeletal growth, dental development, and the whole ecologic system of the oral cavity. [7, 10]

Some of the side effects of chemo-radiation therapy include xerostomia, mucositis, candidiasis, trismus, delayed eruption of teeth, retarded tooth and bone development, partial anodontia, alterations of root development, radiation caries, discoloration of teeth, osteoradionecrosis, loss of taste and soft-tissue necrosis. [8, 9] Many of these side effects were present in our patient.

Growth failure of the facial bones in children due to radiation therapy for head and neck tumors has been reported in the literature. [10] The face of patient appeared triangular but symmetric, the profile was convex and she presented retrognathic. Our cephalometric analysis showed that the maxilla, mandible, and the anterior portion of the skull base were deficient in size.

General body growth of the patient was also affected, probably due to the effect of radiation on the hypothalamus and pituitary glands. Growth disturbances after chemotherapy are often temporary, but radiotherapy of cranial, spinal, and abdominal areas can cause permanent and progressive growth disturbances. [11] Radiotherapy may affect bone growth directly or act secondarily, causing hypothalamic-pituitary axis damage. [10, 11] Growth hormone supplements were prescribed, but no change was observed in facial and general growth, so, after 4 years, the use of these hormones was discontinued by the physicians.

RT in head and neck area can reduce salivary flow rate, pH, and buffering capacity, and saliva turns more viscous. Qualitative and quantitative changes could compromise several protective functions of saliva, impair oral functions such as speech and swallowing, predisposing caries and gingivitis. [9] In some cases, the salivary secretion rate decreases for 3 to 6 months after CRT, but recovers to the normal level within one year; however high doses and time of exposition of RT can cause a long-term reduction in the salivary secretion rate. [12] As our patient presented gingivitis and hyposalivation, artificial saliva was prescribed and a prophylactic program was carried out to prevent caries and gingivitis. Nowadays, she doesn't have any caries or white-spot lesions or gingivitis.

Anticancer therapy can cause a spectrum of side effects from mild to severe tooth alterations such as enamel hypoplasia to tooth agenesis. These alterations may vary depending on when the therapy is given in relation to the tooth developmental stage. [5, 7, 9] Our patient presented permanent root agenesis, retardation of tooth development, impacted primary teeth and absence of tooth germs of the second permanent premolars. Due to the permanent interruption of root formation, there was a severe mobility of the permanent teeth and because of micrognathia severe crowding making hygiene and tooth positioning difficult.

Kanatas *et al.* [13] declared that invasive procedures such as tooth extraction should be avoided even several years after radiation therapy for head and neck because of the high risk of resulting in osteoradionecrosis. However, the extractions of primary teeth were necessary in our case and were performed because the teeth were retained only in mucosa; also the extractions were carried out more than 5 years after the radiotherapy treatment. The child was referred for phonoaudiologic treatment because of severe

trismus and deficient communication. Her oral opening increased significantly after phonoaudiologic treatment. After extractions and a prophylactic program her chewing and swallowing difficulties decreased, and her oral hygiene improved significantly; there were no more signs of gingivitis or mucositis. Monitoring the patient every six months has been important to maintain oral health and maintenance of the teeth in the mouth despite the severe mobility, and overall the patient is in good general and oral health.

The literature has shown that after radiotherapy treatment in children some teeth continue a slow eruption even though root formation has completely ceased. These authors suggest that eruption is not dependent upon development of the root or periodontal ligament. [7,8]

The treatment of our patient was planned after medical approval and prioritized the main difficulties that the child had. Chemo-radiotherapy has increased the survival of patients with head and neck cancer, although it can cause severe oral-health problems.

## CONCLUSION

It is important that patients who undergo anticancer therapies are encouraged to carry out dental treatment in order to establish not only treatment, but also a well-defined program of prevention and follow-up for many years. This should be a key element of dental health maintenance after anticancer therapies.

## REFERENCES

1. Gillespie MB, Marshall DT, Day TA, Mitchell AO, White DR, Barredo JC. Pediatric rhabdomyosarcoma of the head and neck. Curr Treat Options On. 2006;7: 13-22.
2. Raney RB, Maurer HM, Anderson JR, et al. The Intergroup Rhabdomyosarcoma Study Group (IRSG): Major Lessons From the IRS-I Through IRS-IV Studies as Background for the Current IRS-V Treatment Protocols. Sarcoma. 2001;5: 9-15.
3. Alaraudanjoki V, Laitala ML, Tjaderhane L, Pesonen P, Lussi A, Anttonen V. Association of erosive tooth wear and dental caries in Northern Finland Birth Cohort 1966 - an epidemiological cross-sectional study. BMC Oral Health. 2016;17: 6.
4. Radzikowska J, Kukwa W, Kukwa A, et al. Management of pediatric head and neck rhabdomyosarcoma: A case-series of 36 patients. Oncol Lett. 2016;12: 3555-3562.
5. Paulino AC, Simon JH, Zhen W, Wen BC. Long-term effects in children treated with radiotherapy for head and neck rhabdomyosarcoma. Int J Radiat Oncol Biol Phys. 2000;48: 1489–1495.
6. Stevens MC, Rey A, Bouvet N, et al. Treatment of nonmetastatic rhabdomyosarcoma in childhood and adolescence: third study of the International Society of Paediatric Oncology. J Clin Oncol. 2005;23: 2618-2628.
7. Nasman M, Forsberg CM, Dahllof G. Long-term dental development in children after treatment for malignant disease. Eur J Orthod. 1997;19: 151-159.
8. Shetty K, Tuft H. Dental management of the pediatric post radiation therapy-rhabdomyosarcoma patient: Case reports and review of literature. Oral Oncol. 2005;41: 242-248.
9. Vissink A, Jansma J, Spijkervet FK, Burlage FR, Coppes RP. Oral sequelae of head and neck radiotherapy. Crit Rev Oral Biol Med. 2003;14: 199-212.
10. Kaste S, Hopkins K, Tenn M. Micrognathia after radiation therapy for childhood facial tumors. Oral Surg Oral Med Oral Pathol Oral Radiol Endod. 1994;77: 95-99.
11. Moell C, Marky I, Hovi L, et al. Cerebral irradiation causes blunted pubertal growth in girls treated for acute leukemia. Med Pediatr Oncol. 1994;22: 375-379.
12. Bagesund M, Richter S, Agren B, Ringdén O, Dahllöf G. Scintigraphic study of the major salivary glands in pediatric bone marrow transplant recipients. BMT. 2000;26: 775-779.
13. Kanatas AN, Rogers SN, Martin MV. A practical guide for patients undergoing exodontia following radiotherapy to the oral cavity. Dent Update. 2002;29: 498-503.

# UNUSUAL CASE OF ANKYLOGLOSSIA RECURRENCE AFTER FRENECTOMY IN A CHILD WITH CEREBRAL PALSY

Fernanda Michel Tavares **Canto**[1], Aline dos Santos **Letieri**[1], Michelle **Agostini**[2], Oswaldo de Castro Costa **Neto**[3], Gloria Fernanda Barbosa de Araújo **Castro**[1*]

[1]Department of Pediatric Dentistry and Orthodontics, School of Dentistry, Universidade Federal do Rio de Janeiro, Rio de Janeiro, Brazil.
[2]Department of Oral Diagnosis and Pathology, School of Dentistry, Universidade Federal do Rio de Janeiro, Rio de Janeiro, Brazil.
[3]Department of Dental Clinic, School of Dentistry, Universidade Federal do Rio de Janeiro, Rio de Janeiro, Brazil.

**Palavras-chave:** Anquiloglossia. Pessoas com Deficiência. Freio Lingual.

**RESUMO**

**Introdução**: A frenectomia é o tratamento mais indicado para os casos de anquiloglossia em crianças e jovens, sendo a recorrência extremamente rara. **Objetivo**: O objetivo é relatar o caso incomum de um menino de 8 anos, com paralisia cerebral, apresentando recidiva de anquiloglossia dois anos após a realização de frenectomia lingual**. Relato de caso:** Ao exame físico, em consulta de revisão, 2 anos após uma frenectomia lingual observou-se freio lingual levemente elástico, curto e aderido, presença de formato de coração na língua, restrição severa dos movimentos laterais e superiores, além de dificuldades na fala e deglutição. Uma nova frenectomia foi realizada após dois anos da primeira frenectomia , sob anestesia local, restaurando a mobilidade lingual. O paciente foi acompanhado periodicamente junto com a fonoaudiologia e após 2 anos da segunda cirurgia, a inserção firme do freio e a continuidade do aspecto bífido da língua foram novamente verificadas, porém, os movimentos da língua e as funções orais mantiveram-se satisfatórios. O paciente continuará a ser acompanhado periodicamente e, se houver alterações nas funções orais, uma nova intervenção será realizada. **Conclusão:** É fundamental o diagnóstico e tratamento multidisciplinar da anquiloglossia, além da necessidade de acompanhamento clínico periódico para identificar possíveis casos de recidiva, que, embora raros, podem ocorrer.

**Keywords:** Ankyloglossia. Disabled Persons. Lingual Frenum.

**ABSTRACT**

**Introduction:** Frenectomy is the most indicated treatment for ankyloglossia in children and adolescents, with recurrence being extremely rare. **Objective**: Here, we report the unusual case of an 8-year-old boy with cerebral palsy presenting recurrence of ankyloglossia 2 years after undergoing lingual frenectomy. **Case report**: On physicalexamination, in a follow-up, 2 years after a lingual frenectomy, we observed a slightly elastic, short and adhered lingual frenulum and the presence of a heart-shaped tongue, with severe restriction of lateral and superior movements, and difficulties in speech and swallowing. A new frenectomy was performed under local anesthesia, restoring lingual mobility. The patient has been followed-up periodically and has undergone speech therapy; 2 years after the second surgery, firm insertion of the frenulum and the continuity of the bifid aspect of the tongue have been again verified, but the tongue movements and oral functions remain satisfactory. The patient will continue to be followed periodically and a new intervention will be performed if there are changes in oral functions. **Conclusion**: Beyond the need forperiodic clinical follow-up, the diagnosis and multidisciplinary treatment of ankyloglossia are fundamental for identifying possible cases of recurrence, which, although rare, can occur.

Submitted: March 20, 2019
Modification: May 6, 2019
Accepted: May 9, 2019

***Correspondence to**:
Gloria Fernanda Barbosa de Araújo Castro
Address: Rua Rodolpho Paulo Rocco, 325 - Cidade Universitária. Faculdade de Odontologia, Departamento de Odontopediatria e Ortodontia. Rio de Janeiro, RJ, Brazil.
Zip code: 21941-913.
Telephone number: +55 (21) 39382098.
E-mail: gfbacastro@yahoo.com.br

## INTRODUCTION

Ankyloglossia, or tongue-tie, is a congenital anomaly where a short lingual frenulum interferes with normal movement of the tongue, and the insertion of the frenulum may be anterior to the inferior alveolar crest. [1,2] Its prevalence is estimated at less than 1% to 10%, with a male to female ratio of 2.6:1.0 in newborns. [3,4] The wide variation of the prevalence data between studies may be associated with the difficulty in accessing dental services, especially in some populations, and a lack of diagnosis by dentists, leading to possible under-reporting of prevalence. [5]

There are several criteria for diagnosing ankyloglossia, such as the presence of a bifid aspect of the tongue during the protrusion movement (presenting a heart shape), the presence of restrictions in relation to the amplitude of tongue movements, and/or the impossibility of touching the palate with the tip of the tongue. [6, 7] Some treatments, such as clinical monitoring, preservation and frenotomy can be performed until more invasive surgical procedures such as frenectomy can be performed. Frenectomy consists of complete removal of the frenulum and is most commonly performed in children and adolescents because of better understanding and acceptance of the procedure. Frenectomy has a high success rate, with few recurrences postoperatively. [8]

In the present paper, we report an unusual case of an 8-year-old male patient who presented with recurrence of ankyloglossia 2 years after undergoing frenectomy.

## CASE REPORT

An 8-year-old boy with cerebral palsy was referred by his speech-language pathologist with the complaint of difficulty in phonation and deglutition as a result of ankylosis recurrence 2 years after undergoing lingual frenectomy. Analysis of the dental records of the previous surgical procedure verified that a frenectomy had been performed 2 years ago and that the patient had history of collaborative behavior despite mild cognitive deficit. We observed that the patient did not attend the periodic follow-up consultations after the surgical procedure.

Clinical examination verified the poor mobility and bifid aspect (heart-shaped appearance) of the tongue when lifted. We also observed little tongue elasticity, lingual frenulum length > 1 cm, appropriate lateralization movement of the body of the tongue, anterior movement with moderate restriction, and impossibility of tongue tip touching the lingual surface of the maxillary incisors (Figure 1). After evaluation by the bucomaxilofacial surgeon, we decided to perform another frenectomy. The surgery was performed, with the mother's consent, under local anesthesia (2% lidocaine with epinephrine 1:100.000) and with the pediatric dentists' assistance for better behavior control. Resection of the lingual frenulum (complete removal) was performed and a simple catgut 5-0 suture was used to immobilize the tongue. Immediately after the surgery, we observed the re-establishment of tongue mobility (Figure 2).

Seven days after the frenectomy, the patient returned for a clinical follow-up of his postoperative condition, confirming satisfactory healing. Subsequently, he was clinically re-evaluated after 15 days and 1 and 3 months; and in all of these appointments were verified satisfactory clinical evolution of the case. Since then, he has been followed-up every 6 months in partnership with speech therapy. After 2 years of follow-up, we have observed that the tongue is functionally adequate, with satisfactory lateral and anterior movements, where the tip of the tongue can touch the lingual surface of the maxillary incisors. In addition, phonation and deglutition have remained satisfactory. Besides that, firmer insertion of the lingual frenulum has been verified, and the tongue tip still presents the bifid aspect when lifted (Figure 3). However, new surgical intervention is not needed at the moment. The patient will continue to be followed-up, and if new surgical treatment is needed, will be carried out a multidisciplinarily planning.

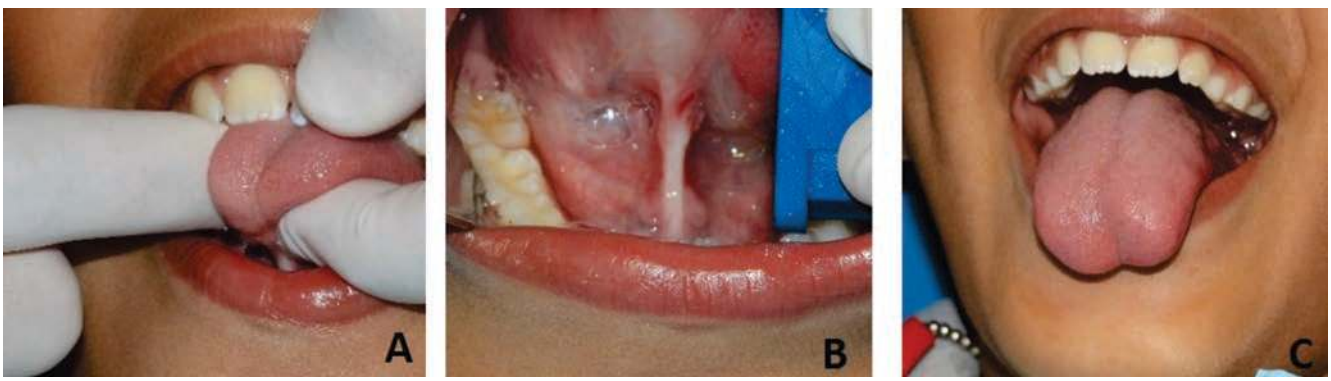


***Figure 1***: *A: Intraoral photography of initial clinical examination showing restriction of the superior movements of the tongue, whose tip cannot rest on the lingual surface of the maxillary incisors. B: A less elastic lingual frenulum inserted from the base of the tongue to the crest of the alveolar ridge. C: The bifid appearance, besides the restricted anterior movements.*

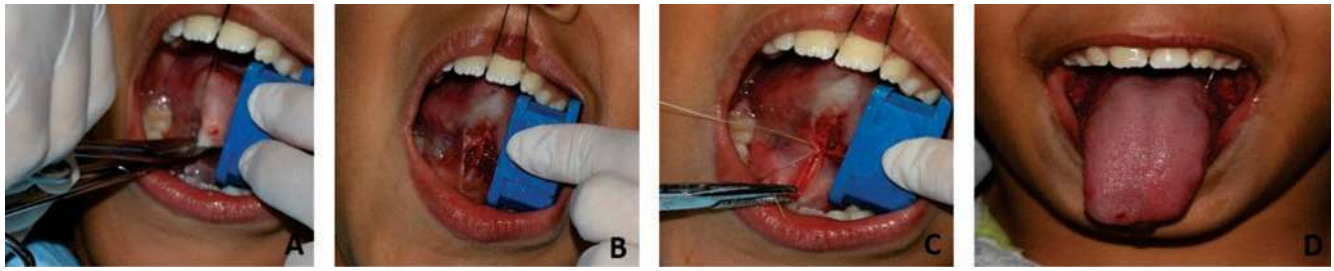


***Figure 2***: *A, B: Images of the surgical procedure, showing debridement and complete resection of the lingual frenulum and release of the tongue movements. C: Local suture performed in the area at the end of the surgery. D: Intraoral photography showing the re-established lingual mobility just after the second frenectomy.*




***Figure 3***: (A) *Firm insertion of the lingual frenulum verified 2 years after the second frenectomy.* (B and C) *besides the maintenance of the bifid aspect of the tongue, lingual movements and oral functions (deglutition and phonation) were maintained satisfactorily.*

## DISCUSSION

Ankyloglossia is a congenital anomaly that causes speech and feeding difficulties and is not correlated with any other specific cause. There are some standards for recognizing and diagnosing ankyloglossia, such as the appearance of the tongue when lifted, frenulum elasticity, lingual frenulum length when the tongue is lifted, lingual frenulum attachment to the tongue, lingual frenulum attachment to the inferior alveolar ridge, lateralization, and tongue lifting. [1,9]

When ankyloglossia is diagnosed, the treatment options include frenotomy and frenectomy. [1,10] In frenotomy, the frenulum is only superficially cut, and it is even performed only with topical anesthesia. It is used most often in babies, as it is less invasive and faster. Frenectomy is a more invasive surgical procedure that requires local anesthesia and consists of complete debridement of the lingual frenulum, whose insertion must be removed from the base of the mandibular bone. Thus, the choice of a less invasive treatment, such as frenotomy, may cause relapses, as the frenulum can have several insertions, while the recurrence of ankyloglossia after frenectomy is rarer. [1,8,10,11]

In the present case, the first-choice treatment was frenectomy, but even then, the patient returned after 2 years with the lingual frenulum well-inserted in the inferior alveolar crest, besides problems with phonation, indicating the need for new surgical intervention. In the searched literature, we found no other reports of recurrence of ankyloglossia after frenectomy.

Different factors are related to the healing process of wounds in the oral soft tissues. [12] It is suggested that the relapse observed in the present case is related to an individual characteristic of the patient, with the formation of a scar tissue that is more fibrous than normally observed. It could be the reason that, even after the second procedure, the patient presented a very fibrous insertion of the lingual frenulum in the postoperative follow-up period, revealing an individual physiological problem. Despite this, no need for new interventions has been observed to date.

In addition, to avoid recurrence after frenectomy, it is important that the patient perform myofunctional tongue rehabilitation exercises with a speech therapist, as observed in many other successful cases. [13] In the present case, the patient also underwent multi-professional treatment with a speech therapist to complement the surgical treatment and improve the prognosis. The importance of maintaining this treatment was explained to his mother.

The dental management of children, especially when they are patients with special needs, is challenging. In this context, behavioral control is one of the main issues in enabling adequate management of the patient and for performing the necessary procedures effectively. [14,15] In the present case, multidisciplinary care with a dental surgeon and pediatric dentists allowed us to perform the surgical treatment without requiring sedation or general anesthesia. It should be noted that this multidisciplinary and multi-professional collaboration was of fundamental importance

for ensuring the most adequate planning, efficient management, and the best prognosis for the patient.

We can conclude that, after the 2-year follow-up period, the multidisciplinary and multi-professional treatment, including a new lingual frenectomy and speech therapy treatment, facilitated the successful management of a case of ankyloglossia recurrence in a child with cerebral palsy.

## ACKNOWLEDGMENTS

This study was partly financed by the Coordenação de Aperfeiçoamento de Pessoal de Nível Superior Brasil (CAPES – DS) with finance code 001.

## REFERENCES

1. Manfro A, Manfro R, Bortoluzzi M. Surgical treatment of ankyloglossia in babies—case report. Int J Oral Maxillofac Surg. 2010;3911:1130-2.
2. Pompéia LE, Ilinsky RS, Ortolani CLF, Faltin Júnior K. ankyloglossia and its influence on growth and development of the stomatognathic system. Rev Paul Pediatr. 2017;352:216-21.
3. Heller J, Gabbay J, O'hara C, Heller M, Bradley JP. Improved ankyloglossia correction with four-flap Z-frenuloplasty. Ann Plast Surg. 2005;546:623-8.
4. Messner AH, Lalakea ML, Aby J, Macmahon J, Bair E. Ankyloglossia: incidence and associated feeding difficulties. Arch Otolaryngol Head Neck Surg. 2000;1261:36-9.
5. Becker S, Mendez M. Ankyloglossia. 2018.
6. Junqueira MA, Cunha NNO, SILVA C, Lucas L, Araújo LB, Moretti ABS, et al. Surgical techniques for the treatment of ankyloglossia in children: a case series. J Appl Oral Sci. 2014;223:241-8.
7. Fleiss PM, Burger M, Ramkumar H, Carrington P. Ankyloglossia: a cause of breastfeeding problems? J Hum Lact. 1990;63:128-9.
8. Hong P, Lago D, Seargeant J, Pellman L, Magit AE, Pransky SM. Defining ankyloglossia: a case series of anterior and posterior tongue ties. Int J Pediatr Otorhinolaryngol. 2010;749:1003-6.
9. Hazelbaker AK. The assessment tool for lingual frenulum function (ATLFF): Use in a lactation consultant private practice: Pacific Oaks College; 1993.
10. Walsh J, Tunkel D. Diagnosis and treatment of ankyloglossia in newborns and infants: a review. JAMA Otolaryngol Head Neck Surg. 2017;14310:1032-9.
11. Masaitis NS, Kaempf JW. Developing a frenotomy policy at one medical center: a case study approach. J Hum Lact. 1996;123:229-32.
12. Larjava H, Wiebe C, Gallant-Behm, C, Hart DA, Heino, J, & Hakkinen L. Exploring scarless healing of oral soft tissues. *J Can Dent Assoc*. 2011; *77*, b18.
13. Ferrés-Amat E, Pastor-Vera T, Ferrés-Amat E, Mareque-Bueno J, Prats-Armengol J, Ferrés-Padró E. Multidisciplinary management of ankyloglossia in childhood. Treatment of 101 cases. A protocol. Med Oral Patol Oral Cir Bucal. 2016;211:e39.
14. Uman LS, Chambers CT, McGrath PJ, Kisely S. Psychological interventions for needle-related procedural pain and distress in children and adolescents. Cochrane Database Syst Rev. 2006.
15. Singh H, Rehman R, Kadtane S, Dalai DR, Jain CD. Techniques for the behaviors management in pediatric dentistry. Int J Sci Stud. 2014;27:269-72.

# OROFACIAL FINDINGS AND DENTAL CARE MANAGEMENT IN A PATIENT WITH ROBINOW SYNDROME

Marina Fernandes **Sena**,[1] Paôla Caroline da Silva **Mira**,[1] Thais Tedeschi dos **Santos**,[1] Carolina Paes **Torres,**[1] Francisco Wanderley Garcia **Paula-Silva**,[1]* Fábio Lourenço **Romano**,[1] Sandra Maria Garcia da **Silveira**,[1] Karina. Mayra de Queiroz **Brito**,[1] Alexandra Mussolino de **Queiroz**,[1]

[1]Department of Children's Clinic, School of Pediatric Dentistry of Ribeirão Preto-USP, Ribeirão Preto, SP, Brazil.

**Palavras-chave:** Síndrome de Robinow. Crianças com Deficiência. Atendimento Odontológico.

**RESUMO**

**Introdução**: A síndrome de Robinow é uma doença genética rara caracterizada por baixa estatura, dismorfismos faciais e anomalias orodentais, genitália subdesenvolvida e falhas no desenvolvimento esquelético. **Relato de Caso:** Uma paciente de 6 anos com Síndrome de Robinow foi encaminhada ao Centro de Formação de Recursos Humanos Especializado no Atendimento Odontológicode Pacientes com Necessidades Especiais (Ribeirão Preto, São Paulo, Brasil).Na investigação da história médica e ao exame clínico foram observados baixa estatura, dismorfismo facial e genitália hipoplásica. Os achados orofaciais mostraram retrognatismo, hemangioma de linha média de aproximadamente 1 cm de largura com bordas voltadas para cima, língua bífida, anquiloglossia, hipertrofia gengival geral, mordida profunda e apinhamento dentário leve. A anormalidade cardíaca e o atraso no desenvolvimento neuromotor demandaram cuidados individualizados. O tratamento odontológico consistiu em procedimentos preventivos e restauradores para adequar a condição de saúde bucal da paciente. Além disso, foi realizada avaliação ortodôntica e planejamento do tratamento. A paciente está em acompanhamento há seis anos. **Conclusão**: Anomalias orofaciais e outras alterações encontradas no presente caso contribuíram para complementar os achados orofaciais na literatura e auxiliar no diagnóstico da síndrome. Neste caso, um plano de tratamento integral e equipe multiprofissional foram essenciais para resgatar a saúde bucal e propiciar melhor qualidade de vida à paciente.

**Keywords:** Robinow Syndrome. Disabled Children. Dental Care.

**ABSTRACT**

**Introduction:** Robinow syndrome is a rare genetic disorder of skeletal development. It is characterized by short stature, facial dysmorphisms and orodental anomalies, underdeveloped genitalia, mesomelic brachymelia. **Case Report**: A 6 year old girl with Robinow Syndrome was referred in the Center for Formation of Human Resources Specialized in Dental Care to Special Needs Patients (Ribeirão Preto, São Paulo, Brazil) for evaluation. Medical history investigation and clinical examination were observed in short stature, facial dimorphism and hypoplastic genitalia. Orofacial findings showed retrognathism, a mid-line hemangioma approximately 1 cm wide with upturned borders, bifid tongue, ankyloglossia, general gingival hypertrophy, deep bite and mild tooth crowding. Cardiac abnormality and neuromotor developmental delay consisted of systemic manifestations present which demanded individualized dental care. The dental treatment consisted of preventive and restoratives procedures to adequate the oral health condition of the patient and orthodontic treatmentwas planned. The patient has been in follow-up for six years. **Conclusion**: Orofacial anomalies and other alterations found in the present case contributed to complement the orofacial findings described in the literature and to assist in diagnosis of the syndrome. In this case, amultiprofessional team and integral treatment were essential to rescue oral health and improvelife quality of the patient.

Submitted: July 2, 2019
Modification: September 16, 2019
Accepted: September 17, 2019

***Correspondence to:**
Francisco Wanderley Garcia Paula-Silva
Address: Faculdade de Odontologia de Ribeirão Preto da Universidade de São Paulo. Avenida do Café, s/n. Ribeirão Preto. SP. Brazil. Zip code: 14040-904.
Telephone number: 55 (16) 3315-3995.
E-mail: franciscogarcia@forp.usp.br

## INTRODUCTION

Robinow syndrome (RS) was first described in 1969 by Robinowet al.(1969).[1] Epidemiological data indicate occurrence in approximately 1:500,000 births with no gender predilection.[2] Researchers have identified two types of RS, which are distinguished by their patterns of inheritance and the severity of their signs and symptoms: autosomal dominant (OMIM #180700)[3] and autosomal recessive (OMIM #268310).[4] The diagnosis of RS is based mainly on the observation of typical clinical features like short stature, facial dysmorphisms and hypoplastic genitalia.[5]

Patients with RS present several craniofacial and orodental alterations such as frontal bossing, bulging or wide forehead, midfacial hypoplasia, hypertelorism, gingival hypertrophy, micrognathia, retrognathia, missing teeth, bilobed tongue tip. [6,7-10] The signs of both types of RS are similar, but tend to be more severe in the autosomal recessive form, including a more evident dwarfism and typical vertebral and rib segmentation anomalies, such as hemivertebrae with fused ribs leading to kyphoscoliosis. [11-15] Craniofacial findings are more significant in the recessive form whereas orodental features are more common in the dominant form.[16]

The prognosis of RS is unfavorable, especially for the patients with heart problems.[7] The treatment includes surgeries for treating hernias, vertebral anomalies and scoliosis, orthodontic procedures for correction of dental malocclusions, face reconstruction, psychotherapy and even growth hormone therapy in some cases.[17]

This report presents the case of a pediatric patient diagnosed with RS. The clinical features are described, with emphasis on the orodental findings and dental treatment performed in an outpatient dental service.

## CASE REPORT

A 6-year-old female child was referred for general dental treatment at the Center for Formation of Human Resources Specialized in Dental Care to Special Needs Patients, School of Dentistry of Ribeirão Preto, University of São Paulo, Brazil.

During the clinical interview, the mother revealed uneventful pregnancy, with normal ultrasound scans and results to laboratory tests within normal ranges. Between the third and fourth months the mother used procaine benzylpenicillin, dimenhydrinate and *sodium* dipyrone. She smoked one pack of cigarettes per day and was under continuous use of ranitidine hydrochloride. The child was born at term by cesarean delivery weighing 2,860 g and measuring 44 cm, with 34 cm cephalic perimeter and 5/9 Apgar score. The parents were healthy and non-consanguineous, and both were 30-year-old at the time of conception. There was no similar case in the family.

According to the medical history, the child had delayed neuromotor development, at 6 months, the child underwent surgical closure of the patent ductus arteriosus. The child had normal karyotype of 46 XX, and showed underdeveloped genitalia, focus of left parietal demyelination and discrete signs of cerebellum atrophy and moderate bilateral hearing loss.

Thus, general clinical examination revealed mesomelic shortening of the upper limbs, with small hands, strong ligament laxity, muscular hypotonia, brachycephaly, bilateral clinodactyly of the fifth fingers, and transversal palmar crease on the right hand (Figure 1A, 1B, 1C).

The craniofacial and orodental characteristics revealed very dispersed hair, low-set ears, frontal bossing, shallow eyebrows, “fetal face”, square nose tip, wide nose bottom, erased philtrum, thin lips, triangle-shaped mouth, retrognathism, a mid-line hemangioma approximately 1 cm wide with upturned borders, bifid tongue, ankyloglossia, general gingival hypertrophy, deep bite and mild tooth crowding (Figure 1B, 1D, 1E, 1F).

Initial radiographic examinations revealed early tooth losses due to the extensive carious lesions (Figure 2A). A panoramic radiograph showed the presence of all permanent teeth, supernumerary tooth in the region of the tooth 17 and the upper and lower third molar undergoing coronary formation (Figure 2B). Also, in the oral examination, the patient presented inflammation gingival and accumulation of biofilm in the upper and lower dental arch.

A two-phase treatment was planned for this case. In the first phase, preventive measures were applied.[18] The second phase was surgical and restorative. Teeth 64, 71, 74 and 81 were not restorable and were extracted. Teeth 16, 26, 62, 63, 75 and 85 were restored.

Due to the patient’s heart problems, a prophylactic antibiotic regimen was prescribed prior to the dental procedures, with 50 mg of Amoxilin per kg body weight taken 1 hour before the procedure. [19]

There was moderate mental retardation associated with uncooperative behavior. After a few modulating sessions employing the basic behavior guidance, [20] physical restraint measures were used after parental consent by signing the consent form.

After completion of the dental treatment, the patient was referred to orthodontic treatment, which it is in initial phase. The diagnosis and treatment orthodontic plan were performed after the clinical examination and documentation orthodontic analysis. By analyzing facial features, the patient

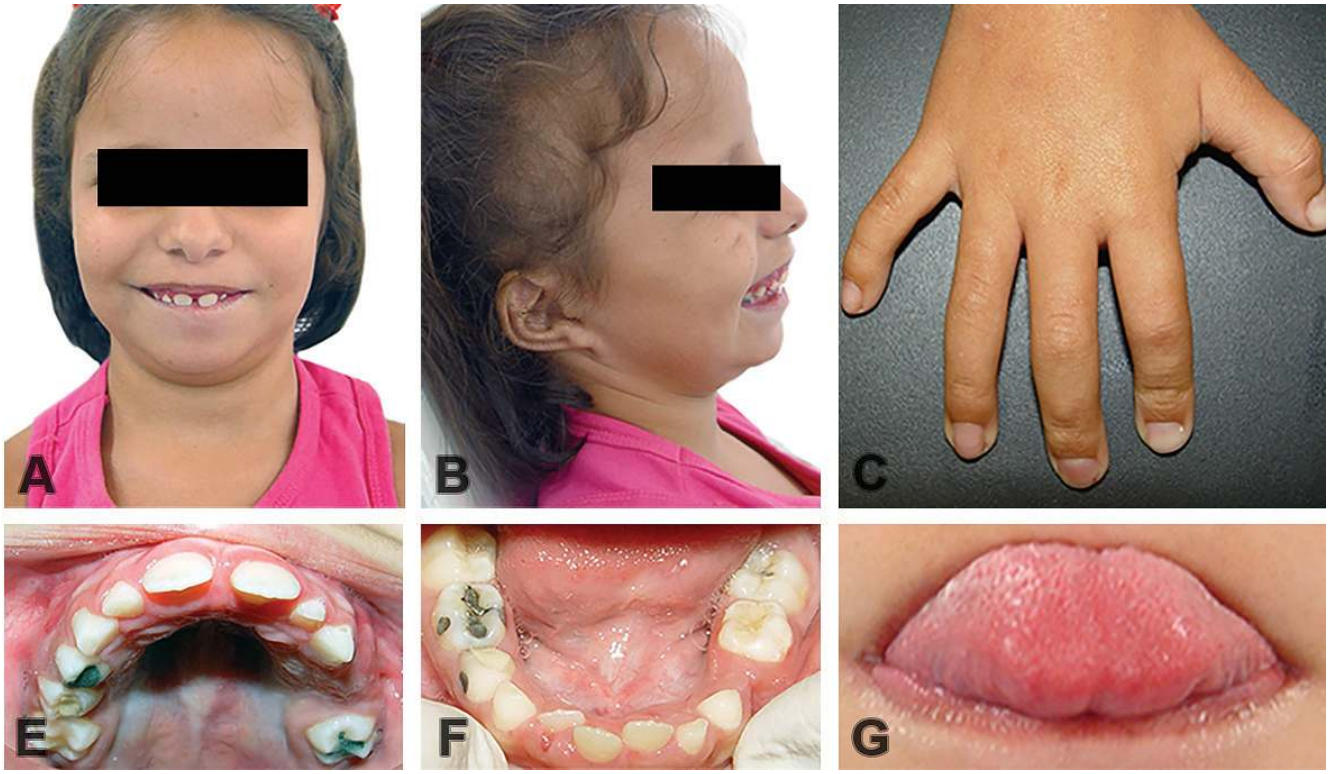


***Figure 1**: Patient at 6-year-old during treatment. (A) Frontal view of the patient. (B) Lateral view of the patient where it can be observed low-set ears, frontal bossing, and retrognathism. (C) Bilateral clinodactyly of the fifth fingers. (D) Intra-oral view where it can be observed high palate. (E) Presence of mild tooth crowding. (F) Presence of mild ankyloglossia.*

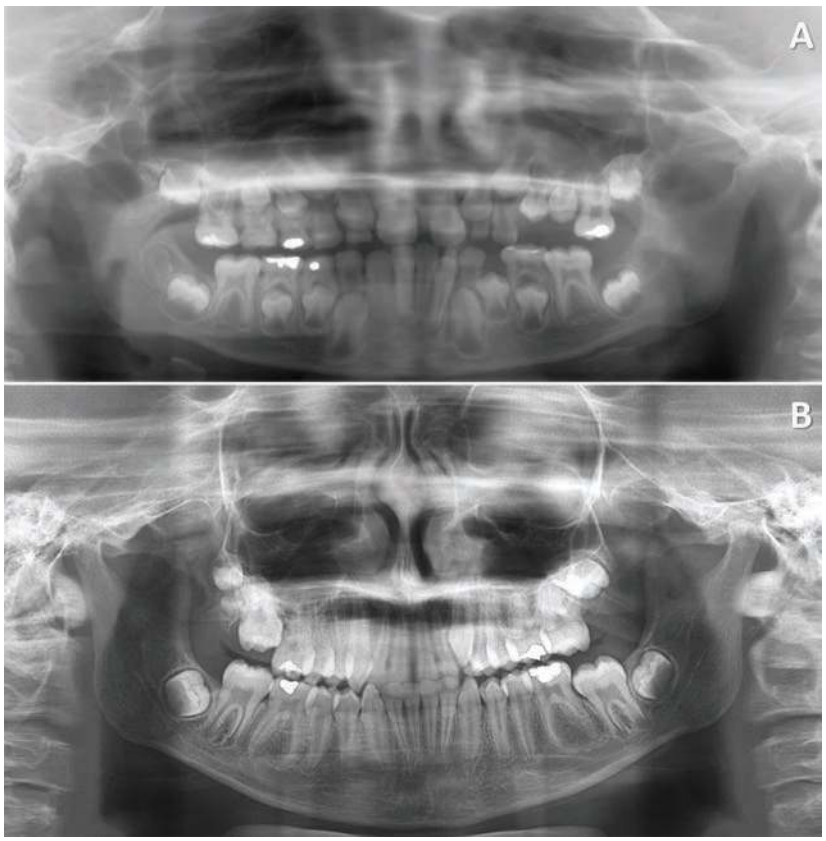


***Figure 2**: (A) Patient at 7-year-old, initial radiographic examination. (B) Patient at 11-year-old, actual radiographic examination.*

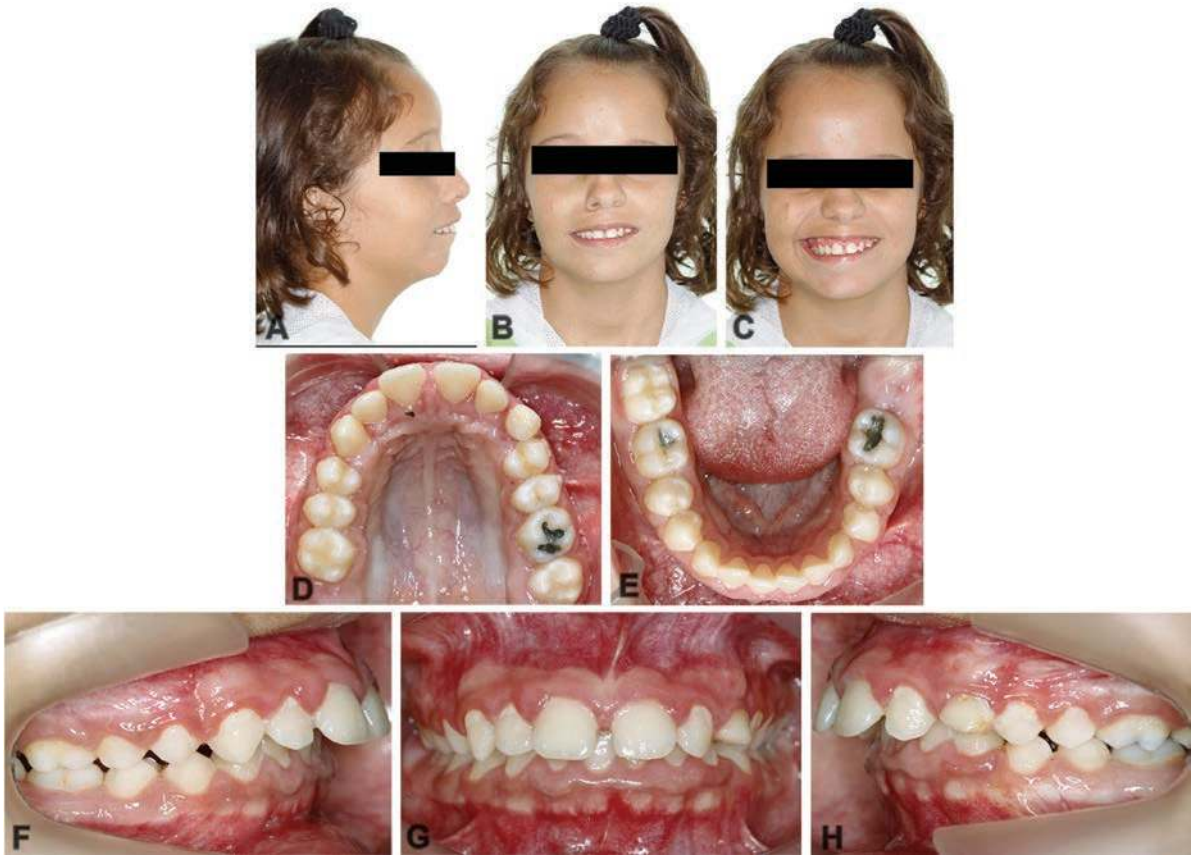


***Figure 3**: Patient at 11-year-old. (A) Lateral view of the patient with the presence of lower third increased, convex profile, nasolabial acute angle, decreased chin-neck line, absence of lip seal. (B) Frontal view of the patient which it can be observed facial assymmetric. (C) Frontal view of the patient which it can be observed facial asymmetric while smiling. (D) Maxillary arch. (E) Mandibular arch. (F), (G) and (H) Malocclusion Class II, Angle division 1 deep overbite, overjet of 7 mm, coincident upper midline and lower midline 1 mm deviated to the left, gingival hypertrophy.*

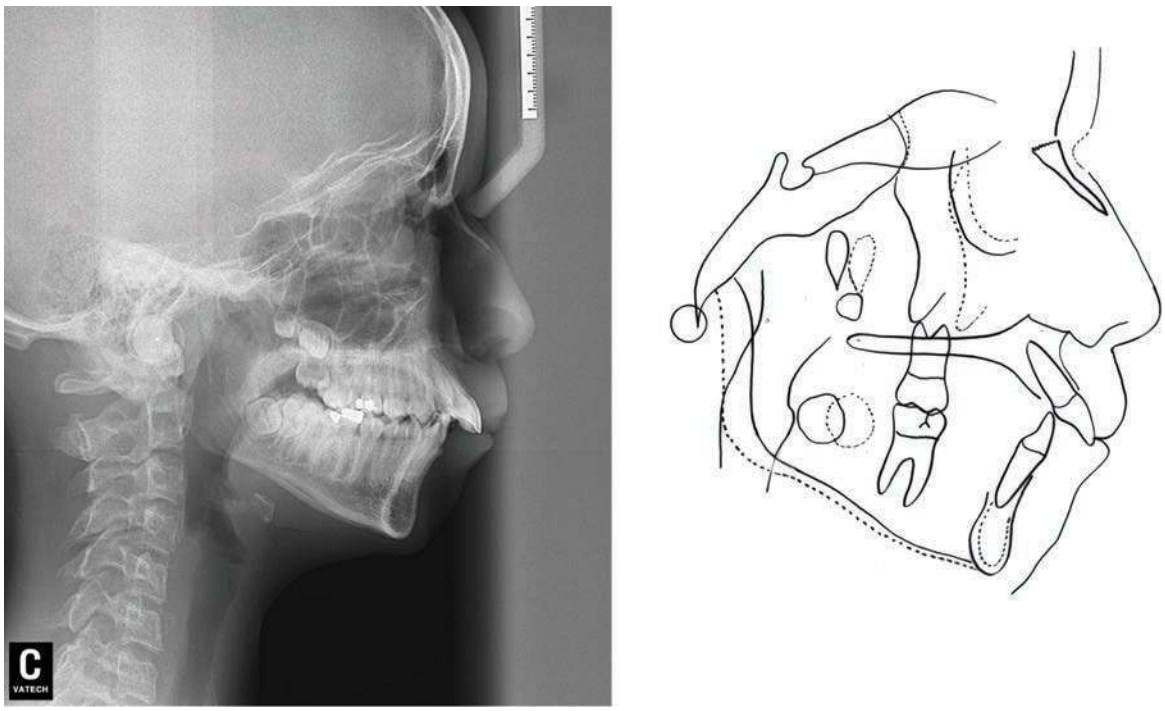


***Figure 4**: Patient at 11-year-old. (A) Lateral teleradiographic examination. (B) Cephalometric analysis.*

***Table 1**: Craniofacial and orodental manifestations: bibliographic survey*

| Craniofacial | Orodental |
|---|---|
| Frontal bossing[2, 8, 18, 28, 29, 33] | Triangular mouth (bottom corners face downward)[16, 28, 29, 33] |
| Bulging or wide forehead [16, 17, 28, 33] | Broad mout[8] |
| Hemangioma[8, 16] | High palate [8, 10, 11, 28, 29] |
| Flat facial profile with large head (macrocephaly not necessarily associated with hydrocephaly)[16, 28] | Long/short philtrum (tented upper lip, inverted "V" philtrum)[2, 8, 11, 16, 17, 25] |
| Midfacial hypoplasia [9, 10, 28, 29] | Dental abnormalities, misaligned teeth (crowded, missing teeth) [2, 9, 10, 11, 17, 18, 28, 29, 33] |
| Hypertelorism [2, 8, 16, 17, 25, 28, 29, 33] | Gingival hypertrophy [8-11, 16, 17, 28] |
| Wide palpebral fissures[7] | Abnormal uvula (heart shaped) [7, 9, 28] |
| Downslanting palpebral fissures[7, 29] | Absent uvula[16] |
| Lower lid deficiency (pseudoexophthalmos)[7] | Cleft lip/palate (non midline) [2, 8, 16, 33] |
| Ear abnormality, small and lower set [8, 17, 29] | Bifid tongue (bilobed tongue tip)[10, 16,18, 28, 29] |
| Right pre-auricular pit[16] | Ankyloglossia[9, 10, 16, 28, 29] |
| Micrognathia [8-10, 29] | Microdontia[8] |
| Retrognathia [11, 18] | Crowded tooth buds[8] |
| Prominent eyes with bilateral proptosis [2, 8, 11, 16, 18, 28, 29, 33] | Delayed tooth eruption and exfoliation[10, 16, 18, 28, 29] |
| Epicanthal folds [2, 11] | Short roots primary molars[16] |
| Flat-saddle nose[8] | Trapezoid maxillary arch[16] |
| Upturned nose with depressed nasal bridge[11, 16, 18, 28, 29, 33] | Narrow and thick-floored pulp chambers[16] |
| Short nose [2, 18, 25, 28] | Down-slanted mouth corners[2, 11] |
| Broad nasal bridge[16, 18, 25] | Thin upper lip [11] |
| Anteverted nares [17, 18, 25, 28, 29] | Supernumerary teeth[11] |
| Macrocephaly [11, 20, 28, 29] | |
| Posteriorly rotated ears [2, 18, 25] | |

presented lower third increased, convex profile, nasolabial acute angle, decreased chin-neck line, absence of lip seal and facial asymmetric (Figure 3A, 3B, 3C).

At that time, the patient was in the mixed dentition (Figure 3D and 3E) and dental pattern revealsed malocclusion Class II, Angle division 1, deep overbite, overjet of 7 mm, coincident upper midline and lower midline 1 mm deviated to the left (Figure 3F, 3G, 3H).

In cephalometric analysis (Figure 4) in the horizontal plane was possible to verify that the maxilla (SNA = 82 °) was well positioned and mandible (SNB = 73 °) retruded in relation to the anterior cranial base, showing an skeletal malocclusion class II (ANB = 8º). In the vertical plane the patient had a predominance of mesofacial vertical growth and morphological type (SNGoGn = 41 °, NSGn = 70 °, Facial axis = 89 °). The upper and lower incisors were protruded (1-NA = 7mm, 1-NB = 6mm) and axial inclination increased (1.NA = 32 °, 1.NB = 26 °).

The patient was referred to extraction of the supernumerary tooth after complete eruption and root formation of the permanent maxillary right second molar. Orthodontic treatment was performed in two phases. In the first phase, Kloehn headgear was adapted with a parietal traction (high) of 500 gf in each side. The use of the appliance was recommended for 12 hours/day to redirect the maxillary growth and to allow an anterior mandibular growth. The time to use this appliance was of approximately 12 months.

## FOLLOW-UP

During puberty, parents were informed about the importance of collaboration for the success of orthodontic treatment, especially during the period of growth. Unfortunately, the parents reported that they could not collaborate and that orthodontic treatment should be interrupted without the corrective phase.

The patient still remains in follow-up, as the child was considered a high-caries-risk patient after completion of the restorative phase. Additionally, supervision of oral homecare

by the parents was strongly recommended and gingival hypertrophy was not surgically treated because alteration was not severe.

## DISCUSSION

RS features can be identified at birth and by ultrasound examination, starting at 19 weeks of gestation.[9] The patient of this case was diagnosed with the recessive form of RS, based on her postnatal characteristics. [10-12, 20-22] Although parental consanguinity has an important role in RS etiology,[7] the patient in this case was born to a non-consanguineous couple.

Congenital heart problems are a common finding in individuals with RS, accounting to 16% of the cases reported in the literature and 5 to 10% of the children with RS die prematurely due to heart problems. [1,6,23-25] The patients with RS requires reduction of anxiety (usually evoked by dental treatment) as well as maintenance of adequate oral conditions without infectious foci and administration of prophylactic antibiotics prior to dental procedures for prevention of bacterial endocarditis[14] and supervision of oral homecare for parents.

The patient presented mental retardation, even though normal intelligence is reported in most cases. [8-10, 13, 26-28] The neuropsychomotor condition of the patient was an important issue during the dental treatment because she presented unpredictable oscillations of mood, poor understanding of instructions and resistive behavior that are common to individuals with mental retardation.

After a few modulating sessions using resources of behavior management, the patient became more cooperative with dental staff, allowing the treatment without need of sedation or general anesthesia, thus eliminating the risks inherent to general anesthesia procedures and hospital infection, which are increased in patients with cardiovascular problems. In addition, the anatomic characteristics of patients with RS make intubation very difficult. [29,30]

Patients with RS present several craniofacial and orodental alterations.[12-15] In this case the syndrome was characterized by the findings that are consistent with other reports in the literature (Table 1).

Besides the orodental examination, this case report evaluated the cephalometric profile of the patient which yet there not report in the literature to Robinow syndrome. The detection of occlusal alterations is important to execute the planning of orthodontic treatment in earlier phase because the improvement in facial appearance in syndromic children is gradually reduced with growth.[31] Further studies are needed to describe the differences in frequency and severity of craniofacial and orodental features and between dominant and recessive forms to be used as clinical pattern in the characterization of the forms of Robinow Syndrome.[16,32] In this way, it is very important that the dentists describe in detail the craniofacial and orodental findings and to assist in diagnosis in this syndrome, because the facial features are more pronounced in younger subjects than adults.[16] The dental treatment requires that the dentist to be familiar with RS features, as well the performance of integral treatment and multiprofessional team is essential to promote a better life quality to these patients.

Orofacial anomalies and other alterations presented in this case contributed to the orofacial findings described in the literature for diagnosis of Robinow syndrome. In this case, a multiprofessional team and integral treatment were essential to rescue oral health and improve life quality of the patient.

## REFERENCES

1. Robinow M, Silverman FN, Smith HD. A newly recognised dwarfing syndrome. Am J Dis Child 1969;117: 645–51.
2. Hosalkar HS, Gerardi J, Shaw BA. Robinow syndrome. J Postgrad Med 2002; 48: 50-1.
3. OMIM #180700 [n.d.] Robinow syndrome, autosomal dominant [Internet], Online Mendelian Inheritance in Man. Available from: <http://omim.org/entry/180700> [Accessed July 18 2012].
4. OMIM #268310 [n.d.] Robinow syndrome, autosomal recessive [Internet], Online Mendelian inheritance in man. Available from: <http://omim.org/entry/268310> [Accessed July 18 2012].
5. Robinow M. The Robinow (fetal face) syndrome: a continuing puzzle. Clin Dysmorphol 1993; 2:189-98.
6. Robinow, M. Robinow syndrome. In: Buyse ML (eds): Birth defects encyclopedia. Massachusetts: Blackwell Scientific Publications; 1990; 1499-1500.
7. Patton MA, Afzal AR. Robinow syndrome. J Med Genet 2002;39:305–310.
8. Al Kaissi A, Bieganski T, Baranska D, Chehida FB, Gharbi H, Ghachem MB, Hendaoui L et al. Robinow syndrome: report of two cases and review of the literature. Australas Radiol 2007; 51:83-86.
9. Grothe R, Anderson-Cermin C, Beiraghi S. Autosomal Recessive Robinow Syndrome: A Case Report. J Dent Child 2008; 75: 48-54.
10. Cerqueira DF, Souza IPR. Orofacial manifestations of Robinow's Syndrome: a case report in pediatric patient. Oral Surg Oral Med Oral Pathol Oral Radiol Endod 2008; 105:353-7.
11. Mazzeu JF, Pardono E, Vianna-Morgante AM, Richieri-Costa A, Ae Kim C, Brunoni D et al. Clinical characterization of autosomal dominant and recessive variants of Robinow syndrome. Am J Med Genet A 2007; 143: 320-325.
12. Castells S, Chakurkar A, Qazi Q, Bastian W. Robinow syndrome with growth hormone deficiency: treatment with growth hormone. J Pediatr Endocrinol Metab 1999; 12:565-71.

13. American Academy of Pediatric Dentistry. Guideline on caries-risk asse ssment and management for infants, children, and adolescents. Pediatr Dent 2010-2011; 31(6): 179-86.
14. Wilson W, Taubert KA, Gewitz M, Lockhart PB, Baddour LM, Levison M et al. Prevention of infective endocarditis: guidelines from the American Heart Association: a guideline from the American Heart Association Rheumatic Fever, Endocarditis, and Kawasaki Disease Committee, Council on Cardiovascular Disease in the Young, and the Council on Clinical Cardiology, Council on Cardiovascular Surgery and Anesthesia, and the Quality of Care and Outcomes Research Interdisciplinary Working Group. Circulation 2007; 116: 1736-1754.
15. American Academy of Pediatric Dentistry. Guideline on Management of Dental Patients with Special Health Care Needs Pediatr Dent 2016-2017; 38(6): 107-1.
16. Kantaputra PN, Gorlin RJ, Ukarapol N et al. Robinow (Fetal Face) Syndrome: Report of a boy with Dominant Type and an Infant With Recessive Type. Am J Med Genet 1999; 84:1-7.
17. Suresh SS. Robinow Syndrome. Indian J Orthop. 2010; 42:474-6.
18. Roifman M, Brunner H, Lohr J, et al. Autosomal Dominant Robinow Syndrome. 2015 Jan 8 [Updated 2018 Aug 9]. In: Adam MP, Ardinger HH, Pagon RA, et al., editors. GeneReviews® [Internet]. Seattle (WA): University of Washington, Seattle; 1993-2019.
19. Atalay S, Ege B, Imamoðlu A, Suskan E, Ocal B, Gümüþ H. Congenital heart disease and Robinow syndrome. Clin Dysmorphol 1993; 3: 208-210.
20. Sabry MA, Ismail EA, al-Naggar RL, al-Torki NA, Farah S, al-Awadi SA, Obenbergerova D et al. Unusual traits associated with Robinow syndrome. J Med Genet 1997; 34:736–740.
21. Al-Ata J, Paquet JAM, Teebi AS. Congenital Heart Disease in Robinow Syndrome. Am J Med Genet 1998; 77:332-333.
22. Wang LY, Hsu CH, Shih SL, Lin SP. Robinow syndrome: report of one case. Chung Hua Min Kuo Hsiao Erh Ko I Hsueh Hui Tsa Chih 1997; 38: 235-238.
23. Castro S, Peraza E, Barraza A, Zapata M. Prenatal diagnosis of Robinow syndrome: a case report. J. Clin. Ultrasound 2014; 42:297-300.
24. Mishra S, Agarwalla SK, Pradhan S. Robinow Syndrome: A Rare Diagnosis. J Clin Diagn Res. 2015; 9: SD04–SD05.
25. Nagasaki K, Nishimura G, Kikuchi T, Nyuzuki H, Sasaki S, Ogawa Y el al. Nonsense mutations in FZD2 cause autosomal-dominant omodysplasia: Robinow syndrome-like phenotypes. Am J Med Genet. 2018;176A:739–742.
26. Lirk P, Rieder J, Schuerholz A, Keller C. Anaesthetic implications of Robinow syndrome. Paediatr Anaesth 2003; 13: 725-7.
27. Sleesman JB, Tobias JD. Anaesthetic implications of the child with Robinow syndrome. Paediatr Anaesth 2003; 13:629–632.
28. Basman A, Akay G, Peker I, Güngör K, Akarslan Z, Özcan S, el al. Dental management and orofacial manifestations of a patient with Robinow Syndrome. J Istanbul Univ Fac Dent 2017; 51(2):43-48.
29. Jain PS, Gupte TS, Jetpurwala AM, Dedhia SP. Robinow syndrome and fusion of primary teeth. Contemp Clin Dent 2017; 8:479-81.
30. Beiraghi S, Leon-Salazar V, Larson BE, John MT, Cunningham ML, Petryk A, Lohr JL. Craniofacial and intraoral phenotype of Robinow syndrome forms. Clin Genet 2011; 80: 15-24.
31. Gürsoy S, Hukki J, Hurmerinta K. Five year follow-up of mandibular distraction osteogenesis on the dentofacial structures of syndromic children. Orthod Craniofac Res 2008; 11: 57-64.
32. Afzal AR, Rajab A, Fenske CD, Oldridge M, Elanko N, Ternes-Pereira E, Tüysüz B et al. Recessive Robinow syndrome, allelic to dominant brachydactyly type B, is caused by mutation of ROR2. Nat Genet 2000; 25:419-22.
33. Kargi E, Acun C, Tomaç N, Savranlar A, Dursun A, Babuccu O. Midline cleft of the lower lip associated with Robinow syndrome. Scand J Plast Reconstr Surg Hand Surg 2004; 38:361-4.

# AESTHETIC RECOVERY OF THE SMILE USING A SIMPLE AND EFFECTIVE APPLICATION OF PREPOLYMERIZED COMPOSITE VENEERS

Cínthia Marques **Sperduto**[1], Jeane Batista dos Santos **Cavalcante**[1], Núbia Gomes de **Santana**[1], João Victor Frazão **Câmara**[1*], Isabel Ferreira **Barbosa**[1], Gisele Damiana da Silveira **Pereira**[1]

[1]Department of Dental Clinic, Federal University of Rio de Janeiro, Rio de Janeiro, RJ, Brazil

**Palavras- chaves:** Estética. Falha de Restauração Dentária. Estética Dentária.

**RESUMO**

**Introdução:** As facetas pré-fabricadas de resina composta são laminados pré-polimerizados de compósito que surgiram no mercado para simplificar o procedimento restaurador, reduzindo o tempo de trabalho. São facetas extremamente finas, fabricadas em diversos tamanhos, com as quais é possível realizar restaurações com alto padrão estético em dentes anteriores através de uma técnica minimamente invasiva. **Objetivo:** Esse trabalho teve como objetivo demonstrar o uso de facetas pré-fabricadas de resina na reanatomização e recuperação da estética dentária de um paciente jovem com histórico de fratura e escurecimento dos dentes anteriores, após cirurgia estética periodontal. **Relato de caso:** Paciente compareceu à clínica com queixa do sorriso e ao exame clínico, observou-se dente 11 com fratura cervical, dente 21 com alteração de cor e infiltração por cárie e dente 22 com inclinação da face distal para palatina. Como tratamento, foi optado pela utilização das facetas pré-fabricadas de resina composta. **Conclusão:** Os resultados estéticos deste caso foram altamente satisfatórios, principalmente quando comparados ao tempo clínico, custo e trabalho laboratorial de facetas de cerâmica, mostrando a qualidade e as vantagens desse material.

**Keywords:** Aesthetics. Dental Restoration Failure. Dental Aesthetics.

**ABSTRACT**

**Introduction:** The prefabricated composite resin veneers are prepolymerized laminates of composite that appeared in the market to simplify the restorative procedure, reducing working time. They are extremely thin veneers fabricated in several sizes, which allows performing restorations with high aesthetic standard in anterior teeth using a minimally invasive technique. **Objectives:** This study aimed to show the use of prefabricated resin veneers in the re-anatomization and recovery of dental aesthetics of a young patient with history of fracture and darkening of anterior teeth after aesthetic periodontal surgery. **Case report:** The patient attended the clinic with a smile complaint and the clinical examination showed tooth 11 with cervical fracture, tooth 21 with color change and caries infiltration, and tooth 22 with inclination of the distal surface toward the palatal region. As treatment, was opted for the use of prefabricated composite resin veneers. **Conclusion:** The aesthetic results of this case were highly satisfactory, especially when compared with clinical time, cost, and the laboratory work of ceramic veneers, showing the quality and advantages of this material.

Submitted: May 21, 2019
Modification: September 19,02019
Accepted: September 20, 2019

***Correspondence to:**
João Victor Frazão Câmara
Address: Alameda Doutor Octávio Pinheiro Brisolla, 6-65, Jardim Brasil, Bauru - São Paulo, Brazil. Zip code 17012-059.
Telephone number: +55 (21) 98384-4255
E-mail: jvfrazao92@hotmail.com

## INTRODUCTION

Over the last years, aesthetics in Dentistry has been a determinant factor for the development of new materials and techniques.[1,2] Several factors may interfere with the aesthetics of the smile, including dental trauma, which causes changes in tooth shape and potential darkening. This clinical situation may cause discomfort to the patient and brings the challenge of conservative aesthetic solution to dental professionals.[3]

Restorative procedures with minimal dental preparation that employ adhesives. The adhesive system promotes a high degree of physical and chemical adhesion at the tooth/restoration interface, reduction of polymerization contraction and marginal microleakage. Therefore, the prefabricated composite resin veneers are used in cases presenting deficient restorations and/or shape changes, allowing an aesthetic recontouring. They are extremely thin and fabricated in several sizes, which allows performing restorations with high aesthetic standard in anterior teeth and minimally invasive restorations, preserving the dental structure.[4]

Thus, this study aimed to show the clinical use of prefabricated resin veneers in the aesthetic dental recovery of a young adult patient.

## CASE REPORT

Male patient, D B S, 24 years old, attended the Integrated Clinic of the School of Dentistry of the Federal University of Rio de Janeiro, RJ, Brazil, complaining of the appearance of his anterior teeth. After anamnesis, clinical examination, radiographic analysis, and initial photographs, the treatment was designed.

The clinical examination showed a deficient restoration of element 21, with overcontouring, disharmonious color, and caries infiltration; small cervical fracture in element 11, restored with excess composite resin; element 22 with inclination of the distal surface toward the palatal region; absence of proportion between the cervico-incisal size of upper central and lateral incisors and inadequate gingival contour; and presence of bacterial plaque and dental calculus, especially in the lingual aspect of lower incisors (Figure 1A).

Initially, instructions were provided on oral hygiene and adequacy of the oral environment, which included supragingival scaling with periodontal curettes (Hu-Friedy Mfg.Co, LLC3232 N. Rockwell St.Chicago) and prophylaxis with Robinson brush (Microdont Micro Usinagem de Precisão Ltda, SP, Brazil) and prophylactic paste (Herjos 90G Tutti Frutti – RJ- Brazil).

Next, gingivectomy was performed from element 12 to element 22 to improve the gingival contour, considering that central incisors presented small cervico-incisal size relative to lateral incisors and canines. The surgical technique selected was external bevel gingivectomy (16,17), with the purpose of recontouring the lining tissues. The periodontal pocket depth was assessed with a millimeter bur (Hu-Friedy Produtos para Saúde Ltda - Rio de Janeiro - RJ - Brazil) followed by an external bevel and intrasulcular incision with a scalpel blade (Maxicor - Paraná - Brazil). The incised area was removed with a Gracey periodontal curette (Golgran 2013 Desenvolvimento N2 Mídia - SP - Brazil) and the tooth surface exposed was subjected to scaling and flattening (Figure 1B). There was no suture or placement of surgical cement, therefore allowing a second-intention healing.

After two weeks, the composite resin restoration of element 21 was removed, considering the presence of overcontouring and caries infiltration. After removing the caries and the restoration, little remaining tooth structure was verified (Figure 1C). The post was made of fiberglass composite and epoxy resin, featuring high mechanical strength, double taper, radiopacity and aesthetics. In anterior teeth, the indication is determined for 50% loss of structure coronary. For stabilization of the coronary reconstruction, the post occupied two thirds of the length of the dental remnant. Proper endodontic treatment allowed the absolute isolation of the element, preparation of the conduit by removing the gutta-percha with a 0.5 Largo bur (Microdont Micro Usinagem de Precisão Ltda - SP - Brazil) for cementing a prefabricated 0.5 White Post fiberglass post (FGM Produtos Odontológicos – SC – Brazil) previously performed cleaning with alcohol and silanized with Prosil (FGM Produtos Odontológicos - SC – Brazil). After 60s and with a short air blast, excess silane is removed. The post was cemented with RelyX U 200 self-adhesive resin cement (3M Brasil - SP - Brazil) (Figure 1D). The excess fiberglass post was cut with a #4 spherical diamond bur (Microdont Micro Usinagem de Precisão - SP - Brazil) and the final restoration was performed with an Opallis composite resin (FGM Produtos Odontológicos - SC – Brazil) translucent in the palatal region (Figure 1E), opaque in the incisal region, and A3 and D3 in the buccal region by the stratification method (Figure 1F), with posterior finishing and polishing.

The same session included the selection of the prefabricated aesthetic veneers (Brilliant NG Componeer - Coltene) of incisal resin by size and translucency, whereas size L opaque bleach was chosen. Next, elements 11, 12, 21, and 22 were prepared with a light bevel on the buccal aspect with a 4138 bur (Microdont Micro Usinagem de Precisão - SP - Brazil) to reduce the convexity until fitting the veneers



***Figure 1**: (A) Initial photograph; (B) Periodontal surgery of gingival recontouring of elements 12 to 22; (C) Removal of the deficient restoration of element 21; (D) Cementation of prefabricated 0.5 White Post fiberglass post (FGM, Brazil); (E) Performance of adhesive system and application of a thin layer of Opallis translucent composite resin (FGM, Brazil) per palatal region; (F) Final restoration with Opallis A3 and D3 composite resin (FGM, Brazil) by the stratification method; (G) Preparation of elements 11, 12, 21, and 22 with light bevel on the buccal aspect with a 4138 bur (Microdont, Brazil); and (H) Preparation of veneers with 37% phosphoric acid etching.*



***Figure 2**: (A) 37% phosphoric acid etching with Condac 37 - Dentscare (FGM, Brazil); (B) Preparation of veneers with active application of Adper Single Bond II adhesive (3M, Brazil); (C) Active application of conventional adhesive of two steps (3M, Brazil) and light curing and (D) Thin layer of Opallis composite resin applied on the buccal aspect of teeth, followed by the positioning of veneers with mild pressure and light curing.*



***Figure 3**: Final photograph.*

(Figure 1G). The teeth and veneers were etched with 37% phosphoric acid (Condac FGM Produtos Odontológicos - SC – Brazil) (Figures 1H and 2A). Washing was performed with water blast for 20 s and, after removal, the tooth surface was briefly air dried. A conventional adhesive system (One Coat Bond SL – Coltene) of two steps with water base that does not change the physical conditions of the veneers was used. It was applied with a microbrush (Figure 2B) followed by light curing for 20 s, according to the manufacturer's instructions. Brilliant NG resin color scale was used (Brilliant NG Componeer - Coltene) for color selection of resin for cementation of facets. A thin layer of Opallis flow composite resin (high mechanical strength and low viscosity) (FGM Produtos Odontológicos - SC – Brazil) was placed on the buccal aspect of teeth and the veneer was pressed over this resin and later light cured for 40 s with Bluephase G2 (Ivoclar/Vivadent - Liechtenstein) on all surfaces (Figure 2C). The excess resin was removed with a composite resin spatula. Each tooth was individually prepared and cemented to control the removal of excess cementing material. The palatal surfaces of teeth were filled with composite resin and the canine guide was set for tooth 13 in the incisal region by placing Opallis A3 composite resin (FGM Produtos Odontológicos - SC – Brazil) and later finishing and polishing (Figures 2D and Figure 3).

## DISCUSSION

The unbalance of smile harmony is seen as a determinant factor for facial harmony. Several factors may produce problems that affect oral aesthetics, including dental traumas, caries, frequent consumption of pigmented foods, tooth malpositioning, among others.[5,6,7]

In order to reach excellent functional and aesthetic results, considering the gingival level and smile line were not satisfactory in the present report, a multidisciplinary approach is required to re-establish harmony between tooth structure and the gingiva. Therefore, gingivectomy is required to extend the length of clinical crowns of anterior teeth and to a harmonious gingival contour.[8]

Ceramic laminates have been considered the gold standard for restoring anterior teeth, but a less invasive preparation is needed.[9] They show excellent properties such as biocompatibility and aesthetics. However, their mechanical limitations such as fragility, low fracture toughness, low stress, and the flexural strength and wear caused on antagonist teeth have been described as potential disadvantages.[10]

The use of prefabricated composite resin veneers has been the aesthetic solution mostly used to elongate anterior teeth, correct malpositioning, close diastemas, and mask discolorations in devitalized teeth, also restoring fractured teeth, extensive caries lesions, congenital malformations, and fluorosis.[11,12,13,14]

These veneers present the advantage of a low elasticity modulus and a higher ability to absorb functional loads when compared to porcelain veneers,[15,16] and they are more viable economically. As for ceramic veneers, they favor the preservation of structure and allow easy color selection.[17] Such technique provides shorter clinical time and lower cost also when compared to direct composite resin veneers.

This model of veneers is available in small, medium, large, and extra-large sizes, and the veneer closest to the size of the tooth in question is selected. Some adjustments may be required by wearing the piece.[17] Marginal and

superficial discoloration problems have been reported over time. Another disadvantage is the difficulty for selecting the correct opacifying resin when masking the unwanted color of the dental element is required.[18] As a solution, thin layer of opaque resin, dispersed with the aid of non-adhesive microbush to evaluate naturalness compared to tooth color.

The composite veneers are formed with thin layers that are polymerized under controlled light, heat, and pressure, providing greater durability and aesthetics. The probability of failure of restorations of composite resin veneers was not significantly different from the ceramic restorations.[18] Perdigão *et al.* reported that prefabricated veneers resulted in a mechanical strength statistically similar to IPS E.max Press (Ivoclar, Vivadent, Schaan, Liechtenstein), but further studies assessing the survival of this type of material are required.[19]

As related by Dietschi *et al.*, prefabricated veneers present reduction of polymerization shrinkage, superior mechanical properties compared to direct resin, decreasing gap, postoperative hypersensitivity and microleakage. Besides that, direct composite resin restorations present some limitations such as the difficulties of color match and surface polishing. However, further *in vivo* studies are needed to assess the potentiality of prefabricated veneers.

## CONCLUSION

In this case report, the clinical use of prefabricated resin veneers in the aesthetic dental was considered success because is a technique that preserves the dental structure, fast and low cost.

## REFERENCES

1. Korkut B, Yanýkoglu F, Günday M. Direct composite laminate veneers: Three case reports. J Dent Res Dent Clin Dent Prospects. 2013;7(2):105–111.

2. Abu Arqoub SH, Al-Khateeb SN. Perception of facial profile attractiveness of different antero-posterior and vertical proportions. Eur J Orthod. 2011; 33(1):103-11.

3.Kumar A, Kumar V, Singh J, Hooda A, Dutta S: Drug-induced discoloration of teeth: An updated review. Clin Pediatr. 2012; 51(2):181–185.

4.Nguyen JF, Migonney V, Ruse ND, Sadoun M. Resin composite blocks via high-pressure high-temperature polymerization. Dent Mater. 2012; 28(5):529-534.

5.Al-Zarea BK. Satisfaction with appearance and the desired treatment to improve aesthetics. Int J Dent. 2013; 2013:1-7.

6.Anchieta RB, Rocha EP, Watanabe MU, de Almeida EO, Freitas-Junior AC, Martini AP, Barioni SR. Recovering the function and esthetics of fractured teeth using several restorative cosmetic approaches. Three clinical cases. Dent Traumatol. 2011;28:166–172.

7.DiAngelis AJ, Andreasen JO, Ebeleseder KA, Kenny DJ, Trope M, Sigurdsson A, Andersson L, Bourguignon C, Flores MT, Hicks ML, Lenzi AR, Malmgren B, Moule AJ, Pohl Y, Tsukiboshi M . International Association of Dental Traumatology guidelines for the management of traumatic dental injuries: 1. Fractures and luxations of permanent teeth. Dent Traumatol. 2012; 28:2–12.

8.Pinto RC, Chambrone L, Colombini BL, Ishikiriama SK, Britto IM, Romito G. A. Minimally invasive esthetic therapy: a case report describing the advantages of a multidisciplinary approach. Quintessence Int. 2013; 44(5):385-391.

9.Kamal V, Mahesh GE, Parag D. Esthetic smile designing with porcelain laminates – a case report. Journal of Pierre Fauchard Academy. 2014; 28:100-103.

10.Gomes G, Perdigao J. Prefabricated composite resin veneers – A clinical review. J Esthet Restor Dent. 2014; 26(5):302-313.

11.Dietschi D, Devigus A. Pre-fabricated composite veneers: Historical perspectives, indications and clinical application. Eur J Esthet Dent. 2011; 6:178–87.

12.Du Toit J, Patel N. Montalli V, Jain S. Aesthetic treatment of severely fluorosed teeth with prefabricated composite veneers: a case report. IntDentistry South Africa. 2012;2(6):44-50.

13.Bhatt A, Gupta V. Componeer- A case study. Update Dental College Journal. 2016; 6(1):40-42.

14.Migliau G, Besharat LK, Sofan AAA, Sofan EAA, Romeo U. Endo-restorative treatment of a severely discolored upper incisor: resolution of the “aesthetic” problem through Componeer veneering System. Ann Stomatol. 2016;12(3-4):113-8.

15.Gargari M, Ceruso FM, Pujia A, Prete V. Restoration of anterior teeth using an indirect composite technique. Oral Implantol. 2014;6(4):99-102.

16.D‘Sousa DSJ, Kumar M. Esthetics and biocompatibility of composite dental laminates. Med J Armed Forces India. 2010;66(3):239-43.

17.Magne P, Stanley K, Schlichting LH. Modeling of ultrathin occlusal veneers. Dent Mater. 2012;28(7):777-82.

18.Gurtu A, Bansal R, Chowdhary P, Mehrotra N, Mohan S, Mehrotra A, Kishore A. Componeer: An emerging esthetic solution. J Dent Sci Oral Rehab. 2016;7(3):146-148.

19.Perdigão J, Sezinando A, Muñoz MA, et al. Prefabricated veneers—bond strengths and ultramorphological analyses. J Adhes Dent. 2014;16(2):137–46.

# Revista Científica do CRO-RJ (Rio de Janeiro Dental Journal) | Instructions to authors

The Revista Científica do CRO-RJ (Rio de Janeiro Dental Journal), a periodical published quarterly aiming at divulging and promoting scientific production and interchange of information between the Brazilian and International community in the different areas of Dentistry and other fields of Health Care. The entire content of the Revista Científica do CRO-RJ (Rio de Janeiro Dental Journal) is available on the following web site http://revcientifica.cro-rj.org.br, to which there is free access. All the articles published in the Revista Científica do CRO-RJ (Rio de Janeiro Dental Journal) have a publication license CC BY-NC-ND (http://creativecommons.org/licenses/by-nc-nd).

The Revista Científica do CRO-RJ (Rio de Janeiro Dental Journal) publishes original articles, clinical case reports, protocols, reviews, letters to the editor and editorials/comments. Researches involving animals and/or human beings must be accompanied by the Certificate of Approval of a Research Ethics Committee. All articles are published in PDF format, in American English and must be submitted in this language. An abstract in Portuguese is demanded at the time of submitting and sending the final version.

**Peer Review Process**

All the content published by the Revista Científica do CRO-RJ (Rio de Janeiro Dental Journal) goes through the process of review by specialists. Articles submitted for appreciation are sent to the CRO-RJ librarian, who, under the supervision of the Editors-in Chief, initially assesses them with regard to the minimum standards demanded relative to form of presentation in the Revista Científica do CRO-RJ (Rio de Janeiro Dental Journal), with a view to complying with all the guidelines required for sending original articles. Once approved at this stage, the original is submitted for appreciation by the Editorial Board, to assess the merit of the work and decide about the convenience of publishing it, with or without changes. After this, the article is sent to undergo a process of evaluation carried out in the review system, by peers selected from a register of reviewers. The reviewers are always professionals from institutions different from that of the origin of the article; they are blind to the identity of the authors and place of origin of the work. After receiving both reports, the Editorial Council evaluates them, and decides about acceptance of the article without changes, rejection, or return to the authors with the suggestions about changes. The Editorial Board is responsible for returning the article to the authors for explanations, as many times as necessary, and at any time, the Editors may decide to reject the document. Each version is always analyzed by the Editorial Board that has the power of making the final decision.

**Types of Articles Published**

The Revista Científica do CRO-RJ (Rio de Janeiro Dental Journal) accepts the spontaneous submission of original articles, clinical case reports, protocols, reviews, letter sot the editor and editorials/review comments, and letters to the editor.

**Original articles** include randomized and controlled studies; studies of diagnostic tests and triage; observational cohort, case control and cross-sectional studies; other descriptive and experimental studies, as well as those of basic research with laboratory animals. The text must have a maximum of 3.000 words, excluding tables and references; the number of references must not exceed 30. Articles that report clinical trials with therapeutic interventions must be registered in one of the Registers of Clinical Trials

listed by the World Health Organization. In the absence of a Latin American Register, the Revista do CRO-RJ (Rio de Janeiro Dental Journal) suggest that the authors use the following register www.clinicaltrials.gov, of the National Institute of Health (NIH). The Identification Number must be presented in the body of the manuscript. The submission of clinical trials must adhere to CONSORT checklist (http://www.consort-statement.org/). In cases of submission of observational studies, for preparation of the manuscript, adhesion to the STROBE guidelines is requested (https://www.strobe- statement.org/index.php?id=strobe-home).

**Clinical Case Reports** must not exceed 2000 words, including the abstract, brief introduction, description of the case, discussion, acknowledgments (if there are any). The figures may be organized in the form of a panel. Each panel will be considered a figure. The abstract must not exceed 250 words. Case report articles must be accompanied by the term of free and informed consent signed by the participant and/or his/her legal guardian. For preparation of the manuscript, authors must adhere to the guidelines suggested in CARE (http://www.care-statement.org).

**Protocols** the protocols aim to guide clinical practices in the different specialties of dentistry. Description: Structured Summary (150 words); introduction; step-by-step presentation of the adopted protocol with textual description and images/figures/tables; discussion, conclusions and references.

**Reviews** are critical and orderly assessments of the literature relative to topics of clinical importance, with emphasis on factors such as the causes and prevention of diseases, their diagnosis, treatment and prognosis. Systematic reviews and meta-analyses are included in this category. In the body of the manuscript of the latter two types of reviews, authors must include the Registration Number of the Review protocol in PROSPERO (http://www.crd.york.ac.uk/PROSPERO/). For preparation of the manuscript, authors must follow the guidelines proposed by PRISMA (http://www.prisma-statement.org/). Authors may also submit a proposal of a review article, with a script, to the Editorial Board. If this is approved the author may develop the script and submit it for publication. Review articles must be limited to 6.000 words, excluding references and tables.

**Letters to the editor** must contain comments with a constructive critical content about subject matter previously published in the Revista Científica do CRO-RJ (Rio de Janeiro Dental Journal). These must be submitted directly to the Editorial Board. The maximum size is 1000 words, including a maximum of 10 bibliographic references. Whenever possible, a reply to the authors will be published together with the letter.

**Editorials and comments** are commissioned from authorities in specific areas. The Editorial Board may also analyze proposals of spontaneously submitted comments.

**General Guidelines**

The manuscript must be written using 12-point Arial font, on A4 size pages, with 1.5 line spacing, and a 3 cm margin on each side of the page, including the bibliographic references and titles/legends of tables and illustrations. The file must be presented in digital format, extension “doc” or “docx”. Each section must start on a new page, in the following order; title page, abstract in Portuguese, Abstract in English, text, acknowledgments, bibliographic references, tables (each complete table, with title and footnotes, on a separate page), figures (each complete figure, with titles and footnotes, on a separate page) and figure legends.

The following are the main guidelines about each section, according to the type of manuscript:

**Title Page**

The title page must contain all of the following items of information:

a) Title of the article, concise and informative, avoiding the use of superfluous terms and abbreviations; also avoid indicating the place and city where the study was conducted;

b) Abbreviated title (short title) to be stated at the top of all the pages with a maximum of 60 characters, counting the spaces;

c) The full name of each of the authors (first name and other surnames, with the last surname typed in bold-face font.

d) Department to which the authors are affiliated and/or definition of the institution or official service to which the study is tied;

e) Specific contribution of each author to the study;

f) Declaration of conflict of interest (write “nothing to declare” or a clear revelation of any interest of an economic or other nature that may cause embarrassment if it becomes known after publication of the article);

g) Name, address, telephone, fax and e-mail address of the corresponding author;

h) Source of financing or supplier of equipment and materials, if this were the case;

**ABSTRACT**

The abstracts (Portuguese and English) must contain a maximum of 250 words, avoiding the use of abbreviations. No words that identify the institution or city where the article was written must be put into the abstract, to facilitate blind reviewing. All the information that appears in the abstract must also appear in the article. The abstract must be structured according to the following description:

**Abstract of Original Article**

Introduction (optional): introduce the reader to the topic to be addressed in the article.

Aim: inform the initial hypotheses, if there are any. Define the main aim and inform only the most relevant secondary aims.

**Methods:** Inform the type of study design, contextual or local, the patients or participants (define the eligibility criteria, sample number, sample distribution criteria among groups, etc.), the interventions/exposures (describe characteristics, including methods of application, variables analyzed, duration, etc.), and the criteria for measuring the outcome, including the statistical analysis.

**Results:** Inform the main data, confidence intervals and significance, the statistics of the findings.

**Conclusions:** Present only those supported by the data of the study, and that contemplate the aims, as well as their practical application with equal emphasis on the positive and negative findings that have similar scientific merits.

**Abstract of Case Reports**

**Introduction** (optional): inform the reader about the topic to be addressed.

**Aim**: briefly state the aims of the report.

**Case Report**: report the case itself.

**Results:** Inform the main data related to resolution of the case.

**Conclusions:** Present only those supported by the data of the study, and that contemplate the aims and their application.

**Abstract of Reviews**

Introduction (optional): briefly report the central topic of the review, and justify why it was conducted.

**Aim:** Inform the aim of the review, indicating whether it especially emphasizes some factor, risk, prevention, diagnosis, treatment or prognosis.

**Sources of data:** Describe the sources of the research, defining the databases and years researched. Briefly inform the eligibility criteria of articles and methods of extraction and evaluation of the quality of information (in cases of Systematic Reviews).

**Summary of data:** Inform the main results of the research, whether they are quantitative or qualitative.

**Conclusions:** Present the conclusions and their clinical application.

After the summary of the original articles, case reports or reviews, include three to six key-words that will be used for indexing. Use terms of Medical Subject Headings (MeSH), available in http://www.nlm.nih.gov/mesh/ meshhome.html. When adequate descriptors are not available, it is possible to use free terms.

**Abstract of Protocolos**

Inform the reader about the topic to be addressed and state the aim of the protocol.

**ABBREVIATIONS**

These must be avoided, because they hamper comfortable reading of the text. When used, they must be defined when they are used for the first time. They must never appear in the title and abstracts.

**TEXTS**

The text of **original articles** must contain the following sections, each with its respective sub-title:

**Introduction:** Clear, objective, succinct, citing only references strictly related to the topic, and seeking to justify why the study was conducted. At the end of the introduction, the aims of the study must be clearly described.

**Materials and Methods:** Describe the population studies, sample and eligibility criteria; clearly define the variables and detail the statistical analysis; if necessary, include references about the methods used during the course of this section. Procedures, products and items of equipment used must be described in sufficient detail to allow reproduction of the study. Furthermore, they must contain details of the brand and place of manufacture. In case of studies with human beings and/or animals, it is mandatory to include a declaration that all the procedures were approved by the research ethics committee of the institution to which the authors belong. In the absence of this, approval must be obtained from another research ethics committee indicated by the National Commission of Research Ethics of the Ministry of Health.

**Results:** These must be presented clearly, objectively and in a logical sequence. The information contained in tables or figures must not be repeated in the text. The option to use graphs instead of tables with a large number of data depends on the authors and Editorial Board, which may suggest changes and adjustments with the purpose of making them better suited to the guidelines and specificities of the Revista de Odontologia do CRO-RJ (Rio de Janeiro Dental Journal).

**Discussion:** This must interpret the results and compare them with data previously described in the literature, emphasizing the new and important aspects of the study. Discuss the implications of the findings and their limitations, as well as the need for additional researches. Avoid repetition of the results and/or superimposition between results and discussion. The conclusions must be presented at the end of the discussion, and must respond to the aims of the study, by avoiding information if inferences were not supported by the findings. The authors must place equal emphasis on favorable and unfavorable findings that have similar scientific merits. Include recommendations, when these are pertinent.

The text of **case reports** must contain the following sections, each with its respective sub-title:

**Introduction**: Clear, objective, succinct, citing only references strictly related to the topic, and seeking to justify why the study was conducted. Describe the aims at the end of the introduction.

**Case Report**: must present details of the case and procedures for performing them. Describe the follow-up data and prognosis of the case, when pertinent. CRO suggests that cases without due conclusion should be avoided. Mention the Term of Free and Informed Consent.

**Discussion:** Discuss the diagnostic, therapeutic and technical criteria used, among other details about the case. Discuss the clinical implications of the findings and their limitations. The conclusions must be presented at the end of the discussion, and must respond to the aims of the study, by avoiding information if inferences were not supported by the findings. The authors must place equal emphasis on favorable and unfavorable findings that have similar scientific merits. Include recommendations, when these are pertinent.

The text of **review articles** must contain the following topics: - In case of **narrative reviews**, the following are suggested:

**Introduction:** clear and objective, in which the authors explain the importance of the review to clinical practice, in the light of dental literature. The introduction must conclude with the aims of the review.

**Materials and Methods/Data Source:** It is necessary to describe the methods of data selection and extraction, followed by Data Synthesis.

**Data Synthesis:** This data synthesis (result/discussion) must present all the pertinent information in rich detail.

**Conclusion:** The conclusion section must correlate the main ideas of the review with the possible clinical applications, limiting generalization to the domains of the review.

- In cases of **systematic reviews, with or without meta-analyses**, the authors must follow the PRISMA statement (http://www.prisma-statement.org/). These reviews must contain: **Introduction**: that demonstrates the pertinence of the subject and the existent controversy with respect to the topic. At the end of the introduction, the authors should raise the focal question of the review. **Materials and Methods**: must present the search strategy; eligibility criteria of the studies; risk of bias analysis of the included studies; data extraction, and when pertinent, the strategy used for quantitative data synthesis.

**Result**: must respond in an orderly manner to the data searched according to the methodological design with respect to the qualitative and quantitative synthesis of the primary studies included.

**Discussion**: must consider interpreting the results, emphasizing resolution of the controversies related to the topic, with this being directed towards answering the focal question of the review, showing whether or not there is need for further research. The limitations of the study must also be pointed out and envisage the external validity of the study (power of generalization of the data).

**Conclusion:** The conclusion section must correlate the main ideas of the review with the possible clinical applications.

**Acknowledgments**

These must be brief and objective; they should only mention the person or institutions that made a significant contribution to the study, butthat had not fulfilled the criteria of authorship.

**References**

The references must be formatted in the Vancouver style, also known as the Uniform Requirements style.

The bibliographic references must be numbered and ordered according to the order in which they appear in the text, in which they must be identified by the respective superscript Arabic numbers. To list the references, do not use the Word resource of end notes or footnotes.

Articles accepted for publication, but not yet published, may be cited provided that the name of the journal is indicated and that it is "in press". Unpublished observations and personal communications may not be cited as references. If it were imperative to include information of this type in the article, it must be followed by the observation "unpublished data" or "personal communication" in parentheses in the body of the article.

The titles of periodicals must be abbreviated as recommended in the Medicus Index; a list with their respective abbreviations may be obtained by means of the publication NLM "List of Serials Indexed for Online Users", available at the address http:// www.nlm.nih.gov/tsd/serials/lsiou.html.

As follows, we present some examples of the model adopted by the Revista Científica do CRO-RJ (Rio de Janeiro Dental Journal):

**Articles in periodicals:**

*1.* Up to six authors:

Vieira AR, Bayram M, Seymen F, Sencak RC, Lippert F, Modesto A. In Vitro Acid-Mediated Initial Dental Enamel Loss Is Associated with Genetic Variants Previously Linked to Caries Experience. Front Physiol. 2017 Feb 22;8:104. doi: 10.3389/fphys.2017.00104.

*2.* More than six authors:

da Silva Bastos Vde A, Freitas-Fernandes LB, Fidalgo TK, Martins C, Mattos CT, de Souza IP, et. al. Mother-to-child transmission of Streptococcus mutans: a systematic review and meta-analysis. J Dent. 2015 Feb;43(2):181-91. doi: 10.1016/j.jdent.2014.12.001.

*3.* Organization as author:

American Academy of Pediatrics. Clinical practice guideline. Diagnosis and management of childhood obstructive sleep apnea syndrome. Pediatrics 2012;130 (3):576-684.

*4.* Articles with electronic publication, not yet with printed publication:

Tavares Silva C, Calabrio IR, Serra-Negra JM, Fonseca- Gonçalves A, Maia LC. Knowledge of parents/guardians about nocturnal bruxism in children and adolescents. Cranio. 2016; Jun 24:1-5. [Epub ahead of print]

**Books:**

Andreasen JO, Andreasen FM. Textbook and color atlas of traumatic injuries to the teeth. 4ª ed. Copenhagen: Mosby. 2007.

Chapters of Books:

Pagel JF, Pegram GV. The role for the primary care physician in sleep medicine. In: Pagel JF, Pandi-Perumal SR, editors. Primary care sleep medicine. 2nd ed. New York: Springer; 2014.

Academic Studies:

BorkowskiMM. Infant sleep and feeding: a telephone survey of Hispanic Americans [dissertation]. MountPleasant(MI): Central Michigan University; 2002.

**CD-ROM:**

Soils. Geographica on CD ROM. [CD ROM]. Melbourne, Australia: Random House. 1999.

**Homepage/website:**

Integrative Medicine Center[Internet]. Houston: University of Texas, M. D. Anderson Cancer Center; c2017 [cited 2017 Mar 25]. Available from: https://www.mdanderson.org/patients- family/diagnosis-treatment/care-centers-clinics/integrative- medicine-center.html.

Ministry of Health Documents/Decrees and Laws:

1. Brazil. Decree 6.170, of July 25, 2007. States provisions about the rules relative to Transfers of resources from the Union by means of transfer agreements and contracts and makes other provisions. Diário Oficial, Brasília, 26 jul. 2007.

2. Brazil. Ministry of Health Health Care Secretary Department of Primary Care Política Nacional de Atenção Básica / Ministério da Saúde. Health Care Secretary Department of Primary Care Brasília, Ministério da Saúde, 2012. (Série E. Legislação em Saúde)

Presentation of Paper/Study?

Pierro VSS, Maia LC, Silva EM. Effect of pediatric syrups on roughness and erosion of enamel (abstract). 82nd. IADR General Session & Exhibition; 2004 Mar 10-13, Honolulu, Hawaii. J Dent Res 2004, 83 (Special Issue A): 896.

**Tables**

Each table must be presented on a separate page, numbered with a Arabic numeral (1, 2, 3, etc.), in the order of appearance in the text; with single spacing between lines, and contain a summarized but explanatory title. All the explanations must be presented in footnotes and not in the title, identified with superscript letters in alphabetical order. Do not underline or draw lines within the tables and do not use spaces to separate the columns. Do not use space on either side of the symbol ± or any other symbol.

**Figures (photographs, drawings, graphs, etc.)**

All the figures must be numbered with Arabic numerals (1, 2, 3, etc.), in order of appearance in the text. The title must be clear and objective, and must appear at the base of the Figure. All the explanations must be presented in the legends, including those about the abbreviations used. Figures reproduced from other previously published sources must indicate this condition in the legend, in addition to being accompanied by a letter of permission from the copyright holder. Photographs must not allow identification of the patient; masking the patient's eye region in the photograph may not provide sufficient protection. Should there be possibility of identification, it is mandatory to include a written term of free and informed consent to publication. Microphotographs must present internal scales and arrows in contrast with the background.

Illustrations in color are accepted for publication online, without additional cost to the authors. However, all the figures will be transformed to black and white in the printed version. If the authors consider it essential for a certain image to be in color, even in the printed version, the authors are requested to make special contact with the editors. Computer-generated images, such as graphs, must be attached in the form of files in the following formats: .jpg, .gif or .tif, with minimum resolution of 300 dpi. Graphs must preferably be presented in two dimensions. CRO will only accept

drawings, photographs or any illustrations that contain an adequate degree of resolution for the printed version of the journal.

**Figure Legends**

These must be presented on a separate page, duly identified with their respective numbers.

**Verification List**

As part of the submission process, authors are requested to indicate their agreement with the items listed as follows:

1. All the authors will sign and submit their agreement by means of a Copyright License Declaration (and end user license), and the content of their intellectual work will be their sole and exclusive responsibility.

2. The corresponding author must prepare, with the consent of the other authors, a letter of submission of the article to the Revista Científica do CRO-RJ (Rio de Janeiro Dental Journal).

3. The submission file (manuscript) must be sent as a Microsoft Word document.

4. The title page must contain all the information required, as specified in the guidelines to the authors.

5. The abstract and key words must be formatted and submitted in English and Portuguese, following the title page.

6. The entire text must be presented in double line spacing using 12-point Arial font, and using italics instead of underlining to indicate emphasis (except in e-mail addresses. All the tables, figures and legends must be numbered in the order in which they appear in the text; each of these must be placed on a separate page, after the bibliographic references at the end of the article.

7. The text must be in accordance with the demands of style and bibliography described in the publication guidelines.

8. The references must be presented in the so-called Vancouver style, and numbered consecutively in the order in which they appear in the text.

9. Information about approval of the study by a research ethics committee must be clearly presented in the text, in the Methods section, and must be sent as an attachment.

10 All the internet addresses presented in the text must be active and ready to be clicked on.

11.Documentary proof of potential Conflict of Interest must be signed by all the authors and sent as an attachment during the submission process.

**Final Considerations:**

**Anti-Plagiarism Policy**

The Revista Científica do CRO-RJ (Rio de Janeiro Dental Journal) uses a system to detect plagiarism (available at http//:www.plagium.com/pt/detectordeplagio). When submitting an article to the journal, the authors accept that the work will be digitized in the mentioned program at the time of submission, and in the case of acceptance, prior to publication.

**Ethics Policy of the Publication**

All submissions will be subject to the condition that the articles have not been previously published, and have also not been simultaneously submitted to another medium of disclosure. All the authors must have read and approved the content and all the authors have declared possible conflicts of interest. The article must follow the ethical principles

of the Revista Científica do CRO-RJ (Rio de Janeiro Dental Journal), and they must also comply with the international standards of research ethics in studies with human beings and animals.

**Conflict of interest and financial aid**

The Revista Científica do CRO-RJ (Rio de Janeiro Dental Journal) requires all authors to declare potential conflicts of interest. Any interest or relationship, financial or other type that may be perceived as having influenced the results of a study, and the objectivity of an author, is considered a potential source of conflict of interests, and must be declared. The potential sources of conflict of interest include, but are not limited to, rights arising from patent rights or ownership of shares, membership of a board of directors, membership of an advisory board or committee of a company, and receiving advice or speaking fees from a company. If the authors are not sure whether a past or present affiliation or relationship needs to be divulged in the manuscript, please contact the editorial office at http://revcientifica.cro-rj.org.br

The existence of conflict of interests does not exclude publication.

The corresponding author is responsible for ensuring that all the authors fulfill and sign the copyright license declaration and other mandatory documents at the time of submission.

**Confirmation of sending the documents**

After submission, the corresponding author will receive an e-mail to confirm receipt of the article. If this e-mail of confirmation is not received after 24 hours, please contact the Revista Científica do CRO-RJ (Rio de Janeiro Dental Journal) by e-mail: revistacientifica@cro-rj.org.br. The error may have been caused by some type of spam filtering in the e-mail server.

**Updating the status of the article**

The initial process of evaluating the article may take up to 60 days, counted from the date of its submission. Should this period have expired, you may contact the Editorial Board to verify the present status. The Revista Científica do CRO-RJ (Rio de Janeiro Dental Journal) will inform you by e-mail, once a decision has been made. One of the following possibilities will be indicated in the reply e-mail: 1. Make adjustments to suit the guidelines and Re-submit; 2. Accepted; 3. Minor adjustments required; 4. Major adjustments required; 5. Rejected. In the latter case, the article will be summarily refused and cannot be re-submitted to the journal.

**Submission of Revised Articles**

The revised manuscripts must be sent within 2 months after notifying the authors about the conditional acceptance (minor or major adjustments). All the revisions must be accompanied by a letter of response to the reviewers, in which each question or suggestion made by the reviewers must be answered in sequential order. The letter must a) detail the author's reply, point by point, to each of the reviewers' comments, and b) a revised manuscript, highlighting in color, exactly what has been changed in the manuscript after revision. In addition to this, any need for adjustment or correction of the manuscript is the sole responsibility of the authors.

The authors must supply an official certificate of revision of the English language in the act of submitting the revised manuscript. The authors will be fully responsible for the costs of translation/revision of the English language.