

GARRÉ'S OSTEOMYELITIS: A CASE REPORT WITH A 6-MONTH FOLLOW-UP

Bárbara de Oliveira **Nogueira**¹, Hiorran Coelho Almeida **Matos**², Karla Magnan **Miyahira**², José Alexandre da Rocha **Curvelo**¹, Maria Elisa Rangel **Janini**^{1*}

¹Department of Oral Pathology and Oral Diagnosis, Faculty of Dentistry, Federal University of Rio de Janeiro, RJ, Brazil.

²Department of Pediatric Dentistry and Orthodontics, School of Dentistry, Federal University of Rio de Janeiro, RJ, Brazil.

Palavras-chave: Osteomielite de Garré. Tomografia Computadorizada. Antibioticoterapia. Remodelação óssea.

RESUMO

Introdução: A osteomielite de Garré é um tipo raro e crônico de infecção óssea associado a periostite proliferativa que induz neoformação óssea reacional. **Objetivo:** relatar o caso clínico de osteomielite de Garré em uma paciente jovem tratada com sucesso. **Relato de caso:** Paciente do gênero feminino, 11 anos compareceu ao serviço odontológico com queixa de aumento de volume em borda de mandíbula acompanhada de dor e assimetria facial. A tomografia computadorizada revelou extensa destruição dentária associada a lesão periapical e a presença de várias laminações ósseas radiopacas paralelas ao cortical da mandíbula, sugerindo o diagnóstico de osteomielite de Garré. O caso foi tratado com a remoção do elemento dentário associado a antibioticoterapia, o que resolveu completamente a infecção e diminuiu a assimetria facial conforme constatado após 6 meses de preservação. **Conclusão:** Uma vez estabelecido o diagnóstico de osteomielite de Garré, e a infecção adequadamente tratada, o prognóstico tende a ser extremamente favorável e a remodelação óssea deve ocorrer continuamente até que a superfície retorne à sua anatomia normal.

Keywords: Garré's osteomyelitis. Computed Tomography. Antibiotic Therapy. Bone Remodeling.

ABSTRACT

Introduction: Garré's osteomyelitis is a rare, chronic infection associated with proliferative periostitis that induces reactional bone neoformation. **Objective:** To report the clinical case of successful treatment of Garré's osteomyelitis in a young patient. **Case report:** An 11-year-old girl visited a dental clinic with complaints of volume increase in the mandibular border accompanied by pain and facial asymmetry. Computed tomography revealed extensive tooth destruction, a periapical lesion, and several radiopaque bone laminations parallel to the mandible cortex, all findings suggestive of Garré's osteomyelitis. The patient was treated by tooth removal and antibiotic therapy, and the condition was completely resolved, with decreased facial asymmetry at the 6-month follow up. **Conclusion:** Once the diagnosis of Garré's osteomyelitis is established and proper treatment is provided, the prognosis tends to be extremely favorable and bone remodeling should be considered until the affected surface returns to its normal anatomy.

Submitted: october 15, 2018
Modification: november 8, 2018
Accepted: november 13, 2018

*Correspondence to:

Maria Elisa Rangel Janini
Address: Rua Rodolpho Paulo Rocco
325, Cidade Universitária, Rio de
Janeiro, Brasil, CEP: 21941-913
Telephone number: +55 (21) 3938-2071
Email: elisajanini@globo.com

INTRODUCTION

Garré's osteomyelitis is a chronic osteal infection, also known as ossifying periostitis. This condition is also referred to as osteomyelitis with proliferative periostitis, ossifying periostitis, non-suppurative ossifying periostitis, Garré's periostitis, and perimandibular ossification; its etiology or pathophysiology are still under speculation.¹⁻³

Garré's osteomyelitis presents as an infection with periosteal reaction that induces new bone formation. It affects children and young adults, with an average onset age of 13 years. It mostly occurs in the region of the mandibular premolars and molars, but it can also affect the maxilla and metaphysis of long bones such as the tibia and femur.^{1,4-6} The majority of

cases originate from periapical inflammatory disorders associated with dental cavities, but other possible causes include periodontal infections, fractures, vestibular bifurcation cysts, and non-odontogenic infections.^{5,7} Clinically, patients usually present asymptomatic facial asymmetry caused by a localized swelling over the mandibular margin, with normal or slightly erythematous skin. It can be associated with pain, regional lymphadenopathy, trismus, and fever. The condition is predominantly unilateral, although reports of multiple quadrants affected are present in the literature. Typically, the oral mucosa remains unaltered.^{1,5,8,9}

Clinical and radiographic examinations are fundamental for the diagnosis of Garrè's osteomyelitis. Occlusal and panoramic radiographs, as well as computed tomography (CT) can be successfully used for diagnosis. Radiological findings include new bone formation that shows a pattern of parallel radiopaque bone laminations along the underlying cortical bone, in a shape that resembles onion peels.^{5,10} Bone sequestration or osteolysis may present as radiolucent areas within the neoformed bone. Because of the pattern of periosteal bone neoformation, other diseases should be considered in the differential diagnosis, such as Ewing's sarcoma, fibrous dysplasia, osteogenic sarcoma, osteoma, metastatic neuroblastoma, infantile cortical hyperostosis, congenital syphilis Langerhans cells histiocytosis and Caffey disease.^{1,11,12}

Garrè's osteomyelitis is typically treated by eliminating the odontogenic cause of the infection by extraction or endodontic treatment of the evolved tooth. To accelerate and improve infection resolution, the use of antibiotic therapy with pathogen identification, drainage, removal of osseous tissue, and debridement may also be used.^{1,13} After the infection is resolved, bone layers are expected to consolidate within 6-12 weeks with the aid of the surrounding musculature, which will contribute to the bone remodeling. The prognosis is often favorable when the cause is completely removed and antibiotic therapy is administered.⁵

CASE REPORT

A 11-year-old black female patient was brought to the stomatology service of the Federal University of Rio de Janeiro, with complaints of toothache and facial asymmetry. The patient presented a large cavity in her permanent lower first molar, and extra-oral examination revealed increased volume on the left side of the mandible with firm consistency and slight skin color alteration (Figure 1); however, no cervical lymph node was detected. On intraoral examination, the patient showed an extensive cavity on the left mandibular first molar, extensive destruction of the dental crown that reached root furcation, and slight bulging of the vestibular



Figure 1: Frontal view of the patient showing well-delimited swelling in left side of the jaw (arrow).

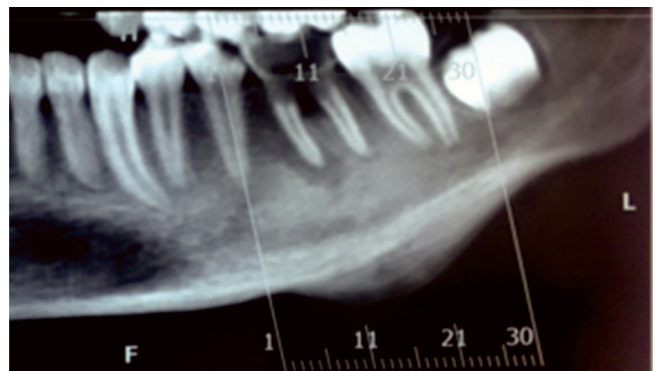


Figure 2: Panoramic reconstruction of cone beam CT showing an extensive radiolucent image associated with the first mandibular molar, with bone rarefaction and radiopaque bone laminations on the cortical surface resembling "onion peels."

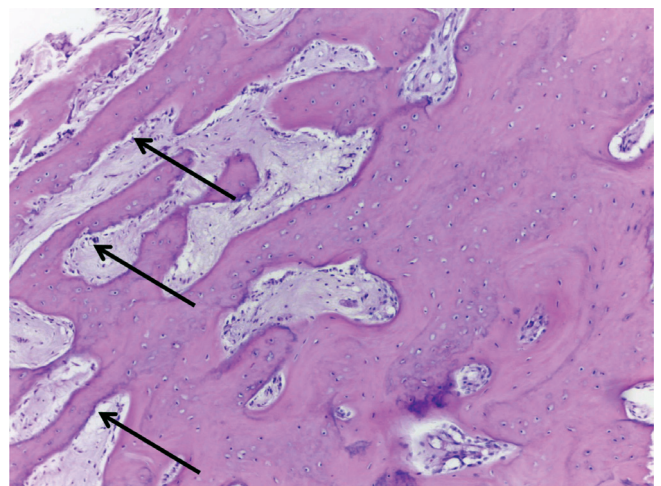


Figure 3: Histopathological analysis shows parallel rows of richly cellularized reactive trabecular bone extending from the cortical surface (thin arrows).

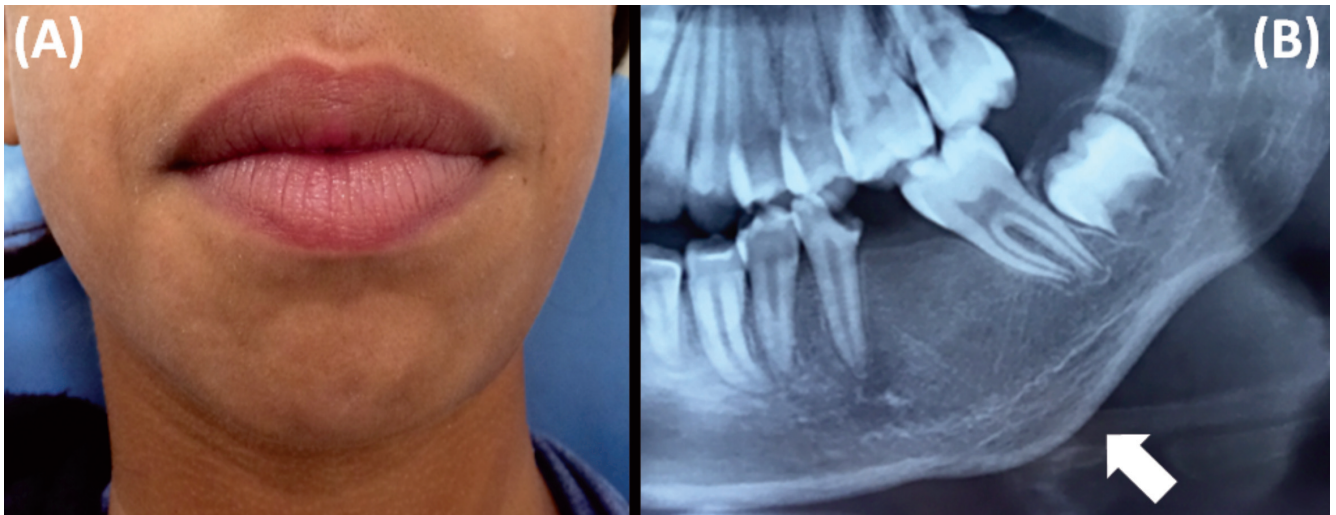

Figure 4: (A) Frontal view of the patient at the 6-month follow-up showing no facial asymmetry. (B) Panoramic radiographic image evidencing significant bone remodeling in the mandible ridge (arrow).

alveolar ridge. CT revealed an extensive periapical lesion evidenced by a well-delimited radiolucent area involving the apex of the compromised tooth, as well as new bone formation among the cortical border presented as radiopaque laminations that resembled onion peels. The findings were suggestive of Garrè's osteomyelitis (Figure 2).

Treatment involved the removal of the left first mandibular molar, followed by extensive curettage of the adjacent alveolar bone and antibiotic therapy with amoxicillin 1.5 g/day for 10 days. The collected material was sent for histopathological analysis, which showed parallel rows of highly cellular and reactive trabecular bone (Figure 3), confirming the diagnosis of Garrè's osteomyelitis. After treatment, the signs and symptoms of the infection were completely resolved and the process of bone neoformation had initiated. Follow-up was conducted at 6 months and the decrease in facial asymmetry and bone structure remodeling was evidenced by radiographic and imaging records (Figure 4).

The patient's legal guardian was duly advised and agreed to the terms of permission to publish her case according to free and informed consent.

DISCUSSION

Garrè's osteomyelitis is a rare pathological condition that mostly affects young patients with a mean age of 13 years. Several hypotheses have been made to explain the high prevalence of the condition in children and adolescents. Some hypothesis postulate that the high periosteum activity in young individuals can react strongly against low virulence infections or that an imbalance between the osteoblastic and osteoclastic activities may enable the predominance of osteoblastic activity.^{1-6,14}

In most cases, Garrè's osteomyelitis originates from lesions of mandibular permanent molars, as reported in the present study. The extent of the lesion as well as its clinical symptoms depend on microbiological factors such as the degree of virulence of the microorganism, and on the immunological state of the host.^{1,6,14} Some studies suggest that because the mandibular first molars are the first permanent teeth to erupt, they become more susceptible to cariogenic agents, and therefore are more frequently involved in the disease.⁴ Nevertheless, a few cases of Garrè's osteomyelitis caused by impacted third molars that can lead to a very low-grade infection or inflammation able to trigger new periosteal bone formation have also been reported in pre-teen patients.¹⁵

The case of Garrè's osteomyelitis presented here was focal and unilateral, which is the most usual presentation of this condition. However, a multiple quadrant situation may also be observed in a small percentage of cases, according to a previous study.¹⁶

Radiographic examinations are essential to reach the diagnosis of Garrè's osteomyelitis. Among the available methods, CT has many advantages and is an effective tool for assessing the extent and contour of lesions, as well as the involvement of surrounding structures. In fact, the existence of a communication channel between an infected tooth and bone expansion observed on CT can be used as additional criteria to diagnose Garrè's osteomyelitis caused by endodontic infection.¹⁷ In the present case, the initial CT revealed areas of radiopaque bone lamellae parallel to each other and to the surface of the cortical bone of the mandible. This pattern is often described by the literature as "onion peels," and is one of the most consistent radiographic characteristic of Garrè's osteomyelitis. These laminations

may range from 1 to 12 lamellae, and are often separated by radiolucent areas.⁵ Although the diagnosis can be established by clinical and radiographic examination alone, in this case, the authors decided to send any collected material for histopathological analysis, and that allowed a definitive diagnosis.

Histopathological descriptions of Garré's osteomyelitis present in the literature are quite similar to the microscopic features observed in this case. The literature describes the histological aspect of Garré's osteomyelitis as parallel rows of highly cellular reactive trabecular bone surrounded by osteoblasts. The rows are often parallel to each other and perpendicular to the cortical surface, with relatively non-inflamed fibrous connective tissue between them. The literature also states that when bone sequestration is present, typical histological features of bone necrosis can be observed.^{1,5}

The treatment of Garré's osteomyelitis typically involves eliminating the infection either by tooth removal or an endodontic approach.^{1,5} In this case report, tooth removal associated with antibiotic therapy was selected due to the high destruction of the dental structure and severity of the infection dissemination. The 6-month follow-up included panoramic radiography at different moments, allowing the evaluation of alveolar bone neoformation, as well as the remodeling of the lower mandibular border.

Garré osteomyelitis has predilection for young patients and, if untreated, can lead to facial asymmetry and discomfort for the patient. Diagnosis can be achieved through clinical and radiographic examination alone, although in this case, we proved the usefulness of confirmation by histopathological analysis. The authors chose to perform histological evaluation because it is very important in cases where the classic presence of pulp necrosis with a periapical lesion and well-defined bone neoformation forming layers on the cortical surface is not evident. Thus, histological analysis helps exclude all other differential diagnoses. Finally, this case report confirms previous findings that when treatment is correctly performed, prognosis can be favorable and bone remodeling should be considered until the bone surface returns to its normal anatomy.

REFERENCES

1- Silva, MM, Castro, AL, Castro, EVFL, Coclete, GA. Garré's osteomyelitis. An update and report of two new cases. *Rev. bras. odontol.* 2009 Jan/Jun; 66 (1): 8-11.
2- Jacobson, HLJ, Baumgartner, JC, Marshall, JG, et al. Proliferative periodontitis of Garré: Report of a case. *Oral Surg. Oral Med. Oral Pathol. Oral Radiol. Endod.* 2002 Jul; 94 (1): 111-114.
3- Moares, FB, Motta TMV, A Severin AA, et al. Garré's sclerosing osteomyelitis: case report. *Rev Bras Ortop.* 2014; 49 (4): 401-404.

4- Zand, V, Lotfi, M, Vosoughhosseini, S. Proliferative Periostitis: A Case Report. *J Endod.* 2008; 34: 481-483.
5- Neville BW, Damm OD, Allen CM, Bouquot JE. *Oral and maxillofacial pathology.* 2^a ed. Philadelphia: Saunders, 2009.
6- Kannan, SK, Sandhya, G, Selva-rant, R. Periostitis ossificans (Garre's osteomyelitis) radiographic study and two cases. *Int. J. Pediatric Dent.*, 2006 Jan; 16 (1): 59-64.
7- Sugaya, NN, Pedote, CM, Birman, EG. General considerations on the "osteomyelitis" of Garré: report of a case. *Rev. Fac. Odontol. F. Z. L.* 1991 Jul / Dec; 3 (2): 99-105.
8- Castro, FPSS, Guaré, RO Mathias, RS. Garré Osteomyelitis: general considerations and clinical case report. *Ver. ABO Nac.* 2001 Aug / Sep; 9 (4): 247-250.
9- Kadom N, Egloff A, Obeid G, Bandarkar A, Vezina G. Juvenile mandibular chronic osteomyelitis: multimodality imaging findings. *Oral Surg Oral Med Oral Pathol Oral Radiol Endod.* 2011; 111 (3): 38-43.
10- Nortjé, CJ, Wood, RE, Grotepass, F. Periostitis ossificans versus Garré's osteomyelitis. Part II: Radiologic analysis of 93 cases in the jaws. *Oral Surg Oral Med Oral Pathol.* 1988 Aug; 66 (2): 249-260.
11- Belli, E, Matteini, C, Andreano, T. Sclerosing osteomyelitis of Garré periostitis ossificans. *J. Craniofac. Surg.* 2002 Nov; 13 (6): 765-768.
12 - Akgül HM, Çağlayan F, Günen Yılmaz S, Derindağ G. Garré's Osteomyelitis of the Mandible Caused by Infected Tooth. *Case Rep Dent.* 2018 Jul; 8;(18):1-4
13- Hudson, JW. Osteomyelitis of the jaws: a 50-year perspective. *J. Oral Maxillofac. Surg.* 1993 Dec; 51 (12): 1294-1301.
14- Suei Y, Taguchi A, Tanimoto K. Diagnosis and classification of mandibular osteomyelitis. *Oral Surg Oral Med Oral Pathol Oral Radiol Endod.* 2005; 100: 207-14.
15- Park J, Myoung H. Chronic suppurative osteomyelitis with proliferative periostitis related to a fully impacted third molar germ: a report of two cases. *J Korean Assoc Oral Maxillofac Surg.* 2016 Aug; 42(4):215-20.
16- Eisenbud, L, Miller, J, Roberts, IL. Garré's proliferative periostitis occurring simultaneously in four quadrants of the jaws. *Oral Surg Oral Med Oral Pathol.* 1981 Feb; 51 (2): 172-178
17- Brazão-Silva, MT & Pinheiro TN. The So-called Garré's Osteomyelitis of Jaws and the Pivotal Utility of Computed Tomography Scan. *Contemp Clin Dent.* 2017 Oct-Dec; 8(4): 645-646.