

CANDIDA spp. IN LINEAR GINGIVAL ERYTHEMA LESIONS IN HIV- INFECTED CHILDREN: REPORT OF SIX CASES

Maristela Barbosa **Portela**¹, Daniella Ferraz **Cerqueira**², Renato Vieira de **Paiva**¹, Adrielle Mangabeira **Santos**², Tamiris Ramos **Vargas**¹, Gloria Fernanda **Castro**³

¹ Department of Dental Clinics, Pediatric Dentistry, Universidade Federal Fluminense – UFF, Niterói, RJ, Brazil

² Universidade Federal do Rio de Janeiro - UFRJ, Rio de Janeiro, RJ, Brazil

³ Department of Pediatric Dentistry and Orthodontics, Universidade Federal do Rio de Janeiro - UFRJ, Rio de Janeiro, RJ, Brazil

Palavras-chave: Crianças. Aids. Manifestações orais. Dentista pediátrico.

RESUMO

Introdução: O eritema gengival linear (LGE), normalmente referido como gengivite do HIV, é a forma mais comum de doença periodontal presente em indivíduos infectados pelo HIV. Recentemente, estas lesões foram consideradas como uma possível forma de candidíase oral eritematosa causada por *Candida albicans*. Outras espécies, como *C. tropicalis*, *C. stellatoidea*, *C. krusei*, *C. parapsilosis*, *C. glabrata* e *C. dubliniensis* também foram identificadas em indivíduos infectados pelo HIV associadas ao LGE. **Objetivo:** O presente artigo mostra a presença de lesões típicas de LGE em seis crianças infectadas pelo HIV e também investigou o agente etiológico das lesões orais através de exames microbiológicos, correlacionando o LGE com as condições sistêmicas dos pacientes. **Case report:** Análises microbiológicas mostraram crescimento positivo para *Candida spp* em todos os pacientes, os quais possuíam imunossupressão grave. Adicionalmente, a regressão total das lesões foi observada após medicação tópica antifúngica. **Conclusão:** A presença de LGE em pacientes pediátricos com AIDS pode ser um marcador preditivo da progressão

Keywords: Children. Aids. Oral Manifestations. Pediatric Dentistry.

ABSTRACT:

Introduction: Linear gingival erythema (LGE), formally referred to as HIV-gingivitis, is the most common form of HIV-associated periodontal disease in HIV-infected individuals. These lesions have been recently evaluated as a possible form of erythematous oral candidosis, mainly caused by *Candida albicans*. Other species such as *C. tropicalis*, *C. stellatoidea*, *C. krusei*, *C. parapsilosis*, *C. glabrata* and *C. dubliniensis*, have also been identified in some HIV-infected subjects. **Objective:** This case report reveals the presence of typical LGE lesions in six HIV-infected children, and also investigates the etiologic agent through microbiological exams and correlates this oral manifestation with the patients' systemic conditions. **Case report:** Microbiological analyses showed growth for *Candida spp* in all patients; all of whom had severe immunosuppression. However, the regression of lesions was noted after antifungal medication. **Conclusion:** The presence of LGE in pediatric patients with AIDS may be a predictive marker in the progression of AIDS or it may be the first clinical manifestation of HIV infection in children. Hence it is important for dentists to be aware of such lesions.

Submitted: March 27, 2018

Modification: May 16, 2018

Accepted: June 14, 2018

*Correspondence to:

Dra. Maristela Barbosa Portela
Address: Rua Beberibe, 273, apt. 201,
Ricardo de Albuquerque
Rio de Janeiro/RJ Cep: 21640-070, Brazil
Telephone number: (55) (21) 31061231,
E-mail: mbportela@hotmail.com

INTRODUCTION

Oral candidiasis (OC) is the most common opportunistic infection seen in HIV-infected children¹⁻⁴ and it is presented as pseudomembranous and erythematous candidiasis, and angular cheilitis. Linear gingival erythema (LGE),

which was formally referred to as HIV-gingivitis, is the most common form of HIV-associated periodontal disease in the HIV-infected population. It is considered to be resistant to conventional plaque-removal therapies, and is known as a lesion of

fungal etiology.^{1,5,6} It is characterized by a fiery, linear band, 2 to 3 mm wide, along the marginal gingival accompanied by petechiae-like or diffuse red lesions on the attached gingival and oral mucosa and may be accompanied by bleeding. The prevalence of this lesion varies widely in different studies, ranging from 0 to 48%;^{1,2,3,7,8,9} moreover, many of the LGEs may have been misdiagnosed as gingivitis. Mucosal candidiasis is an infection of fungal etiology mainly caused by *Candida albicans*,¹ although other species such as *C. tropicalis*, *C. stellatoidea*, *C. krusei*, *C. parapsilosis*, and *C. glabrata*¹⁰ have been associated with this infection. Also, *C. dubliniensis* has been identified in HIV-infected subjects and two studies^{11,12} have demonstrated the presence of this yeast in positive cultures for *C. albicans* in HIV-infected children who had severe immunosuppression. Velegraki et al.¹³ presented case reports in which there was strong evidence that linear gingival erythema was of candidal origin. These lesions were clinically evaluated as a possible form of erythematous oral candidiasis. Microbiological exams (direct microscopic examination, culture, biochemical and serological tests) identified *C. albicans* in three pediatric patients and *C. dubliniensis* in one patient. In addition, all lesions healed on antimycotic treatment. The objective of this case report is to describe six cases of HIV-infected children with linear gingival erythema lesions. Also we investigated the etiologic agent and correlated these oral manifestations with the patients' systemic conditions.

CASE REPORT

Six vertically HIV-infected children, who were all patients of a Pediatric AIDS Outpatients Clinic of Universidade Federal do Rio de Janeiro - UFRJ, Rio de Janeiro, Brazil, attended by the staff of The Dental Program for Oral Health, were diagnosed as having oral lesions during routine exams.

All the children had definitive diagnosis for HIV infection confirmed by 2 positive ELISA tests and 1 positive Western Blot. The examinations were performed by a single trained pediatric dentist, after supervised toothbrushing with fluoridated toothpaste, followed by topical fluoride application (2.0 % sodium fluoride). The intraoral exam revealed the presence of a linear gingival erythema and the lesions from all children were resistant to conventional plaque-removal therapy (Figure 1).

The other oral manifestations found in the patients were bilateral submandibular gland enlargement. Patient 1 presented pseudomembranous candidiasis in the jugal mucosa and dorsum of the tongue, while patient 3 presented

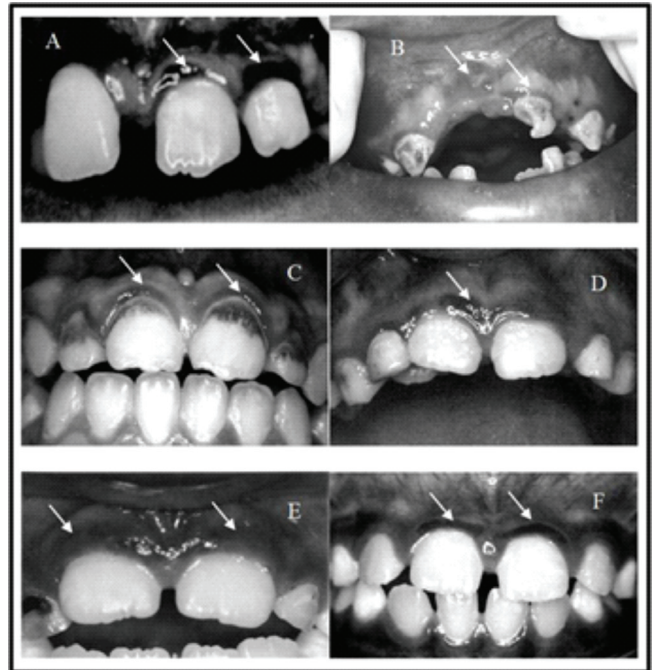


Figure 1: Clinical aspects of the oral lesions when the clinical specimens were collected for mycological investigation in six HIV-infected children. In all oral lesions a fiery, linear band, 2 to 3 mm wide, along the marginal gingival can be seen (A - patient 1; B - patient 2; C - patient 3; D - patient 4; E - patient 5; F - patient 6).

erythematous candidiasis in the hard palate mucosa.

All data regarding the patient's personal information, medical history and laboratorial exams (the closest ones to sample collection) such as immunological and clinical classification (CDC classification),¹⁴ percentage of CD4-positive cells and viral load were collected from their medical records (Table 1).

The samples for mycological investigation were obtained by rubbing the lesion (LGE) with a sterilized microbrush on which was then transferred to a test tube. Also they were smeared on CHROMagar Candida? (Becton Dickinson GmbH, Heidelberg, Germany) plates for culture and incubated at 37°C. This culture medium allows a presumptive identification of common clinical isolates of *Candida* through the production of different colored colonies.¹⁵ Each different colored colony was then identified through biochemical tests of sugar assimilation and fermentation, using the API 20C system (Biomerieux, Marcy L'Etoile, France). Plates with positive growth were classified according to Lamey et al¹⁶ into mild growth (< 10 cfu/ml of saliva), moderate (11-49 cfu/ml) and strong (>50 cfu/ml). The results of the quantification and identification of *Candida* spp. from LGE lesions, as well as the relation with their systemic conditions, can be seen in Table 2.

Table 1: Patient's medical information and oral examination data

Patient	CDC Classification	Age (years) / Sex	Race	ELG Localization (buccal or lingual gingiva)	Orofacial lesions	Anti-retroviral therapy
1	C3	12/ F	Caucasian	Anterior maxillary/mandibular and 16,26 (lingual)	Pseudomembranous candidiasis	Yes
2	C3	7/ M	Caucasian	All teeth, except the 31,41	-	Yes
3	C3	10/ M	Afro- escendent	Anterior maxillary/mandibular	Erythematous Candidiasis	Yes
4	B2	4/ F	Caucasian	Anterior maxillary teeth (buccal)	-	Yes
5	C2	11/ F	Afro- escendent	21 (buccal)	-	Yes
6	C3	11/ M	Afro- escendent	11,21 (buccal)	-	Yes

Note: N- no symptoms; A- mild symptoms; B-moderate symptoms; C-severe symptoms; 1-absence of immunosuppression; 2- moderate immunosuppression; 3- severe immunosuppression. **Source:** 1994 Revised classification system for Human Immunodeficiency Virus infection in children less than 13 years of age (CDC)¹⁴

Table 2: Relationship between patients' systemic conditions and the level of *Candida spp* present in the linear gingival erythema lesions

Patient	Clinical Classification	Viral load	CD4 cells count (%)	Isolates of <i>Candida</i>	Growth classification
1	C3	170,000	1.0	<i>C. albicans</i>	Mild
2	C3	66,000	3.0	<i>C. albicans</i>	Strong
3	C3	110,000	12,0	<i>C. albicans</i> / <i>C. tropicalis</i>	Strong/Strong
4	B3	37,000	18.5	<i>C. albicans</i>	Mild
5	C2	280,000	27.0	<i>C. dubliniensis</i>	Strong
6	C3	900	35.0	<i>C. albicans</i>	Strong

Note: N- no symptoms; A- mild symptoms; B-moderate symptoms; C-severe symptoms (AIDS); 1-absence of immunosuppression; 2- moderate immunosuppression; 3- severe immunosuppression (AIDS). **Source:** 1994 Revised classification system for Human Immunodeficiency Virus infection in children less than 13 years of age (CDC)¹⁴

The mycological investigation demonstrated the presence of *Candida spp* in all LGE lesions. The patients were referred to their clinicians to have the most appropriate antifungal therapy prescribed and they also received oral hygiene and dietary instructions. Those with dental needs were referred to the pediatric dental clinic of the same university. There was a regression of all lesions after the use of topical antifungal treatment [Daktarin® oral gel – Miconazole (Jansen–Cilag Farmacêutica LTDA, São Paulo, Brazil)] for 7 days. Patients were placed under periodical follow up for maintenance of oral health for 8 years. During this time, patients were introduced to antiretroviral HAART therapy and were also followed-up medically.

DISCUSSION

In these six case reports, the fact that all patients presented typical linear gingival erythema lesions, which were resistant to conventional plaque-removal therapies, led to a microbiological investigation. This investigation provided strong evidence that LGE in HIV-infected children may be considered of fungal etiology, since *Candida spp* was isolated from all LGE lesions. These findings corroborate the study of Velegraki et al¹³ in which HIV-pediatric patients presented LGE with positive cultures for *Candida spp*.¹³ They are also in agreement with the consulted literature which classifies LGE as a lesion of fungal etiology.^{1,5,6}

Candida albicans, which was encountered in five of the six patients, was the most frequent species isolated, confirming that this yeast is the main etiologic agent of mucosal candidiasis.¹ One patient presented a mixed culture of *C. albicans* and *C. tropicalis*, confirming the association of other species rather than only *C. albicans* isolates with oral candidiasis.¹⁰ Another patient exhibited positive growth for *Candida dubliniensis* indicating that this species is also present in the pediatric HIV seropositive population.^{12,13} Portela et al¹⁷ also demonstrated, the presence of *Candida dubliniensis* in subgingival sites of HIV-positive children, indicating that this species has emerged as another pathogen noted for its *in vitro* potential for azole resistance and its enhanced *in vitro* adherence to human buccal epithelial cells.

The patients' medical history showed that all patients with LGE had AIDS disease, according to the CDC classification,¹⁴ and presented severe clinical signs and symptoms and/or severe immunosuppression. Castro et al⁸ studied the correlation between oral manifestations and the clinical/immunological classification of HIV-infected children, which demonstrated that patients who were severely debilitated (high viral load and low CD4 percentage) presented oral lesions such as linear gingival erythema. Similar results were also observed in HIV-seropositive adults, demonstrating a trend for more LGE lesions with lower CD4+ cells.¹⁸

Other orofacial lesions associated to HIV-infection, such as erythematous and pseudomembranous candidiasis and hairy leukoplakia, are considered markers for immunosuppression and AIDS.¹⁹⁻²¹ The present case also revealed that all patients who had LGE presented severe signs and symptoms of immunosuppression, which may suggest that, this lesion might be considered a prognostic indicator of HIV-infection.

The patients were referred to their clinicians, who could prescribe the most appropriate antimycotic treatment, due to the fact that some antifungals may have a cross-reaction with some antiretrovirals. One example is the metabolism process for the elimination of ketoconazole and AZT (zidovudine), which is dependent on the cytochrome-C cellular system, unabling the concomitant prescription of both medications.

In conclusion, all clinicians that treat HIV pediatric patients need to consider that an oral examination is an essential component for early recognition of disease progression, because many oral lesions may occur as one of first clinical signs and symptoms of HIV-infection in patients. The findings in this case report may suggest that the presence of linear gingival erythema lesions should be considered a marker in the progression of HIV-infection in a pediatric population. Thus, further studies should be conducted to evaluate the prognosis of this lesion in HIV-infected children.

REFERENCES

- 1- Ramos-Gomez FJ. Classification, diagnostic criteria, and treatment recommendations for orofacial manifestations and in HIV- infected children. J Clin Pediatr Dent 1999; 23: 85-89.
- 2- Portela MB, Ribeiro IP, Castro GF, Souza, IP. Oral dental profile of HIV-infected children from Rio de Janeiro - Brazil. J Dent Res 2000; special issue: 79:480.
- 3-Santos LC, Castro GF, Souza IPR, Oliveira RH. Oral manifestations related to immunosuppression degree in HIV-positive children. Braz Dent J 2001; 12: 135-138.
- 4-Patton LL. Current strategies for prevention of oral manifestations of human immunodeficiency virus. Oral Surg Oral Med Oral Pathol Oral Radiol. 2016 Jan;121(1):29-38.
- 5-Lamster IB, Grbic JT, Mitchell-Lewis DA, Begg MD, Mitchell A. New concepts regarding the pathogenesis of periodontal diseases in HIV infection. Ann Periodontol 1998; 3: 62-75.
- 6-Holmstrup P, Westergaard J. HIV infection and periodontal diseases. Periodontology 2000; 18: 37-46.
- 7-Castro GF, Souza IPR, Fonseca, R. Frequency of oral manifestations in HIV infected children. J Dent Res 1999; 78: 1026, abstract B-260.
- 8-Castro GF, Portela MB, Esteves C. ET AL. Oral manifestations and their correlation with clinical/immunological classification in HIV+ children. J Dent Res 2000; 79 (Special Issue, abstr. 2692):480.
- 9-Kumar RK, Mohan G, Reddy NV, Rao VA, Shameer M, Christopher A. Associated oral lesions in human immunodeficiency virus infected children of age 1 to 14 years in antiretroviral therapy centers in Tamil Nadu. Contemp Clin Dent. 2013 Oct;4(4):467-71.
- 10 Baumgartner C, Freydiere AM, Gille Y. Direct Identification and recognition of yeast species from clinical material by using albicans ID and CHROMagar Candida plates. J Clin Microbiol 1996; 34: 454-6.
- 11- Meiller TF, Jabra-Rizk MA, Baqui AMA, et al. Oral *Candida dubliniensis* as a clinically important species in HIV-seropositive patients in United States. Oral Surg Oral Med Oral Pathol Oral Radiol Oral Endod 1999; 88: 573-580.
- 12-Brown DM, Jabra-Rizk MA, Falkler WA, Baqui AA, Meiller TF. Identification of *Candida dubliniensis* in a study of HIV-seropositive pediatric dental patients. Pediatr Dent 2000; 22 (3): 234-38.
- 13-Velegriaki A, Nicolatou O, Theodoridou M, Mostrou G, Legakis NJ. Paediatric AIDS – related linear gingival erythema: a form of erythematous candidiasis. J Oral Pathol Med 1999, 28:178-82.
- 14-CDC - Center for Disease Control and Prevention – 1994 revised classification system for human immunodeficiency virus infection in children less than 13 years of age. MMWR 1993; 43: 1-10.

- 15- Odds FC, Bernaerts R. CHROMagar Candida, a new differential isolation medium for presumptive identification of clinically important *Candida* species. J Clin Microbiol 1994; 32:1923-1929.
- 16-Lamey PJ, Darwazeh AMG, Fisher BM, Samaranayake LP, MacFarlane TW, Frier BM. Secretor status, candidal carriage and candidal infection in patients with diabetes mellitus. J Oral Pathol 1998; 17: 354-377.
- 17-Portela MB, Souza IP, Costa EM, Hagler AN, Soares RM, Santos AL. Differential recovery of *Candida* species from subgingival sites in Human Immunodeficiency Virus-Positive and healthy children from Rio de Janeiro, Brazil. J Clin Microbiol 2004; 42: 5925-7.
- 18-Grbic JT, Mitchell-Lewis DA, Fine JB, Phelan JA, Bucklan RS, Lamster IB, et al. The relationship of candidiasis to linear gingival erythema in HIV-infected homosexual men and parenteral drug users. J Periodontol 1995; 66: 30-37.
- 19-Katz MH, Mastrucci MT, Legott PJ, Westenhause J, Greenspan JS, Scott GB. Prognostic significance of oral lesions in children with perinatally acquired Human Immunodeficiency virus infection. Amer J Pis Child 1993; 147: 45-8.
- 20-Glick M, Muzyka B, Lurie D, Salkin LM. Oral manifestations associated with HIV- related diseases as markers for immune suppression and AIDS. Oral Surg Oral Med Oral Pathol 1994; 77: 344-8.
- 21-Portela MB, Castro GF, Costa EMMB, Silva Junior A, Dias EP, ET AL. Case report on a rare lesion in a HIV-infected child: hairy leukoplakia. J Clin Pediatr Dent 2002; 26: 405-8.