HYPEREXTENSION OF THE HEAD VERSUS CERVICAL VERTEBRAE MORPHOLOGY IN MOUTH AND NASAL BREATHERS: A PRELIMINARY STUDY

Carolina Messias da **Costa**[1], Julia Garcia **Costa**[1], Adriana de Alcantara Cury **Saramago**[1], Claudia Trindade **Mattos**[1], Beatriz Souza **Vilella**[1], Oswaldo de Vasconcellos **Vilella**[1*]

[1]Department of Orthodontics, School of Dentistry, Universidade Federal Fluminense, Niterói, Rio de Janeiro, Brazil.

Palavras-chave: Vértebras Cervicais. Respiração Bucal. Atlas. Áxis.

RESUMO

Objetivo: O objetivo deste estudo foi comparar, através da tomografia computadorizada de feixe cônico (TCFC), a morfologia das vértebras cervicais atlas (C1) e axis (C2) nos respiradores bucais (RB) e nos respiradores nasais (RN). **Materiais e Métodos**: Imagens de TCFC de 36 indivíduos de 11 a 22 anos foram avaliadas utilizando-se o *software* InVivo Dental 5.1 (Anatomage, San Jose, Califórnia). Foram utilizadas as seguintes medidas para avaliar a morfologia de C1 e C2: altura posterior, altura anterior, comprimento e volume. O ângulo craniocervical (NSL/OPT) foi utilizado para avaliar a postura da cabeça em relação ao pescoço. **Resultados**: A altura posterior, o comprimento e o volume de C1 e C2 foram menores no grupo RB, mas apenas a altura posterior foi significativamente menor em comparação com o grupo RN (C1, *p*=0,01 / C2, *p*=0,05). Os respiradores bucais também apresentaram ângulo craniocervical significativamente maior (*p*=0,04). O teste de Spearman mostrou correlação positiva significativa entre o comprimento de C1 e C2 e o ângulo craniocervical (C1, *p*=0,629, *p*=0,005 / C2, p=0,665, *p*=0,003). **Conclusão**: Os respiradores bucais apresentaram aumento do ângulo craniocervical e diminuição da altura posterior da vértebra C1 em relação aos respiradores nasais. A hiperextensão da cabeça presente está positivamente correlacionada com o comprimento da vértebra.

Keywords: Cervical Vertebrae. Mouth Breathing. Atlas. Axis.

ABSTRACT

Objective: This study aimed to compare through cone-beam computed tomography (CBCT) the morphology of the cervical vertebrae atlas (C1) and axis (C2) in mouth breathers (MB) and nose breathers (NB), correlating them with the head and neck postures of the two groups. **Materials and Methods**: CBCT images of 36 subjects aged 11 to 22 years were evaluated using the InVivo Dental 5.1 (Anatomage, San Jose, California) software. The following measurements were used to assess C1 and C2 morphology: posterior height, anterior height, length, and volume. The craniocervical angle (NSL/OPT) was used to evaluate head posture concerning the neck. **Results**: The posterior height, length, and volume of C1 and C2 were lower in the MB group, but only the posterior size was significantly shorter than the NB group (C1, *p*=0.01 / C2, *p*=0.05). Mouth breathers also showed a considerably higher craniocervical angle (*p*=0.04). Spearman test showed a significant positive correlation between C1 and C2 length and craniocervical angle (C1, ρ=0.629, *p*=0.005 / C2, ρ=0.665, *p*=0.003). **Conclusion**: The mouth breathers showed an increased craniocervical angle and decreased posterior height of the C1 vertebra concerning nasal breathers. The hyperextension of the head present is positively correlated with the length of the vertebra.

Submitted: July 09, 2021
Modification: August 16, 2021
Accepted: September 30, 2021

***Correspondence to**:
Oswaldo de Vasconcellos Vilella
Address: Department of Orthodontics – Faculty of Dentistry - Universidade Federal Fluminense.
Rua Mário Santos Braga, 30, 2º andar, sala 214, Centro, Campus do Valonguinho, Niterói, RJ, Brazil. CEP: 24020-140
Telephone number: +55 (21) 2629-9812
E-mail: ovvilella@gmail.com

INTRODUCTION

Subjects who breathe through the mouth show some specific characteristics: small nose, short upper lip, constantly open mouth, dry mouth, mandibular retrognathism, higher inferior face height, and hyperextension of the head relative to the cervical spine. This is a functional response to facilitate mouth breathing and compensate for the nasal obstruction.[1-7] When the head is tilted up, and back from the second cervical vertebra, the airways expand.[7]

The first two vertebrae, atlas (C1) and axis (C2), form the upper segment of the neck connecting with the occipital bone.[8] The morphology of these vertebrae differs from that of the other vertebrae. In association with suboccipital muscles, they are responsible for allowing the head's extension, flexion, rotation, and lateral inclination.[8,9]

Cause and effect relationships between changes in the head and neck posture that promote morphogenetic changes usually focus on craniofacial structures.[5,10-17] However, it has been observed that the horizontal and vertical dimensions of the first cervical vertebra are associated with the posture of the head and skull base inclination.[10,17-20] To date, there have been no studies related to head posture and possible changes in the morphology of the second vertebra.

This study aimed to compare through CBCT images the morphology of C1 and C2 vertebrae in mouth breathers and nasal breathers, correlating them with the head and neck postures of the two groups. The hypothesis is that mouth breathers show an increased craniocervical angle and decreased posterior height of vertebrae.

MATERIALS AND METHODS

The local ethics committee approved this comparative cross-sectional study by the number 41682015.5.0000.5243. It initially involved 125 consecutive patients evaluated using the CBCT obtained for their diagnosis and orthodontic planning. No imaging was performed specifically for the study.

A sample size calculation was performed using the formula described by Pandis[21], considering a power test of 80% and α of 0.05 to detect a difference in the length of the first cervical vertebra, considered the primary outcome, of 3.0 mm between the groups based on the study of Watanabe *et al.*[22] (SD, 3.2mm). The sample size calculation showed that at least 18 subjects would be needed in each group.

Cone-beam computed tomography (CBCT) was performed using a 3D i-CAT scanner and processed using its software (Xoran Technologies, Ann Arbor, Michigan). The CBCT was obtained in the complete FULL 220-mm mode, in which the scanner performs two rotations (20 + 20 seconds; 0.4 voxel), allowing for scanning the entire skull. Participants were instructed to maintain maximum intercuspation and a natural head posture by looking at a fixed point during the scan.

The inclusion criteria were: C2, C3, and C4 cervical vertebrae in cervical vertebrae maturation (CVM) stage III or above according to the method described by Baccetti *et al*.[23] This meant most morphological and physiological changes related to aging of the first and second vertebrae would have already occurred.

The exclusion criteria were CBCT scans with incomplete images of the vertebrae and bifid vertebrae. Participants who were systematically using nasal medication either topically or systemically were also excluded.

An experienced otolaryngologist (OL) performed clinical exams in 52 participants by rhinoscopy, clinical exam, and endoscopy. Endoscopy was performed using a rigid fiberoptic endoscope with topical decongestant spray (0.05% Xymetazoline) and topical anesthetic spray (2% Xylocaine). Digital images were captured and recorded. Alterations in the nasal turbinates were reevaluated after this exam to validate the behavior of these tissues when under the effect of topical decongestant and topical anesthetic. The presence of smaller turbinates indicated that nasal obstruction was not permanent.

The signs that suggested mouth breathing were the decreased distance between the nasal septum and turbinates, decreased nasopharyngeal space, narrow alar base, dry mouth, labial incompetence, crowding, mandibular retrognathism, increased facial height, and dark circles under the eyes.[24] The OL diagnosed each individual according to the breathing pattern.

Thirty-six participants satisfied the inclusion criteria. Their ages ranged from 11 to 22 years, with a mean of 14 years. They were separated into two groups of 18: mouth breathers (MB) and nasal breathers (NB). All subjects from the MB group had enlarged adenoids, and 15 also had a deviated septum.

The mean age of the NB group was 14 years and three months (15 years and two months for the boys and 13 years and four months for the girls). The mean age of the MB group was 14 years (15 years and nine months for the boys and 13 years and two months for the girls).

C1 and C2 measurements

Measurements were performed randomly by the same operator, who was blinded to the selection of the participants and had no knowledge of the evaluation made by the otorhinolaryngologist. The C1 and C2 vertebrae were evaluated through three-dimensional reconstruction in the

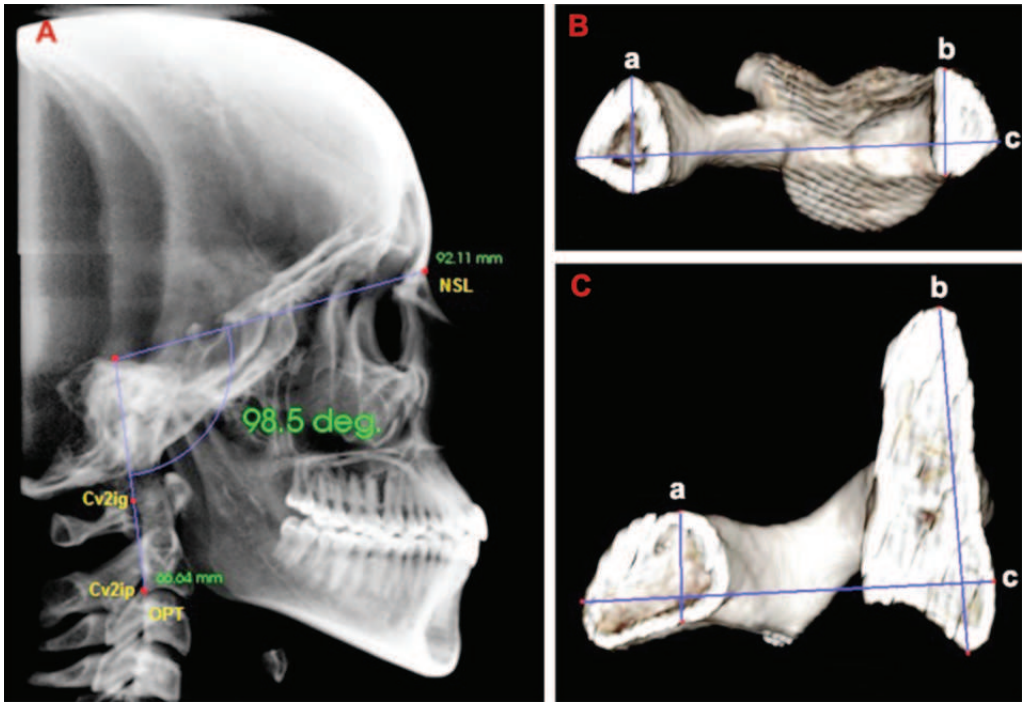

***Figure 1**: A) Craniocervical angle measurement. NSL= Nasion-Sella line; OPT = line through Cv2ig and Cv2ip; Cv2ig = tangent point at the upper posterior extremity of the odontoid process of C2; Cv2ip = lower posterior point on the body of the C2. B) Linear measurements of C1 vertebra evaluated in lateral view: anterior height, posterior height and length. C) Linear measurements of C2 vertebra evaluated in lateral view: anterior height, posterior height and length.*

InVivo Dental 5.1 software (Anatomage, San Jose, California), with the height of the anterior and posterior region and length and volume of each vertebra. Each vertebra was isolated from excluding all other anatomical structures. The vertebrae were positioned in the upper axial view and sectioned in the anteroposterior direction to perform the measurements. In this way, it was possible to carry out measurements in the middle region in lateral view (Figure 1B and 1C). The selected points of each measure were checked in the axial, lateral, anterior, and posterior views.

Length

To measure length, the most prominent point of the anterior region was selected in lateral view, and a line was traced to the most central point of the posterior region.[22]

Anterior and posterior height

To measure height, the uppermost point of each region was selected in lateral view, and a line was drawn from this to the lowest point.[22]

Volume

Adjustments were made to the "threshold," a tool that analyzes the gray tones of different voxels that make up the image to visualize the vertebrae's morphology better. Then, the program automatically calculated the volume.

Head posture assessment

Head posture was evaluated using a head profile image, reproducing the image of a lateral cephalometric radiograph. Points corresponding to the craniocervical angle were selected[25] (OPT/NSL), and the software automatically calculated the angle (Figure 1A).

Statistical analysis

Statistical analysis was performed using SPSS software (version 20.0, IBM, Armonk, NY). The intraclass correlation coefficient (ICC) and the paired t-test were used to evaluate the error of the method, and mean error was described; this was calculated based on measurements of 20 CBCT scans performed in two stages, with an interval of 15 days between the stages.

The Shapiro-Wilk test was used to verify the distribution of the data. Since the data distribution did not follow a regular pattern and due to possible significant confounding from overall body size, the cervical vertebrae measurements were normalized to the mandibular length (Co-Gn), which worked as an independent variable. Additionally, two ratios were calculated. The following formula performed the vertebral height index (VHI): anterior height / posterior height. The vertebral morphological ratio (VMR) was obtained by the following procedure: posterior height/length.

The distribution of patients in the two groups regarding CVM stage, sex, and ethnicity was assessed through the chi-square test. The age difference was tested with the independent t-test.

Intergroup comparison of cervical vertebrae measurements was performed using the Mann-Whitney test for variables without a normal distribution and the independent t-test for normally distributed data, both with the Benjamini-Hochberg correction for multiple hypothesis tests, and adopting $p< 0.05$ as significant. Spearman's correlation test was used to analyze the association of vertebral measurements with the craniocervical angle.

RESULTS

The Table 1 shows the characteristics of nasal breathers (NB) and mouth breathers (MB) groups: age, CVM stage, sex, and ethnicity. No statistically significant differences were observed between the groups.

The ICC values ranged between 0.93 and 0.99, suggesting excellent reliability of the examiner. No statistically significant error was observed, and the mean error varied between 0.01 and 0.22 mm for linear measurements and between 0.00 and 0.12 cm^3 for volume measurements (Table 2).

Posterior height was significantly greater in the NB group for C1 and C2 linear measurements and C1 normalized measurement (p=0.01; p=0.05; p=0.02, respectively). The vertebral height index (VHI) was significantly lower, and the vertebral morphological ratio (VMR) was significantly higher in the NB group. No differences were observed for anterior height, length, and volume (Table 3).

The craniocervical angle differed significantly between groups (p=0.04), with higher values on average in the MB group (105.06° ± 5.00) compared to the NB group (99.93° ± 8.99). The mandibular length (Co-Gn) was similar for both groups with no significant difference and mean value of 109.92° and 109.23° for the MB and NB groups, respectively.

Spearman's test showed a statistically significant positive correlation between the length of C1 and C2and the craniocervical angle in the MB group (p=0.005 and p=0.003, respectively) (Table 4).

***Table 1**: Characterization of the sample groups.*

Characteristic		**NB** (n=18)	**MB** (n=18)	***p*** value
Mean Age (SD)		14.3 (3.46)	14.05 (2.62)	0.788
CVM (%)	S3	38.9	44.5	0.915
	S4	33.3	33.3	
	S5	27.8	22.2	
Sex (%)	M	33.3	50	0.310
	F	66.7	50	
Ethnicity (%)	White	66.7	66.7	1.000
	Black	33.3	33.3	

Note: p values according to independent t test and chi-square test. NB = nasal breathers; MB= mouth breathers; CVM = cervical vertebrae maturation

***Table 2**: Intraclass correlation coefficient (ICC), mean differences and paired t test.*

	ICC (CI 95%)	**Mean Difference**	***p* value**
C1			
Posterior height (mm)	0.993 (0.983 - 0.997)	0.01	0.947
Anterior height (mm)	0.984 (0.960 - 0.994)	0.08	0.648
Length (mm)	0.994 (0.985 - 0.998)	0.07	0.901
Volume (mm^3)	0.983 (0.957 - 0.993)	0.00	0.939
C2			
Posterior height (mm)	0.989 (0.973 - 0.996)	0.05	0.600
Anterior height (mm)	0.984 (0.959 - 0.994)	0.22	0.272
Length (mm)	0.996 (0.989 - 0.998)	0.08	0.740
Volume (mm^3)	0.931 (0.835 - 0.972)	0.12	0.673

***Table 3**: C1 and C2 measurements, vertebral height index (VHI), vertebral morphological ratio (VMR) and differences between nasal breathers (NB) and mouth breathers (MB).*

	NB		MB		
	Median (IQR)	**Range**	**Median (IQR)**	**Range**	***p* value**
C1					
Posterior height (mm)	9.06 (2.02)	5.43 - 12.18	7.59 (2.83)	3.65 - 12.24	0.01*
Anterior height (mm)	10.13 (1.39)	8.68 - 11.55	10.35 (1.91)	7.74 - 13.06	0.76
Length (mm)	43.57 (6.98)	33.01 - 47.16	42.64 (5.62)	37.42 - 49.98	0.73
Volume (mm^3)	10.10 (2.55)	7.26 - 12.81	9.45 (2.51)	6.44 - 11.19	0.15
VHI	1.08 (0.23)	0.83 - 1.79	1.26 (0.61)	0.89 - 3.58	0.03*
VMR	0.22 (0.04)	0.14 - 0.26	0.17 (0.06)	0.09 - 0.26	0.04*
C2					
Posterior height (mm)	11.29 (1.70)	8.75 - 13.36	10.63 (1.96)	5.22 - 13.72	0.05*
Anterior height (mm)	36.79 (4.65)	30.55 - 40.23	36.32 (3.27)	32.41 - 41.47	0.68
Length (mm)	42.04 (6.38)	32.60 - 47.46	41.23 (6.57)	32.16 - 48.43	0.66
Volume (mm^3)	12.65 (2.20)	8.95 - 14.52	11.52 (3.05)	8.13 - 14.94	0.21
VHI	3.18 (0.45)	2.87 - 4.40	3.47 (0.65)	2.51 - 6.84	0.06
VMR	0.27 (0.04)	0.19 - 0.33	0.25 (0.06)	0.16 - 0.31	0.143
	Mean (SD)	**Range**	**Mean (SD)**	**Range**	***p* value**
C1					
Posterior height normalized	0.08 (0.01)	0.05 - 0.11	0.07 (0.01)	0.03 - 0.09	0.02*
Anterior height normalized	0.09 (0.00)	0.08 - 0.11	0.09 (0.01)	0.06 - 0.11	0.87
Length normalized	0.38 (0.03)	0.31 - 0.43	0.40 (0.04)	0.31 - 0.50	0.46
Volume normalized	0.09 (0.01)	0.07- 0.11	0.08 (0.01)	0.05 - 0.11	0.09
C2					
Post. height normalized	0.10 (0.01)	0.08 - 0.12	0.09 (0.02)	0.04 - 0.16	0.09
Ant. height normalized	0.33 (0.02)	0.28 - 0.37	0.33 (0.02)	0.29 - 0.41	0.92
Length normalized	0.38 (0.04)	0.29 - 0.45	0.38 (0.05)	0.27 - 0.52	0.85
Volume normalized	0.11 (0.01)	0.8 - 0.13	0.10 (0.01)	0.08 - 0.13	0.06

Note: p values according to Mann-Whitney and independent t test. NB = nasal breathers; MB = mouth breathers.

***Table 4**: Correlation of the craniocervical angle and cervical vertebrae measurements.*

	NB		MB	
C1	ρ	*p* value	ρ	*p* value
Posterior height	0.276	0.268	0.346	0.16
Anterior height	0.048	0.851	0.226	0.367
Length	0.245	0.328	0.629	0.005*
Volume	0.17	0.499	-0.056	0.826
C2				
Posterior height	-0.009	0.695	0.171	0.496
Anterior height	0.088	0.729	-0.15	0.553
Length	-0.018	0.945	0.665	0.003*
Volume	0.321	0.194	-0.066	0.794

Note: ρ = Spearman coefficient. NB = nasal breathers; *MB = mouth breathers.

DISCUSSION

In this study, the respiratory pattern was determined by an otolaryngologist after clinical examination with validated tools.[26-27] Based on previous studies[28,29] showing no difference between oral and nasal breathers when divided according to sex, we did not distinguish between sexes in the current study. Additionally, the sex distribution in the groups of this study was not significantly different. However, future studies should consider and further address this aspect since sex determination has been reported as possible through discriminant functions from dimensions of the first[30] and second cervical vertebrae[31-33] for forensic purposes. Our ethnicity distribution in both groups was precisely the same, and a recent study[34] has shown no racial differences between whites and African Americans in the timing of cervical vertebrae maturation stages. Based on these results, we did not distinguish between ethnicity in the present study. However, the influence of this aspect has not been proved for cervical vertebrae dimensions and should be addressed in future studies.

To date, the effects of hyperextension of the head on the morphology of the second cervical vertebra have not been investigated. Studies evaluating the first vertebra[17,18,20,33] were based on measurements from cephalometric radiographs. With the advent of cone-beam computed tomography (CBCT), a new approach to diagnosing and analyzing the 3D structures that make up the skull and cervical spine bones became feasible. Our study took advantage of this new approach to identify morphological and volumetric changes in the C1 and C2 vertebrae of oral and nasal breathers and to associate these with each group's head and neck posture.

Once all measurements had been made in lateral view, we decided to cut through the midsagittal section of each vertebra. This methodology avoided overlapping lateral eminences (transversal processes) of the vertebra on a sagittal view. All points were selected from the upper, lower, anterior, and posterior views to position them as accurately as possible.

The data on the craniocervical angle showed that the members of the MB group had an altered head posture concerning the neck compared to members of the NB group. Hyperextension of the head occurs as a functional response to facilitate mouth breathing, offsetting nasal obstruction.[1-3,5,6] When the inclination of the head upwards and backwards occurs from the second cervical vertebra on, the oropharyngeal space increases.[7,25] When it occurs from the C3 vertebra, the head tilt promotes a slight change in the craniocervical angle and increased cervical lordoses, thus reducing the pharyngeal space.[7] Therefore, the effect on the oropharyngeal airspace depends on how the individual extends their head. The steepening of the head tilt seen in the MB group probably occurred from the C2 vertebra.

The anterior height of the two vertebrae was not associated with the posture of the head. This is due to the anatomy and biomechanics of the vertebrae.[9,34,35] The upper and lower articular face of all vertebrae is located more anteriorly. Thus, the amplitude of intervertebral movements is more significant in the posterior region of the cervical spine than in the anterior region.

We found that the posterior height of the C1 vertebra was lower in mouth breathers (MB) than in nasal breathers (NB), which is consistent with the study of Kylämarkula and Huggare[20] based on cephalometric radiography. The posterior height of the C2 vertebra was also smaller in the MB group than in the NB group, although that was not confirmed in the normalized measurements. The hyperextension present in mouth breathers approaches the base of the skull at the C1 vertebra, which directly receives the load from the weight of the head.[9,36] Due to the reduction in the intervertebral space, some of this load is passed on to C2.[7] During this movement, the head can be extended until the posterior arch of the C1 vertebra touches the C2 neural arch.[37] The only limitation to activity is determined by compression of the occipital bone over suboccipital muscles.

There was a significant positive association between the sharp craniocervical angle and C1 and C2 length, showing that the higher the size of the vertebrae, the more the hyperextension of the head. During the extension of the head, the posterior arch of the C1 vertebra is compressed by suboccipital muscles against the neural arch of the C2 vertebra.[36] This compression may affect the length of the vertebrae. Despite this association, the length of the two vertebrae did not differ significantly between the MB and NB.

There was no significant difference in the volume of the vertebrae between the mouth and nasal breathers, although, in the normalized measurements, the p-value was low. Since this was a preliminary study and this variable was not the primary outcome, further research with more excellent samples should analyze and compare this measure, which may be considered a limitation of this study.

The index adopted in this study (VHI) was significantly higher in mouth breathers for C1 and C2, which is compatible with this group's similar anterior height and lower posterior height. This index helps confirm those differences since linear measurements alone may be misleading due to individual overall body size and growth. The morphological ratio (VMR) assessed was significantly lower in mouth breathers for C1, coherent with a lower posterior height and similar length.

This ratio indicates morphological differences in the first cervical vertebrae, which should be confirmed in future studies.

The clinical relevance of this research was the finding that mouth breathers present a significantly higher extension of the head and lower posterior height and indicatives of morphological changes in the first cervical vertebrae. Orthodontists should be aware of the whole context and characteristics of mouth breathers, which can, in turn, influence malocclusion.

In conclusion, the mouth breathers showed an increased craniocervical angle and decreased posterior height of C1 vertebrae concerning nasal breathers.

REFERENCES

1. Krakauer LH, Guilherme A. Relationship between mouth breathing and postural alterations of children: a descriptive analysis. Int J Orofacial Myology 2000;26:13-23.
2. Ricketts RM. Respiratory obstruction syndrome. Am J Orthod 1968;54:495-507. doi: 10.1016/0002-9416(68)90218-2.
3. Huggare JA, Laine-Alava MT. Nasorespiratory function and head posture. Am J Orthod Dentofacial Orthop 1997;112:507-511. doi: 10.1016/s0889-5406(97)70078-7.
4. Cuccia AM, Lotti M, Caradonna D. Oral breathing and head posture. Angle Orthod 2008;78:77-82. doi: 10.2319/011507-18.1.
5. Solow B, Siersbaek-Nielsen S, Greve E. Airway adequacy, head posture, and craniofacial morphology. Am J Orthod 1984;86:214-223. doi: 10.1016/0002-9416(84)90373-7.
6. Lima LC, Barauna MA, Sologurem MJ, Canto RS, Gastaldi AC. Postural alterations in children with mouth breathing assessed by computerized biophotogrammetry. J Appl Oral Sci 2004;12:232-237. doi: 10.1590/s1678-77572004000300014.
7. Hellsing E. Changes in the pharyngeal airway in relation to extension of the head. Eur J Orthod 1989;11:359-365. doi: 10.1093/oxfordjournals.ejo.a036007.
8. Hansen JT. Netter´s Clinical Anatomy. 3rd ed. Elsevier; 2014.
9. Huelke DF, Nusholtz GS. Cervical spine biomechanics: a review of the literature. J Orthop Res 1986;4:232-245. doi: 10.1002/jor.1100040212.
10. Sonnesen L. Associations between the cervical vertebral column and craniofacial morphology. Int J Dent 2010;2010:295728. doi: 10.1155/2010/295728.
11. Leitão P, Nanda RS. Relationship of natural head position to craniofacial morphology. Am J Orthod Dentofacial Orthop 2000;117:406-417. doi: 10.1016/s0889-5406(00)70160-0.
12. McNamara JA. Influence of respiratory pattern on craniofacial growth. Angle Orthod 1981;51:269-300. doi: 10.1043/0003-3219(1981)051<0269:IORPOC>2.0.CO;2.
13. Solow B, Tallgren A. Head posture and craniofacial morphology. Am J Phys Anthropol 1976;44:417-435. doi: 10.1002/ajpa.1330440306.
14. Solow B, Siersbaek-Nielsen S. Cervical and craniocervical posture as predictors of craniofacial growth. Am J Orthod Dentofacial Orthop 1992;101:449-458. doi: 10.1016/0889-5406(92)70119-u.
15. Solow B, Sandham A. Cranio-cervical posture: a factor in the development and function of the dentofacial structures. Eur J Orthod 2002;24:447-456. doi: 10.1093/ejo/24.5.447.
16. Solow B, Sonnesen L. Head posture and malocclusions. Eur J Orthod 1998;20:685-693. doi: 10.1093/ejo/20.6.685.
17. Huggare J. Association between morphology of the first cervical vertebra, head posture, and craniofacial structures. Eur J Orthod 1991;13:435-440. doi: 10.1093/ejo/13.6.435.
18. Sandikçioğlu M, Skov S, Solow B. Atlas morphology in relation to craniofacial morphology and head posture. Eur J Orthod 1994;16:96-103. doi 10.1093/ejo/16.2.96.
19. Huggare J, Kylämarkula S. Morphology of the first cervical vertebra in children with enlarged adenoids. Eur J Orthod 1985;7:93-96. doi: 10.1093/ejo/7.2.93.
20. Kylämarkula S, Huggare J. Head posture and the morphology of the first cervical vertebra. Eur J Orthod 1985;7:151-156. doi: 10.1093/ejo/7.3.151.
21. Pandis N. Sample calculations for comparison of 2 means. Am J Orthod Dentofacial Orthop 2012;141:519-521. doi: 10.1016/j.ajodo.2011.12.010.
22. Watanabe M, Yamaguchi T, Maki K. Cervical vertebra morphology in different skeletal classes. A three-dimensional computed tomography evaluation. Angle Orthod 2010;80:531-536. doi: 10.2319/100609-557.1.
23. Baccetti T, Franchi L, McNamara JA. An improved version of the cervical vertebral maturation (CVM) method for the assessment of mandibular growth. Angle Orthod 2002;72:316-323. doi: 10.1043/0003-3219(2002)072<0316:AIVOTC>2.0.CO;2.
24. Vig KW. Nasal obstruction and facial growth: the strength of evidence for clinical assumptions. Am J Orthod Dentofacial Orthop 1998;113:603-611. doi: 10.1016/s0889-5406(98)70219-7.
25. Muto T, Takeda S, Kanazawa M, Yamazaki A, Fujiwara Y, Mizoguchi I. The effect of head posture on the pharyngeal airway space (PAS). Int J Oral Maxillofac Surg 2002;31:579-583. doi: 10.1054/ijom.2002.0279.
26. Ysunza A, Pamplona MC, Ortega JM, Prado H. Video fluoroscopy for evaluating adenoid hypertrophy in children. Int J Pediatr Otorhinolaryngol 2008;72:1159-1165. doi: 10.1016/j.ijporl.2008.03.022.
27. Parikh SR, Coronel M, Lee JJ, Brown SM. Validation of a new grading system for endoscopic examination of adenoid hypertrophy. Otolaryngol Head Neck Surg 2006;135:684-687. doi: 10.1016/j.otohns.2006.05.003.
28. Juliano ML, Machado MA, de Carvalho LB, Zancanella E, Santos GM, do Prado LB et al. Polysomnographic findings are associated with cephalometric measurements in mouth-breathing children. J Clin Sleep Med 2009;5:554-561.
29. Alves M, Baratieri C, Nojima LI, Nojima MC, Ruellas AC. Three-dimensional assessment of pharyngeal airway in nasal- and mouth-breathing children. Int J Pediatr Otorhinolaryngol 2011;75:1195-1199. doi: 10.1016/j.ijporl.2011.06.019.
30. Marino EA. Sex estimation using the first cervical vertebra. Am J Phys Anthropol 1995; 97: 127-133. doi: 10.1002/ajpa.1330970205.
31. Wescott DJ. Sex variation in the second cervical vertebra. J Forensic Sci 2000; 45: 462-466. doi: 10.1520/JFS14707J.
32. Marlow EJ, Pastor RF. Sex determination using the second cervical vertebra – A test of the method. J Forensic Sci 2011; 56:165-169. doi: 10.1111/j.1556-4029.2010.01543.x.
33. Bethard JD, Seet BL. Sex determination from the second cervical vertebra: a test of Wescott´s method on a modern American sample. J Forensic Sci 2013; 58: 101-103. doi: 10.1111/j.1556-4029.2012.02183.x.
34. Montasser MA, Viana G, Evans CA. Racial and sex differences in

timing of the cervical vertebrae maturation stages. Am J Orhod Dentofacial Orthop 2017; 151: 744-749. doi: 10.1016/j.ajodo.2016.09.019.
35. Huggare J, Houghton P. Associations between atlantoaxial and craniomandibular anatomy. Growth Dev Aging 1996; 60:21-30.
36. Bonney RA, Corlett EN. Head posture and loading of the cervical spine. Appl Ergon 2002;33:415-417. doi: 10.1016/s0003-6870(02)00036-4.
37. Bogduk N, Mercer S. Biomechanics of the cervical spine. I: Normal kinematics. Clin Biomech (Bristol, Avon) 2000;15:633-648. doi: 10.1016/s0268-0033(00)00034-6.