CLINICAL PERFORMANCE OF A MICRO INVASIVE TREATMENT BASED ON DEMINERALIZATION-REMINERALIZATION FOR DENTAL FLUOROSIS: CASE REPORT

María Luján Méndez **Bauer**[1,2], Jorge Pailover **Bermúdez**[1], Mayra Alejandra Nuñez **Aldaz**[1,3], Ana Cláudia Rodrigues **Chibinski**[4], Alessandro Dourado **Loguercio**[1], Denise Stadler **Wambier**[4*]

[1]Department of Restorative Dentistry, School of Dentistry, Universidade Estadual de Ponta Grossa, Ponta Grossa, Paraná, Brazil.
[2]Research Department, Faculty of Dentistry, University Francisco Marroquin, Guatemala City, Guatemala.
[3]Department of Restorative Dentistry and Biomaterials, San Francisco de Quito University, Quito, Ecuador.
[4]Department of Pediatric Dentistry, School of Dentistry, Universidade Estadual de Ponta Grossa, Ponta Grossa, Paraná, Brazil.

Palavras-chave: Fluorose Dentária. Ácido Clorídrico. Hidróxido de Cálcio. Esmalte Dentário.

RESUMO

Introdução: A fluorose dentária manifesta-se clinicamente como manchas brancas a marrons no esmalte de dentes expostos ao excesso de flúor durante o processo de formação. Tratamentos estéticos foram descritos na literatura para reduzir ou eliminar as manchas fluoróticas na superfície do esmalte. **Objetivo**: Apresentar uma alternativa de tratamento para dentes manchados por fluorose dentária. **Relato do caso**: Este relato de caso descreve o desempenho clínico do tratamento para dentes com fluorose moderada em um paciente de 12 anos. Esse tratamento foi baseado numa técnica de desmineralização e remineralização do dente. O material possui uma fase ácida composta por ácido clorídrico com ácido tricarboxílico, e uma fase alcalina composta por Hidróxido de Cálcio. **Resultados**: Observou-se que esse tratamento, sem dor e rápido, apresentou resultados satisfatórios, pois eliminou as manchas durante o acompanhamento. Além disso, preservou ao máximo a estrutura dentária, beneficiando o paciente com uma melhor aparência dos seus dentes. **Conclusão**: O aspecto do esmalte tratado mostrou uma superfície quase sem manchas fluoróticas, demonstrando resultados satisfatórios deste tratamento.

Keywords: Fluorosis. Hydrochloric Acid. Calcium Hydroxide. Dental Enamel.

ABSTRACT

Introduction: Dental fluorosis manifests clinically as white to brown spots on the enamel teeth that were exposed to excessive fluoride during the formation process. Esthetic treatments were described in the literature to reduce or eliminate the fluorotic stains on the enamel surface. **Objective**: The aim of this study is to present an alternative treatment for fluorosis-stained teeth. **Case report**: This case report describes the clinical performance of a treatment of a 12-year-old male patient whose teeth presented moderate fluorosis. This treatment is based on tooth demineralization and remineralization. The material has an acid phase made by hydrochloric acid with tricarboxylic acid, and an alkaline phase made by Calcium Hydroxide. **Results**: This painless and fast treatment presented good results. The treatment eliminated the spots during the follow-up and preserved most of the dental structure, improving the appearance of the patient's teeth. **Conclusion**: The appearance of the treated enamel showed a surface almost completely free of fluorotic stains, demonstrating the satisfactory results of this treatment.

Submitted: June 18, 2021
Modification: September 24, 2021
Accepted: September 30, 2021

***Correspondence to:**
Denise Stadler Wambier
Address: Universidade Estadual de Ponta Grossa, Departamento de Odontologia. Avenida Carlos Cavalcanti, 4748, Uvaranas, Ponta Grossa, PR, Brazil. CEP: 84030-900.
Telephone number: +55 (42) 3220-3740
E-mail: dswambier@yahoo.com.br

INTRODUCTION

The use of fluoride significantly improved the population's oral health and quality of life decreasing the index of dental caries; however, studies identified dental fluorosis as the first clinical sign of the toxic effect of this substance.[1] Dental fluorosis is an enamel development defect caused by excessive fluoride ingestion, resulting in hypomineralized enamel with greater porosity. Clinically, it is identified as spots that range from delicate white lines to opaque spots that cover part or all of the enamel surface and may suffer pigmentation or fractures after eruption.[2]

Dental fluorosis does not cause pain or symptoms,[3] but the effects are related to the esthetic appearance. Teeth with color harmony represent youth, good health, and natural beauty for humans. Throughout history and evidenced in several cultures, the dental modifications have an esthetic tendency.[4] Currently, patients tend to seek whiter and brighter teeth.[4,5] That is why individuals affected with dental fluorosis often report on oral health-related quality of life (OHRQoL) questionnaires to notice or to be concerned about their appearance,[3] and also reported improvement of the OHRQoL when the dental fluorosis is treated.[6]

To diagnose the dental fluorosis, Dean, Thylstrup and Fejerskov indices, which categorize the degree of dental structure damage, are commonly used.[7,8] Considering epidemiologic studies in Brazil, a prevalence of low and very low fluorosis is observed in the population without fluoridated water supply. Moreover, the moderate and severe cases of fluorosis were reported in cities or rural districts where water is supplied by artesian wells.[9]

Several treatments were described to reduce or eliminate fluorotic stains on the enamel surface. The therapeutic management depends on the severity of the dental fluorosis.[10] For mild and moderate fluorosis, bleaching, microabrasion or resin infiltration can be employed. For severe fluorosis, the treatment might include dental veneers or crowns.[10,11] Treatments are usually accomplished in combination to achieve better results.[11]

The treatment described in this article is indicated for the removal of white to brown stains caused by dental fluorosis or extrinsic causes. It is not well known in the field, but it consists of a demineralization-remineralization procedure. This procedure uses an acid phase solution with a gently rubbing on the enamel surface and an alkaline phase solution to neutralize the acid.

Thus, the aim of this case report is to present an alternative treatment for fluorosis-stained teeth. A 12-year-old male patient with moderate fluorosis had its incisors treated using a technique of demineralization-remineralization.

CASE REPORT

The patient presented at the dental clinic of the Department of Pediatric Dentistry. The 12-year-old male student and his parents described that the main problem of his teeth was to present white and yellow spots, suggestive of fluorosis (Figure 1). The patient's parents reported that he had used fluoridated dentifrice throughout his childhood, and received fluoride systematically at school.

After the clinical evaluation, no caries were detected on the teeth and the diagnosis of moderate fluorosis was confirmed. The enamel surfaces of all the teeth were affected, the left central incisor and the lateral incisor showed incisal fractures and some yellow to brown stains were observed. Therefore, the fluorosis classification was code 4 in Dean Index.[8] The patient reported being unsatisfied and uncomfortable with the color of his teeth, which represented a problem when he smiled. The parents asked for any treatment that could help to solve this situation.

Considering the age of the patient, a more invasive restorative treatment was rejected and a conservative esthetic solution for this case was sought. The treatment chosen was a procedure that involve a demineralization-remineralization technique with the Antivet Kit (Antivet, MDC Dental, Mexico). This treatment has an acid phase made by 21% hydrochloric acid stabilized with a tricarboxylic organic acid (pH<3), and an alkaline phase made by Calcium Hydroxide (pH<12). For esthetic reasons, only the upper anterior teeth were treated.

Before to start of the procedure, dental prophylaxis was performed to remove biofilm with a combination of pumice and water. After that, the teeth were isolated with a rubber dam and also, the patient was positioned in 45º. The aim was to protect the gingival tissues and to prevent that any material be swallowed.

The manufacturer's instructions were followed during all treatment. Five drops of the acid phase were dispensed on a dappen dish. Cotton balls secured with clamps were used to apply the acid phase on the teeth, rubbing the acid all over the buccal surface of the teeth. This procedure was applied for 30 seconds, on each teeth surface and repeated about three times (Figure 2). When the cotton ball was stained, it was substituted with another one. Next, a dry cotton ball was used to remove the acid phase excess. On another dappen dish, the alkaline phase was dispensed and then applied on the teeth surface with a brush, where it remained for two minutes (Figure 3). Finally, the alkaline phase was rinsed and the rubber dam was removed. The patient did not report any symptoms or sensitivity. After the procedures, several fluorosis stains had disappeared. After seven days of the treatment, the patient returned for a follow-up evaluation. More changes were observed in the enamel surface. After six months, the fluorosis had almost all disappeared of the surface of the upper incisors (Figure 4). The patient still had the upper primary canines; therefore, the treatment could be continued after the eruption of the permanent teeth.



***Figure 1**: Initial aspect of the fluorosis-stained enamel.*

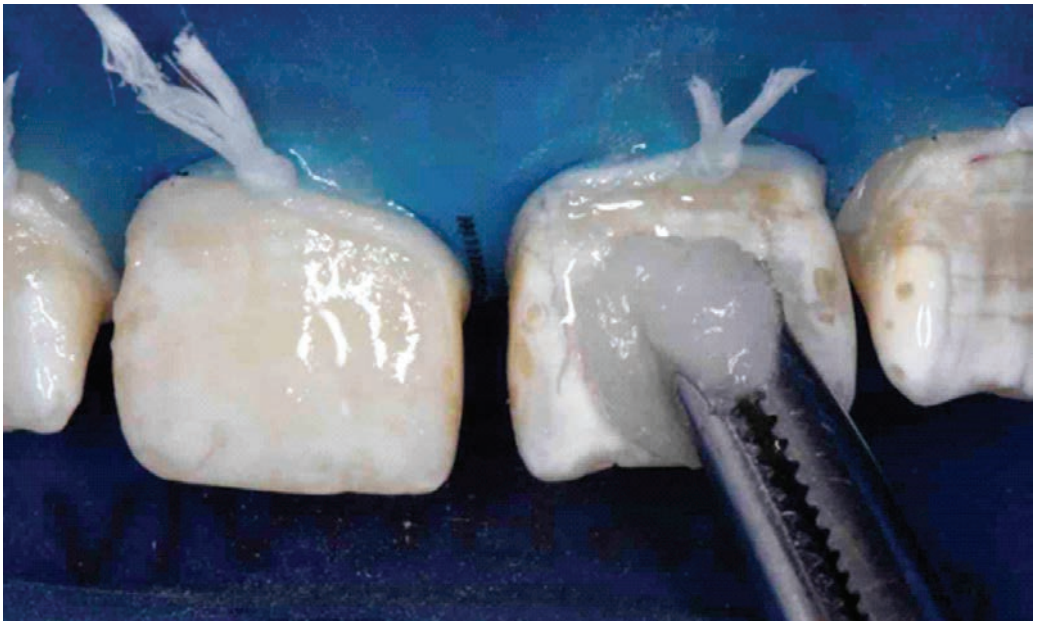

***Figure 2**: Application of the acid phase.*

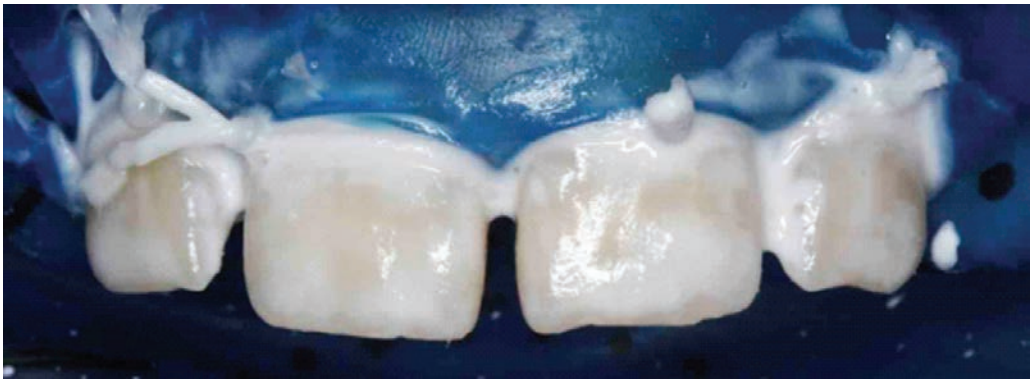

***Figure 3**: Application of the alkaline phase.*



***Figure 4**: Evaluation six months after the treatment.*

DISCUSSION

The prevalence of dental fluorosis constitutes a public health problem in many countries. In Brazil, 16.7% of 12-year-old children have dental fluorosis, most of them presenting mild fluorosis.[12] It is well known that water and toothpastes are the main vehicles of fluoride delivery to prevent caries.[13] The patient reported using adult toothpaste and receiving fluoride at school. For the government, it is important that the concentration of fluoride in drinking water be with the standard values set by the world health organization.[14] Thus, recommendations for using fluoride in public health, clinical practice, self-care and industries need to be prescribed.[15]

The OHRQoL is an endpoint to evaluate treatments in clinical trials of dental fluorosis. The patient reported being unsatisfied and uncomfortable with his teeth; however, after the treatment this perception was improved. A study made in Minas Gerais, Brazil, observed an improvement in psychosocial impact after restorative treatments in patients with fluorosis.[16] Another study that treated dental fluorosis with microabrasion and bleaching concluded that the OHRQoL were improved.[6] To analyze the esthetic perception, a visual analogue scale was used, measuring the improvement of dental fluorosis treatments by the professional.[17,18] According to those studies, patients were satisfied after dental fluorosis treatments, so it is important for the dentistry area that effective, minimally invasive, painless and low-cost treatments for dental fluorosis be investigated.

In the literature, the use of hydrochloric acid appeared between 1960-1970 when it was included in a bleaching solution with satisfactory results to remove fluorosis-stained enamel.[19,20] Years later, this bleaching solution was combined with the sandpaper disk polishing technique,[21] and then the hydrochloric acid at 18% was combined with pumice.[22] Because of the high concentration of hydrochloric acid and the time used in the techniques related, other methods were performed, mostly.[17,18,23] However, recent studies have been developed still using the hydrochloric acid with percentages between 16-18% with good results and without complications.[24,25] The treatment used in this case report is kwon in several countries, so this publication intends to describe this alternative treatment for dental fluorosis and also to promote more studies to evaluate the effect of this treatment on the dental enamel. Moreover, clinic cases may be performed using a combination with other dental fluorosis treatments for better results.

A systematic review compared the effectiveness of treatments for fluorosis-stained enamel.[26] It concluded that resin infiltration was the most effective treatment for lesions of mild to moderate severity, followed by bleaching, and microabrasion. In contrast, resin infiltration and bleaching were considered expensive treatments. Enamel microabrasion is a conservative and easy technique with clinical efficacy,[27] and can be considered a low-cost treatment depending on the material chosen for the procedure. Professionals must be aware of the patient's situation in order to choose the best treatment and, at the same time, adapt it to the patient's needs.

CONCLUSION

Enamel microabrasion with a demineralization-remineralization technique result in a conservative, effective, and low-cost treatment for fluorosis stained enamel. The appearance of the enamel treated showed the loss of fluorotic stains, improving over time.

REFERENCES

1. Burt BA. Fluoride—how much of a good thing? Introduction to the symposium. J Public Health Dent. 1995 Winter;55(1):37-8. doi: 10.1111/j.1752-7325.1995.tb02329.x.
2. Carvalho RWFd, Valois RBV, Santos CNA, Marcellini PS, Bonjardim LR, Oliveira CCdC, et al. Study of the prevalence of dental fluorosis in Aracaju. Cien Saude Colet. 2010;15 Suppl 1:1875-80. doi: 10.1590/s1413-81232010000700101.
3. Chankanka O, Levy Sm Fau - Warren JJ, Warren Jj Fau - Chalmers JM, Chalmers JM. A literature review of aesthetic perceptions of dental fluorosis and relationships with psychosocial aspects/oral health-related quality of life. Community Dentistry and Oral Epidemiology. 2010;38(2):97-109. doi: 10.1111/j.1600-0528.2009.00507.x.
4. Khalid A, Quiñonez C. Straight, white teeth as a social prerogative. Sociology of Health & Illness. 2015;37(1467-9566 (Electronic)):782-96. doi: 10.1111/1467-9566.12238
5. Carey CM. Tooth whitening: what we now know. The journal of evidence-based dental practice. 2014 Jun;14 Suppl:70-6. doi: 10.1016/j.jebdp.2014.02.006.
6. Meireles SS, Goettems ML, Castro KS, Sampaio FC, Demarco FF. Dental Fluorosis Treatment Can Improve the Individuals' OHRQoL? Results from a Randomized Clinical Trial. Brazilian dental journal. 2018 Mar-Apr;29(2):109-16. doi: 10.1590/0103-6440201801733.
7. Thylstrup A, Fejerskov O. Clinical appearance of dental fluorosis in permanent teeth in relation to histologic changes. Community Dent Oral Epidemiol. 1978 Nov;6(6):315-28. doi: 10.1111/j.1600-0528.1978.tb01173.x.
8. Dean HT. Fluorine in the control of dental caries. Journal of the American Dental Association (1939). 1956 Jan;52(1):1-8. doi: 10.14219/jada.archive.1956.0011.
9. Lima IFP, Nóbrega DF, Cericato GO, Ziegelmann PK, Paranhos LR. Prevalence of dental fluorosis in regions supplied with non-fluoridated water in the Brazilian territory: a systematic review and meta-analysis. Cien Saude Colet. 2019 Aug 5;24(8):2909-22. doi: 10.1590/1413-81232018248.19172017.
10 Akpata ES. Occurrence and management of dental fluorosis. International dental journal. 2001 Oct;51(5):325-33. doi: 10.1002/j.1875-595x.2001.tb00845.x.
11. Di Giovanni T, Eliades T, Papageorgiou SN. Interventions for dental fluorosis: A systematic review. J Esthet Restor Dent. 2018 Nov;30(6):502-8. doi: 10.1111/jerd.12408.
12. Brasil. SB Brasil 2010: pesquisa nacional de saúde bucal: resultados principais. Ministério da Saúde Brasília; 2012.
13. Azevedo MS, Goettems ML, Torriani DD, Demarco FF. Factors associated with dental fluorosis in school children in southern Brazil: a cross-sectional study. Brazilian oral research. 2014;28. doi: 10.1590/1807-3107bor-2014.vol28.0014.
14. Ramires I, Olympio KP, Maria AG, Pessan JP, Cardoso VE, Lodi CS, et al. Fluoridation of the public water supply and prevalence of dental fluorosis in a peripheral district of the municipality of Bauru, SP. Journal of applied oral science : revista FOB. 2006 Apr;14(2):136-41. doi: 10.1590/s1678-77572006000200013.
15. Levy SM. An update on fluorides and fluorosis. Journal (Canadian Dental Association). 2003 May;69(5):286-91.
16. Santa-Rosa TT, Ferreira RC, Drummond AM, De Magalhães CS, Vargas AM, Ferreira EFE. Impact of aesthetic restorative treatment on anterior teeth with fluorosis among residents of an endemic area in Brazil: intervention study. BMC oral health. 2014 May 13;14:52. doi: 10.1186/1472-6831-14-52.
17. Loguercio AD, Correia LD, Zago C, Tagliari D, Neumann E, Gomes OMM, et al. Clinical effectiveness of two microabrasion materials for the removal of enamel fluorosis stains. Oper Dent. 2007 Nov-Dec;32(6):531-8. doi: 10.2341/06-172.
18. Castro KS, Ferreira AC, Duarte RM, Sampaio FC, Meireles SS. Acceptability, efficacy and safety of two treatment protocols for dental fluorosis: a randomized clinical trial. J Dent. 2014 Aug;42(8):938-44. doi: 10.1016/j.jdent.2014.01.011.
19. McInnes J. Removing brown stain from teeth. The Arizona dental journal. 1966 May 15;12(4):13-5.
20. Bailey RW, Christen AG. Effects of a bleaching technic on the labial enamel of human teeth stained with endemic dental fluorosis. Journal of dental research. 1970 Jan-Feb;49(1):168-70. Doi: 10.1177/00220345700490011201.
21. Chandra S, Chawla TN. Clinical evaluation of the sandpaper disk method for removing fluorosis stains from teeth. Journal of the American Dental Association (1939). 1975 Jun;90(6):1273-6. doi: 10.14219/jada.archive.1975.0259.
22. Croll TP, Cavanaugh RR. Hydrochloric acid-pumice enamel surface abrasion for color modification: results after six months. Quintessence international (Berlin, Germany : 1985). 1986 Jun;17(6):335-41.
23. Pini NI, Sundfeld-Neto D, Aguiar FH, Sundfeld RH, Martins LR, Lovadino JR, et al. Enamel microabrasion: An overview of clinical and scientific considerations. World journal of clinical cases. 2015 Jan 16;3(1):34-41. doi: 10.12998/wjcc.v3.i1.34.
24. Nevárez-Rascón M, Molina-Frechero N, Adame E, Almeida E, Soto-Barreras U, Gaona E, et al. Effectiveness of a microabrasion technique using 16% HCL with manual application on fluorotic teeth: A series of studies. World journal of clinical cases. 2020 Feb 26;8(4):743-56. doi: 10.12998/wjcc.v8.i4.743.
25. Balan B, Madanda Uthaiah C, Narayanan S, Mookalamada Monnappa P. Microabrasion: an effective method for improvement of esthetics in dentistry. Case reports in dentistry. 2013;2013:951589. doi: 10.1155/2013/951589.
26. Di Giovanni T, Eliades T, Papageorgiou SN. Interventions for dental fluorosis: A systematic review. J Esthet Restor Dent. 2018;30(6):502-8. doi: 10.1111/jerd.12408.
27. Sundfeld RH, Croll TP, Briso AL, de Alexandre RS, Sundfeld Neto D. Considerations about enamel microabrasion after 18 years. American journal of dentistry. 2007 Apr;20(2):67-72.