RESIN INFILTRATION FOR APPROXIMAL CARIES LESIONS IN PRIMARY AND PERMANENT TEETH: CASE REPORTS

Aline Borburema **Neves**[1*], Bruna Ribeiro Mattosinhos da Rosa **Fernandes**[1], Laísa Inara Gracindo **Lopes**[1], Andrea Vaz Braga **Pintor**[1], Aline de Almeida **Neves**[1]

[1]Department of Pediatric Dentistry and Orthodontics, Universidade Federal do Rio de Janeiro, Rio de Janeiro, Brazil.

Palavras-chave: Odontopediatria. Cárie Dentária. Infiltrante de Resina.

RESUMO

Introdução: A odontologia minimamente invasiva visa maior preservação da estrutura dentária e novos materiais odontológicos vêm sendo utilizados para este fim. Dentre esses, o Icon® foi desenvolvido para infiltração de lesões de cárie não cavitadas localizadas em esmalte e/ou no terço externo de dentina. **Objetivo**: Relatar dois casos clínicos em que se utilizou o Icon® para tratamento de lesões de cárie interproximais em dentes decíduos e permanentes. **Relato do caso**: Dois pacientes (10 e 13 anos) compareceram à clínica de Odontopediatria da FO-UFRJ e ao exame clínico e radiográfico foram diagnosticadas lesões cariosas não cavitadas no terço externo de dentina e no esmalte dentário, nos dentes 54 distal (D) e 55 mesial (M) (Paciente 1) e dentes 24D e 25M (Paciente 2), respectivamente. Para restauração das lesões, foi utilizado o infiltrante de resina Icon® sob isolamento absoluto e de acordo com as recomendações do fabricante. **Resultados**: Os pacientes foram avaliados imediatamente após a restauração e observou-se um completo selamento da lesão. O paciente 1 retornou para avaliação clínica e radiográfica após 3 meses e o paciente 2 após 1 mês. Em ambos foi detectada paralisação da lesão cariosa. **Conclusão**: Conclui-se que o Icon® representa uma boa opção de material restaurador minimamente invasivo e com boa aplicabilidade em Odontopediatria.

Keywords: Pediatric Dentistry. Dental Caries. Resin Infiltration.

ABSTRACT

Introduction: Minimally invasive dentistry aims to preserve the tooth structure and to achieve this, improved dental materials can be used. Among these, Icon® was developed for infiltration of non-cavitated enamel carious lesions or those located in the external third of dentin. **Objective**: To report two clinical cases in which Icon® was used to treat interproximal caries lesions in primary and permanent teeth. **Case report**: Two patients (10 and 13 years) attended the Pediatric Dental Clinic and the clinical and radiographic examination revealed non-cavitated enamel carious lesions and outer third of dentin on teeth 54 distal (D) and 55 mesial (M) (Patient 1), and teeth 24D and 25M (Patient 2), respectively. To restore the lesions, a resin infiltrant (Icon®) was used under rubber dam isolation and according to the manufacturer's recommendations. **Results**: The patients were assessed immediately after restoration, when complete sealing of the lesion was observed. Patient 1 returned for clinical and radiographic evaluation after 3 months and patient 2 returned after one month, where arrest of the carious lesions was detected. **Conclusion**: It is concluded that Icon® can be a good option of minimally invasive restorative material, with good applicability in Pediatric Dentistry.

Submitted: June 18, 2021
Modification: October 06, 2021
Accepted: October 11, 2021

***Correspondence to**:
Aline de Almeida Neves
Address: Rua Professor Rodolpho Paulo Rocco, 325, Ilha do Fundão, Rio Janeiro, RJ, Brazil. Zip Code: 21941-617
Telephone number: +55 (21) 3938-2097
E-mail: aline.neves@odonto.ufrj.br

INTRODUCTION

Dental caries is currently defined as dysbiosis, as it is triggered by several microorganisms living in the oral cavity and if allowed to grow undisturbed will result in demineralization of the dental structure, unbalancing the process of demineralization and remineralization of the teeth.[1,2] The disease is closely related to a high content of carbohydrate in the diet, combined with poor oral hygiene habits for biofilm control. According to data from The Global Burden of Disease Study, 9% of the world population (621 million people) are affected by caries in primary and 35% (2.4 billion people) in the permanent dentition.[3]

Despite the high prevalence in permanent teeth, a significant decline in the occurrence of caries lesions on occlusal surfaces has been observed, while this decrease has not been observed at approximal surfaces.[4,5] In fact, the prevalence of approximal caries lesions in deciduous molars varies from 30 to 75%.[4,5]

Early diagnosis of approximal caries lesions (active white spots) and non-cavitated dentin lesions has raised great interest because of its clinical implications on treatment decisions. If detected early, these lesions may be treated with preventive strategies and minimally invasive interventions,[6-8] contributing to tooth structure preservation.

Materials such as low viscosity composites, sealants and resin infiltrating agents,[2,4] allowing treatment of caries lesions in a microinvasive way, have been introduced, serving as an alternative for the treatment of active white spot lesions and non-cavitated lesions on the approximal surface located up to the external third of the dentin.[2,5-7,10] Among these materials, a resin infiltrant (Icon® - DMG, Hamburg, Germany) was developed in order to preserve the dental structure and promote the arrest of the carious lesion with a resin-based material.[4-6,9,10] The resin is infiltrated through the lesion by capillary forces, resulting in transportation of methacrylic resins with high penetration (infiltrating) coefficients in the porous enamel.[8,18,20] Conditioning with 15% hydrochloric acid before the infiltration removes the superficial enamel layer, ensuring better penetration of the material.[4,8,18] It can be used in active enamel lesions on smooth surfaces and non-cavitated lesions on the external third of dentin[4,5,6,9,10].

The aim of this study was to report the treatment of approximal non-cavitated caries lesions extending up to the external third of the dentin of primary teeth - 54 and 55 (patient 1) and permanent teeth - 24 and 25 (patient 2), using the resin infiltration technique with Icon®.

CASE REPORTS

CASE 1

G.S.C.C, 10 years-old, female, attended the Pediatric Dentistry Clinic of the Universidade Federal do Rio de Janeiro, accompanied by her mother, for a review consultation. The patient had no history of diseases, allergies, hospitalizations, toothache or dentofacial trauma. Upon clinical examination, a gray shadow, suggestive of undermining carious lesions, was observed on the approximal surfaces of elements 54 (distal) and 55 (mesial). An interproximal radiograph (bitewing) was taken to confirm the presence and evaluate the extent of the lesions (Figure 1A).

According to the International Caries Detection and Assessment System (ICDAS), the lesions were classified as ICDAS 4, with indication for conservative treatment with micro-invasive restorative technique. For treatment of these teeth, the chosen material was the infiltrating resin (Icon®). The Icon® kit consists of separation wedge, approximal matrix, application cannula, Icon-Etch (hydrochloric acid, pyrogenic silicic acid and surface-active substances / 0.3 ml fluid), Icon-Dry (99% ethanol / 0.45 ml fluid) and Icon-Infiltrant (Methacrylate-based resin matrix, initiators and additives / 0.45 ml fluid).

Prophylaxis of the teeth was carried out, using prophylactic paste followed by interpapillary anesthesia (lidocaine 2% + epinephrine 1:100,000, Alphacaine, DFL, Rio de Janeiro, Brazil). In the sequence, absolute isolation and insertion of a separation wedge was performed in the interproximal region of elements 54 and 55, which was maintained until the end of the procedure (Figure 1B-E).

The approximal matrix, attached to the Icon-Etch syringe, was introduced with the green face of the arch and the pores facing the surface of the approximal lesion to be treated (mesial of 55) (Figure 1F). Approximately two turns of the syringe plunger, clockwise, were sufficient for the application of the material. This gel was maintained for two minutes, removed with water jets for thirty seconds and dried with air jets (Figure 1G). The application cannula was threaded into the Icon-Dry syringe which was applied abundantly over the lesion for thirty seconds and then dried with air jets (Figure 1H).

Another approximal matrix was attached to the Icon infiltrant syringe and fitted into the proximal region in the same manner, as previously described. Approximately two turns of the syringe plunger, clockwise, were sufficient for the application of the material. The infiltrant was kept at the location for 3 minutes, after which the matrix was removed and excesses were removed with a dental floss. The material was light-cured for forty seconds. The approximal matrix was attached again for a second application of the Icon-Infiltrant for 1 minute. The dental floss was used to remove the excesses of the material and another 40 seconds light-curing on all faces was performed (Figure 1I-K).

The entire procedure was repeated for the infiltration of the distal surface of tooth 54. At the end of the procedure, rubber dam isolation was removed. The patient was followed up after 3 months of the procedure, when a new interproximal radiography was taken and the arrest of carious lesion was detected (Figure 1L).

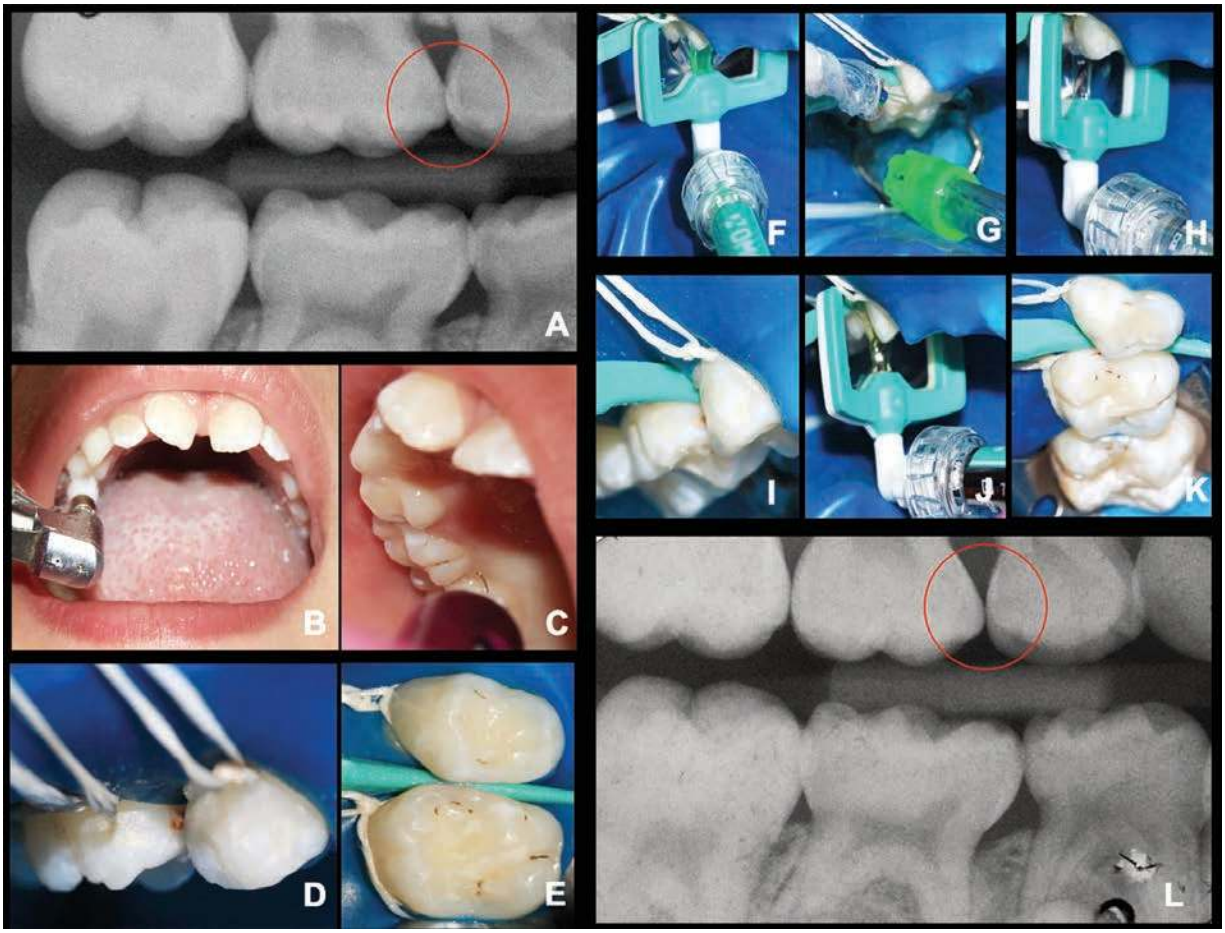

***Figure 1**: Resin infiltration technique on teeth 54 and 55 ICDAS 4. A) initial interproximal radiograph (bite wing); B) Prophylaxis of the teeth using prophylactic paste; C) Interpapillary anesthesia (lidocaine 2% + epinephrine 1: 100,000); D) Isolation with rubber dam; E) Separation wedge provided in the kit inserted into the interproximal region of elements 54 and 55; F) approximal matrix, attached to the Icon-Etch syringe, introduced with the green face of the arch and the pores facing to the surface of the proximal lesion to be treated; G) Removal of the gel with water and air jets; H) Icon-Dry syringe; I) approximal region; J) Icon-Infiltrant syringe fitted into the proximal region; K) Dental floss was used to remove the excesses of the material; L) Interproximal radiography after 3 months follow-up showing the filling of the cavity by the resinous infiltrate (Icon®).*

CASE 2

M.S.A., 13 years-old, male, attended the Pediatric Dentistry Clinic of the *Universidade Federal do Rio de Janeiro*, accompanied by his mother, for a routine evaluation. During the anamnesis, the patient's mother reported that he had bronchitis, used a pump and had food allergies (lactose and some food colorings). The patient had no history of dento-facial pain or trauma.

During the clinical examination, it was observed that the patient had high caries activity, with cavitated carious lesions and other non-cavitated lesions. Visible biofilm was observed on all mandibular sextants, without gingival bleeding. Right and left interproximal radiographs (bite wing) were taken to evaluate the extent of the approximal and occlusal caries lesions. Approximal lesions were observed in elements 24 (distal face) and 25 (mesial face), affecting only enamel (Figure 2A). The lesions were classified as ICDAS 2, indicating conservative treatment with a micro invasive restorative technique. The chosen material was the infiltrating resin (Icon®).

Prophylaxis of the dental elements was carried out and interpapillary anesthesia (lidocaine 2% + epinephrine 1: 100,000) was applied before rubber dam isolation. After this, the separation wedge, present in the kit, was inserted into the interproximal region of elements 24 and 25 and it was kept until the end of the procedure (Figure 2B and C).

The restorative procedures were conducted for the distal face of teeth 24 and mesial face of teeth 25 in the same manner as described in the case 1 (Figure 2D-I). Patient 2 was re-evaluated after one month and it could be seen that the lesion has not further progressed (Figure 2J).

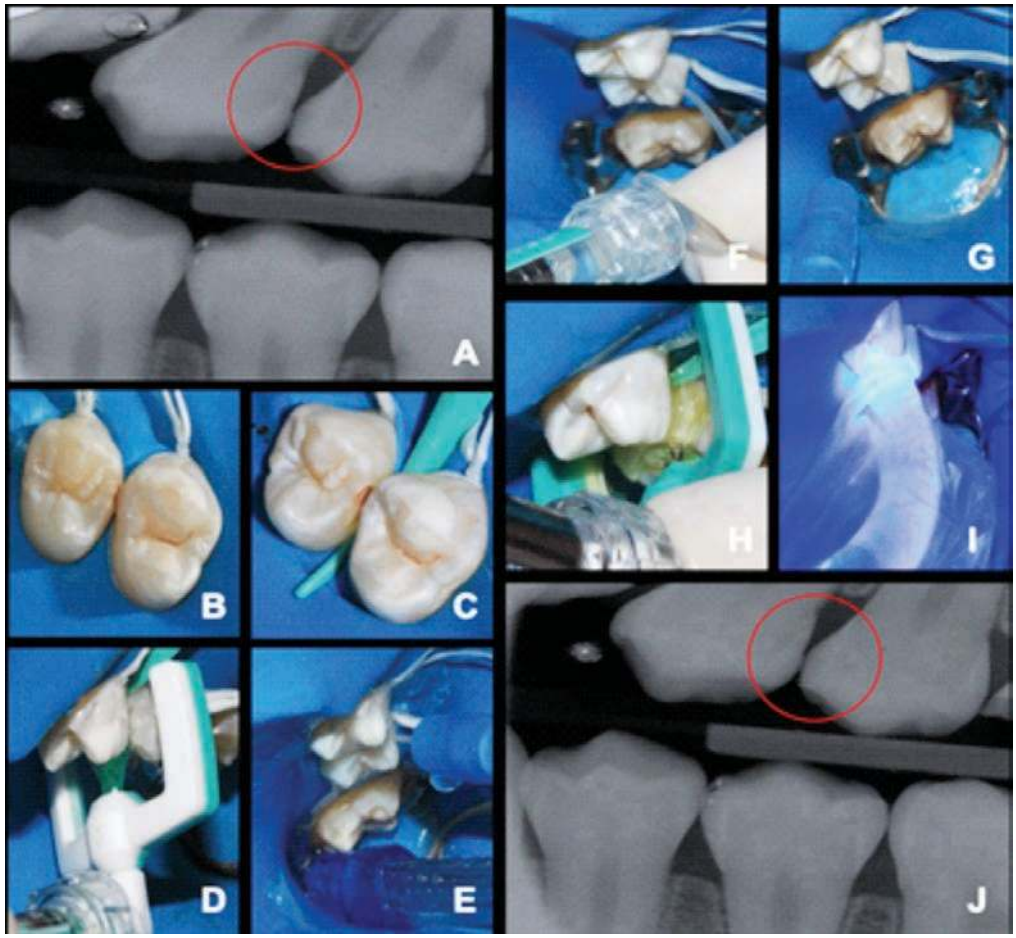

***Figure 2**: Resin infiltration technique of the proximal caries lesion on teeth 24 and 25 ICDAS 2. A) Initial interproximal radiography. B) Isolation with rubber dam. Non-cavitated caries lesion in enamel is observed on the distal surface of the tooth 24 and mesial of the tooth 25; C) Separation wedge inserted into the interproximal region; D) Icon-Etch syringe, introduced with the green face of the arch and the pores facing to the surface of the proximal lesion to be treated; E) Removal of the gel with water and air jets; F) Icon-Dry syringe; G) Removal of the material with water and air jets; H) Icon-Infiltrant syringe into the approximal region; I) Light-curing; J) Interproximal radiography after 1 month follow-up showing the sealing of the non-cavitated carious lesion in the enamel by the resinous infiltrate (Icon®).*

DISCUSSION

The present reports aimed to describe the clinical treatment of non-cavitated carious lesions in primary and permanent teeth. Infiltration of non-cavitated carious lesions up to the external third of the dentin is characterized by the obliteration of the pores of the lesion body with the resin material, preventing the diffusion of the cariogenic acids and the consequent progression of the lesion.[1,5,6] This obliteration is accomplished through infiltration using a special low-viscosity, photopolymerizable resin that stops demineralization, stabilizes the caries lesion and acts as a surface mechanical barrier, inhibiting external bacterial colonization.[1,4-7,9,10]

Resin infiltration differs from resin-based sealants because it shows higher permeability after conditioning with hydrochloric acid (HCl) and pre-treatment with alcohol at 99%.[1,6] The 15% HCl is used to increase the microporosity of the enamel while alcohol helps to dry the lesion, which favors enamel penetration by the low viscosity infiltrate.[4,18] The infiltration of caries lesions uses capillary forces to transport methacrylic resins with high penetration coefficients into the porous enamel.[4,10,18,21] HCl 15% is used, instead of 37% phosphoric acid in order to remove the pseudo-intact surface layer of enamel.[4,18]

It has been described the average penetration of the infiltrating agent inside carious enamel is approximately 99.1% while for dentin lesions, this percentage is around 82.0%.[19] Due to the lower percentage of penetration into dentin lesions, its is not indicated in lesions beyond the external third of dentin (lesions type D2 and D3), being used only in enamel and external third of dentin lesions (E1, E2 and D1).[6,11] The barrier formed by the resinous infiltrate promotes an isolation of the external bacteria, but it is still unclear whether it is able to control bacteria present in the dentin lesion by the histological difference of its structure.[1,4,5]

The most recent technique of infiltration of carious lesions uses Icon® (DMG, Hamburg, Germany), which is a new treatment option for the control of approximal and buccal caries lesions.[4-7,9,10] The infiltrating agent acts differently from the sealant, since this remains on the surface of the lesion, sealing it while the resin infiltrate penetrates into the micropores of the lesion, filling them and preventing the diffusion of the cariogenic acids and progression of the lesion.[4-8,10] It follows the principle of minimally invasive intervention, avoiding the destruction of healthy dental tissue and preserving the dental structure.[5,6]

The effectiveness of the resinous infiltrate in stopping the progression of non-cavitated proximal caries lesions in deciduous and permanent teeth has been reported in several studies,[12-14] with short and medium term efficacy. However, for the analysis of long-term efficacy, there is a need for more randomized controlled trials to increase the scientific evidence.[5,15-17]

An *in vitro* study found that infiltrated lesions are resistant to discoloration.[10] An ex vivo study concluded that the longer the time of material application, greater and deeper will be the penetration of the infiltrate.[11] Studies with micro-CT have disclosed that the resinous infiltrate has a favorable result regarding the inhibition of the progression of lesions of artificial enamel in deciduous and permanent teeth and its use in combination with fluoride can result in additional inhibition.[9]

Although Icon® (DMG, Hamburg, Germany) presents satisfactory results and has the advantage of the preservation of sound dental structure through the penetration of a resin of low viscosity within the pores of the lesion,[4-8,10] its disadvantage and consequent limitation of its use includes the high cost, the need of rubber dam use and the long clinical time required. For this reason, it is currently not accessible to the Public Health System. Additionally, there is a certain complexity in its use and a careful reading of the manufacturer's instruction and/or a step-by-step teaching course may be necessary for an effective clinical conduction.

As a limitation of the present case report, we cite the fact that the long-term follow-up of each clinical case was performed at different times, and this because both cases were performed in two distinct periods. Unfortunately, due to the Pandemic of COVID-19 there was no possibility of extending the follow-up of the cases at this point. However, the patients will continue to be followed clinically and radiographically over time as soon as the return of the clinical activities is possible.

Thus, it can be concluded that resin infiltration represents an alternative for a minimally invasive treatment of non-cavitated proximal carious lesions in enamel and/or in the external third of dentin, with satisfactory results.

REFERENCES

1. Simón-Soro A, Mira A. Solving the etiology of dental caries.Trends Microbiol. 2015 Feb 23(2):76-82. doi: 10.1016/j.tim.2014.10.010.

2. Liang Y, Deng Z, Dai X, Tian J, Zhao W. Micro-invasive interventions for managing non-cavitated proximal caries of different depths: a systematic review and meta-analysis. Clin Oral Investig. 2018 Nov 22(8): 2675-2684. doi: 10.1007/s00784-018-2605-9.

3. Kassebaum NJ, Bernabe E, Dahiya M, Bhandari B, Murray CJL, Marcenes W. Global Burden of Untreated Caries: A systematic review and metaregression. J Dent Res. 2015 May 94(5): 650-8. doi: 10.1177/0022034515573272.

4. Chatzimarkou S, Koletsi D, Kavvadia K. The effect of resin infiltration on proximal caries lesions in primary and permanent teeth. A systematic review and meta-analysis of clinical trials. J Dent. 2018 Oct 77:8-17. doi: 10.1016/j.jdent.2018.08.004.

5. Ammari MM, Jorge RC, Souza IPR, Soviero VM. Efficacy of resin infiltration of proximal caries in primary molars: 1-year follow-up of a split-mouth randomized controlled clinical trial. Clin Oral Investig. 2018 Apr 22(3): 1355-1362. doi: 10.1007/s00784-017-2227-7

6. Paris S, Meyer-Lueckel H. The potential for resin infiltration technique in dental practice. Dent Update. 2012 Nov 39(9): 623-6,628. doi: 10.12968/denu.2012.39.9.623.

7.Dorri M, Dunne SM, Walsh T, Schwendicke F. Micro-invasive interventions for managing proximal dental decay in primary and permanent teeth. Cochrane Database Syst Rev. 2015 Nov 5;(11):CD010431. doi: 10.1002/14651858.CD010431.pub2.

8. Paris S, Meyer-Lueckel H. Inhibition of caries progression by resin infiltration in situ. Caries Res. 2010 44(1):47-54. doi: 10.1159/000275917.

9. Ozgul BM, Orhan K, Oz FT. Micro-computed tomographic analysis of progression of artificial enamel lesions in primary and permanent teeth after resin infiltration. J Oral Sci. 2015 57;3:177-183. doi: 10.2334/josnusd.57.177.

10. Paris S, Schwendicke F, Keltsch J, Dörfer C, Meyer-Lueckel H. Masking of white spot lesions by resin infiltration in vitro. J Dent. 2013 Nov 41Suppl 5:e28-34. doi: 10.1016/j.jdent.2013.04.003.

11. Soviero VM, Paris S, Leal SC, Azevedo RB, Meyer-Lueckel H. Ex vivo evaluation of caries infiltration after different application times in primary molars. Caries Res. 2013 47(2):110-116. doi: 10.1159/000345065.

12. Paris S, Hopfenmuller W, Meyer-Lueckel H. Resin infiltration of caries lesions: an efficacy randomized trial. J Dent Res. 2010 Aug 89(8):823-826. doi: 10.1177/0022034510369289.

13. Meyer-Lueckel H, Bitter K, Paris S. Randomized controlled clinical trial on proximal caries infiltration: three-year follow up. Caries Res. 2012 46:544-548. doi: 10.1159/000341807.

14. Meyer-Lueckel H, Balbach A, Schikowsky C, Bitter K, Paris S. Pragmatic RCT on the efficacy of proximal caries infiltration. J Dent Res. 2016 May 95(5):531-6. doi: 10.1177/0022034516629116.

15. Ammari MM, Soviero VM, Fidalgo TKS, Lenzi M, Ferreira DMTP, Mattos CT et. al. Is non cavitated proximal lesion sealing an effective method for caries control in primary and permanent teeth? A systematic review and meta-analysis. J Dent. 2014 Oct 42(10): 1217-1227. doi: 10.1016/j.jdent.2014.07.015.

16. Doméjean S, Ducamp R, Léger S, Holmgren C. Resin infiltration of non-cavited caries lesions: A systematic review. Med Princ Prac. 2014 24(3):216-21. doi: 10.1159/000371709.
17. Paris S, Bitter K, Krois J, Meyer-Lueckel H. Seven-year-efficacy of proximal caries infiltration - Randomized clinical trial. J Dent. 2020 Feb;93:103277. doi: 10.1016/j.jdent.2020.103277.
18. Paris S, Meyer-Lueckel H, Kielbassa AM. Resin infiltration of natural caries lesions. J Dent Res. 2007 July;86(7): 662-666. doi: 10.1177/154405910708600715.
19. Liu YH, Ge LH, Zhang ZY, Chi XQ, Hou FC, Chen HZ. An experimental study on the penetration abilities of resin infiltration into proximal caries lesions in primary molars. Zhonghua Kou Qiang Yi Xue Za Zhi, 2012 Nov 47(11):684-688. doi: 10.3760/cma.j.issn.1002-0098.2012.11.011.
20. Paris S, Meyer-Lueckel H, Cölfen H, Kielbassa AM. Resin infiltration of artificial enamel caries lesions with experimental light curing resins. Dent Mater J. 2007 July 26(4): 582-588. doi: 10.4012/dmj.26.582.
21. Paris S, Meyer-Lueckel H, Mueller J, Hummel M, Kielbassa AM. Progressions of sealed initial bovine enamel lesions under demineralizing conditions in vitro. Caries Res. 2006 40(2):124-129. doi: 10.1159/000091058.