DIGITAL WORKFLOW USING NATURAL ALGORITHMS FOR CAD/CAM CERAMIC ANTERIOR AND OCCLUSAL VENEERS TO RESTORE BIOCORROSION: A 2-YEAR FOLLOW-UP CASE REPORT

Líssya Tomaz da Costa **Gonçalves**[1], Ângelo Raphael Toste Coelho **Segundo**[1], Terumitsu Sekito **Junior**[1], Fernanda Cunha **Marins**[1], Aline Raybolt dos **Santos**[1], Tayane Holz **Resende**[1*], Luís Henrique **Schlichting**[2]

[1]Department of Prosthodontics and Dental Materials, School of Dentistry, Universidade Federal do Rio de Janeiro - UFRJ, Rio de Janeiro, Brazil.
[2]Division of Comprehensive Oral Health, The University of North Carolina - UNC, Adams School of Dentistry, Chapel Hill, NC, USA.

Palavras-chave: Relato de Caso. Erosão Dentária. Desenho Assistido por Computador.

RESUMO

Introdução: A biocorrosão é uma desordem multifatorial que provoca a dissolução dos tecidos dentários por fatores extrínsecos e/ou intrínsecos. Tradicionalmente restaurar estes desgastes envolve preparos invasivos. **Objetivo**: Este relato de caso objetiva descrever a reabilitação da biocorrosão utilizando abordagem minimamente invasiva, envolvendo laminados cerâmicos finos oclusais e vestibulares por fluxo totalmente digital utilizando algoritmos naturais. **Relato do caso**: Paciente de 23 anos procurou atendimento odontológico apresentando desgastes dentários generalizados associados a hipersensibilidade dentinária. Na anamnese constatou-se distúrbio alimentar e elevado consumo de alimentos ácidos, suportando o diagnóstico de biocorrosão. A recuperação dos tecidos desgastados anteriores envolveu uma abordagem aditiva (minimizando desgastes adicionais), utilizando um protocolo de planejamento guiado pela face e um banco de anatomias de dentes naturais para alcançar maior naturalidade na finalização do caso. A reabilitação dos tecidos desgastados foi realizada através de laminados cerâmicos oclusais, anteriores e restaurações em resina composta. Os dentes e as características naturais da paciente foram preservadas, restabelecendo a estética e auto-estima da paciente que permanece muito satisfeita após o acompanhamento de 2 anos. **Conclusões**: Abordagens aditivas envolvendo a menor quantidade de desgastes possível são imprescindíveis para a restauração da biocorrosão. Além disso, a integração de algoritmos naturais ao CAD/CAM traz mais estética, precisão e naturalidade para as restaurações definitivas, superando um dos principais desafios das restaurações estéticas obtidas por fluxo digital que é a naturalidade.

Keywords: Case Report. Tooth Erosion. Computer-Aided Design.

ABSTRACT

Introduction: Biocorrosion is a multifactorial disorder that causes dissolution of hard tissues by extrinsic/ intrinsic factors. Traditionally, restoring biocorrosion wear involves invasive preparations. **Objective**: This case report aims to describe the rehabilitation of biocorrosion with a minimally invasive approach (thin occlusal and vestibular ceramic laminates) in a fully digital workflow using natural algorithms. **Case report**: A 23-year-old patient was presented to clinic with generalized tooth wear associated to dentin hypersensitivity. In anamnesis, eating disorders and acid food consumption were reported, supporting the diagnosis of biocorrosion. The restoration of worn tissues involved an additive approach (minimizing additional wear), using a face guided planning protocol and a natural tooth anatomy database to achieve greater naturalness at the final restorations. Rehabilitation of worn tissues was performed using occlusal, anterior ceramic veneers and additive composite restorations. The patient's natural teeth characteristics were preserved, restoring aesthetic and self-esteem, and after 2-year follow-up the patient remains very satisfied. **Conclusion**: Additive approaches involving the least amount of tissue wear are essential for the biocorrosion restoration. In addition, the integration of natural algorithms to digital workflows brings more aesthetic and precision to definitive restorations, overcoming one of the main challenges of milled aesthetic restorations: the naturalness.

Submitted: February 21, 2021
Modification: September 27, 2021
Accepted: October 14, 2021

***Correspondence to:**
Tayane Holz Resende
Address: Av. Professor Rodolpho Paulo Rocco, 325, Ilha do fundão, Cidade Universitária, Rio de Janeiro, RJ, Brazil. Zip Code 21941-617
Telephone number: +55 (21) 9 7541-3000
E-mail: tayaneholz@hotmail.com

INTRODUCTION

Biocorrosion is a multifactorial disorder characterized by dissolution of dental hard tissue. It is modulated by the physiological properties of saliva, and acidic sources, such as eating disorders or gastric reflux (intrinsic) or the high consumption of acidic drinks and food (extrinsic), besides habits and lifestyle.[1] The tissue loss can cause biological, aesthetic and functional consequences.[2] Traditionally, full-crown coverage is recommended for dental erosion rehabilitation. However, in young patients this approach is considered too aggressive.[3]

The development of stronger materials, combined with improved bonding protocols have paved the way for minimally invasive restorative designs, such as bonded posterior occlusal Computer-Aided Design/Computer-Aided Manufacturing (CAD/CAM) veneers for the treatment of biocorrosion.[4] Additionally, advances in CAD/CAM technology, and more resistant materials have led to better consistency in thickness and anatomy during the manufacturing process,[5] especially for veneers which are extremely thin and demand high levels of skill from laboratory technicians.[6]

In this context, digital tools for the planning of milled restorations have become popular in dentistry. Among them, Digital Smile Design (DSD) is a tool that allows aesthetic rehabilitative planning from a facial perspective. The planning integrates the functional, aesthetic and emotional needs of the patient, besides making it easier to communicate with the patient and the multidisciplinary team. The use of digital models allows three-dimensional (3D) planning by digital waxing based on DSD, enabling greater predictability for the final restorations.[7] This digital flow gives the patient access to the planned result before starting treatment,[8] assisting in aesthetic case evaluation and management of expectations.

The integration between digital diagnostic tools, such as digital models and patient photographs, associated to the use of natural teeth morphologies enabled the development of DSD Natural Restoration (DSD NR). The DSD NR concept is a fully digital workflow with the objective of reproducing monolithic ceramic restorations using a digital database with natural algorithms.[9] In this workflow, natural teeth morphologies are used, providing naturalness and richness of detail, resulting in more aesthetic and authentic anatomy for digital cases. Monolithic milled restorations can accurately reproduce the concept of natural restorations, whereas the handmade copy would include personal artistic features to the anatomy during layering and finishing procedures.[8]

In this context, this case report aims to present a fully digital aesthetic rehabilitation involving: CAD/CAM occlusal veneers and anterior veneers based on the natural teeth algorithm library in the DSDApp: The so called DSD NR. This report is in accordance with a previous article[2] where ultrathin ceramic CAD/CAM veneers were utilized. In contrast, for anterior veneers, DSD-NR were utilized. DSD-NR was encouraged for aesthetic improvement based on donation of natural teeth anatomies.

CASE REPORT

A 23-year-old woman was presented to the Department of Prosthodontics and Dental Materials at the Universidade Federal do Rio de Janeiro in 2018 requesting treatment for dentin sensitivity and dental wear. The patient was unsatisfied with the appearance of her smile (Figure 1A).Intraoral evaluation revealed generalized loss of enamel with characteristics signs of moderate dental wear with smooth and concave lesions showing clinical evidences of dental biocorrosion (Figure 1B and C).

During anamnesis, the patient reported the consumption of acidic foods and a history of bulimia, as well as possible teeth grinding and jaw clenching. Thus, the patient was advised to reduce acid consumption, and assigned medical and psychological monitoring for her eating disorder.

The treatment plan proposed was a fully digital rehabilitation: DSD planning; upper anterior crown lengthening using perio guide;[10] CAD/CAM occlusal veneers for the reestablishment of the vertical dimension of occlusion (VDO),[2,11] direct composite on lower anterior sextant and bilaminar approach (lingual direct composite restorations and labial CAD/CAM ceramic veneers)[12] on the maxillary anterior sextant. The patient agreed with the planning and signed the Free, Prior and Informed Consent (FPIC) to start the treatment.

At first, the DSD photographic protocol[13] was paired to the dynamic documentation of the smile (video), upper and lower arches scans. A Lucia JIG was made in order to register maxillomandibular relationship in centric relation and it was also scanned. The scanned models were articulated in a digital articulator to receive digital wax-up, increasing 1,5mm of vertical dimension of occlusion (VDO).[14] Then, a 2D DSD was performed in the DSDApp (Figure 1D) using the software's natural teeth library. It played a key role in reproducing the naturalness in the digital workflow.Teeth shape could be selected to better harmonize with patient's expression.[15] Next, the 2D planning was exported from the DSDApp to Nemo Smile Design 3D (Nemotec) where additional editing was performed in order to generate the motivational wax-up design. In this step, the new smile and gingival architecture is planned, based on DSD App suggested measurements.

Then, the waxed model was printed, followed by the mock-up fabrication. Upon the patient's approval, a perio guide was outlined, printed and used for the guided surgical crown lengthening. After 45 days, the motivational wax-up was adjusted to the new post-surgical digitalized arch, giving rise to the final wax-up with the "ideal design". Then, the ideal wax-up posterior multifunctional provisional (test of the new maxillo-mandibular position, functional adaptation, aesthetics and preparation guide) was printed. The anterior model was printed and copied by transparent silicone guides (Elite Transparent, Zhermack) for the flowable composite injection,[14] performing the provisional restorations (Figure 2A-D) to test the new augumented VDO.

Once the posterior ceramic occlusal veneers were completed following the same protocol established in a previous article,[2] temporary injected restorations were also used as preparation guides to the labial ceramic veneers. The preparation through the mock-up yielded a clearance ranging from about 0.5 mm cervically to 0.8mm incisally.

After scanning, the digital wax-up was superimposed and fitted to the preparation's STL file model preserving the original approved anatomy (Nemo Smile Design 3D, Nemotec): the so called design over the prep. This tool allows for maintenance of the original proposal approved by the patient (DSD App natural teeth library - model F07) during the planning stage. The final design was exported to the software containing milling parameters (InLab SW19, Dentsply Sirona), and leucite-reinforced glass ceramic blocks (A1, IPS Empress Multi, IvoclarVivadent) were milled, stained and glazed finishing the digital workflow (Figure 3)

The restorations were adhesively luted with composite resin (A1, Filtek Z100, 3M) preheated to 68ºC (Calset, Addent Inc.) following the previously established protocol.[2] At the following appointment, the upper arch was scanned and a digital wax-up (Nemo Smile Design 3D, Nemotec) was performed and copied with transparent silicon to guide the final restoration of premolars.[14] Finally, the disocclusion guides were evaluated and adjusted.

A printed occlusal splint (Cosmos splint, Yller) was designed and milled, as well as monitoring the patient's daytime tightness, aiming to control the parafunctional habit and increase longevity to the performed treatment. Likewise, the patient was advised to keep up with the treatment for eating disorders as well as maintaining a controlled acid diet. Upon completion of the treatment, the patient expressed great satisfaction and enthusiasm with her new smile´s frontal, side and intraoral view (Figure 4A-C). A clinical follow-up after 2 years of treatment (Figure 4D-F). can be observed.



***Figure 1**: A) Initial aspect of smile. Intraoral occlusal aspect; B) Superior and C) Inferior. D) 2D planning before and after performed in DSDApp.*

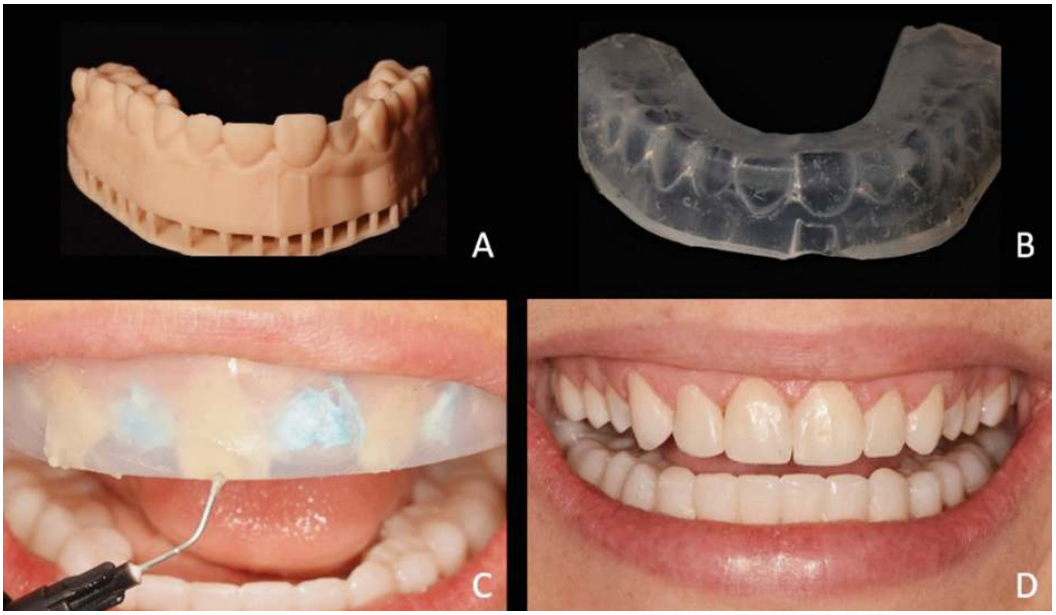

***Figure 2**: A) Printed model with every other alternate tooth waxed-up; B) and respective transparent silicone guide. C) Injection of flowable composite through a hole in silicon guide at the incisal edge. Neighbor teeth were protected with Teflon tape. The process was repeated with a second guide. D) Smile with mock-up injected restorations.*

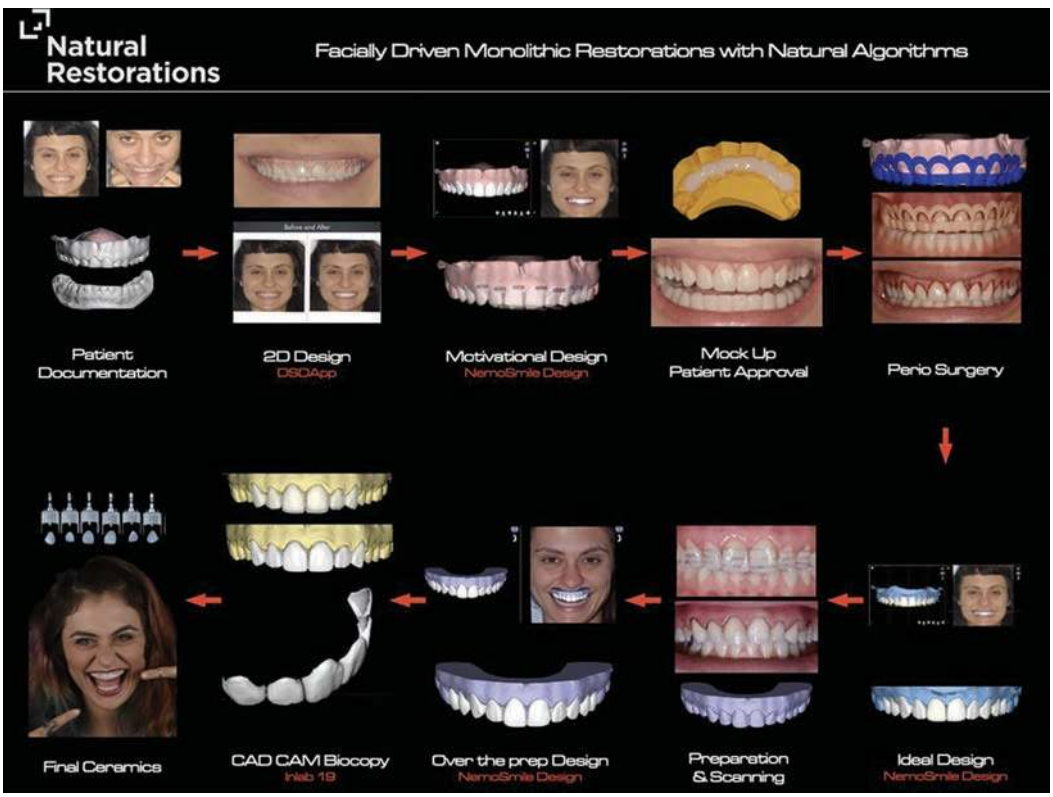

***Figure 3**: DSD-NR Flow chart: From patient documentation to final milled restorations.*



***Figure 4**: A) Final aspect of smile. Facial DSD-NR veneers giving naturalness showing natural color, design and texture. B and C) Final proximal and facial view of intraoral aspect after rehabilitation. D and E) Buccal and proximal view of smile and F) occlusion aspect after 2-year follow-up.*

DISCUSSION

Digital workflow was a watershed in prosthodontics,[15] showing as the main advantages: reduced production cost,[16] increased cost-benefit,[17] adequate internal and marginal adaptation of the restorations obtained by scanning, besides the perception of patient safety.[18] Digital workflow is also an excellent alternative to reproduce digital aesthetic restorations identical to planning, increasing the predictability and reliability of the treatment.[9] In contrast with its predictability, efficiency and improved resistance of CAD/CAM materials, artisanal techniques may contain imperfections incorporated during confection, for this reason the digital workflow was chosen for this case report.[16]

Regarding bonding strategy, the clinical advantages to Immediate Dentin Sealing[17] associated to preheated composite, such as a luting agent are supported by clinical[2,11,17] and laboratory[4] evidence. They include longer worktime, less formation of interfacial voids associated to low viscosity,[18] ideal consistency for seating and excess removal. For posterior indirect restorations, preheated composite is ideal because of the higher filler content and degree of conversion, resulting in better mechanical properties.[6,19]

Further research is required to assess the clinical performance of ultrathin occlusal veneers. For this reason, the present case report is part of an ongoing clinical trial at the Dental School of the Federal University of Rio de Janeiro. This treatment has been applied successfully to restore biocorrosion dental wear, and our perspective reinforces this modality as a protocol. On the other hand, the treatment met patient's expectations bringing back the confidence to smile with the most tissue preservation possible for this case involving hard tissues wear.

CONCLUSION

This case report demonstrates the feasibility of restoring biocorrosion dental wear in a digital workflow using occlusal and anterior CAD/CAM veneers.

This minimally invasive approach was successful due to the conservation of the dental tissue, aesthetics and previsibility confirmed by the reevaluation after 2 years.

The digital planning and workflow led to less chair time at the clinical steps.

The use of DSD-NR provided more aesthetic anterior ceramic veneers, since it is one of the biggest challenges involved in CAD/CAM restorations. The software library is not able to reproduce natural teeth anatomy, texture and final aesthetic as DSD-NR donation of anatomy enabled.

REFERENCES

1. Lussi A, Schlueter N, Rakhmatullina E, Ganss C. Dental erosion-an overview with emphasis on chemical and histopathological aspects. Caries Res. 2011;45 Suppl 1:2-12. doi: 10.1159/000325915.
2. Resende TH, Reis KR, Schlichting LH, Magne P. Ultrathin CAD-CAM Ceramic Occlusal Veneers and Anterior Bilaminar Veneers for the Treatment of Moderate Dental Biocorrosion: A 1.5-Year Follow-Up. Oper Dent. 2018 Jul/Aug;43(4):337-346. doi: 10.2341/17-007-T.
3. Vailati F, Belser UC. Full-mouth adhesive rehabilitation of a severely eroded dentition: the three-step technique. Part 1. Eur J Esthet Dent. 2008 Spring;3(1):30-44.

4. Schlichting LH, Maia HP, Baratieri LN, Magne P. Novel-design ultra-thin CAD/CAM composite resin and ceramic occlusal veneers for the treatment of severe dental erosion. J Prosthet Dent. 2011 Apr;105(4):217-26. doi: 10.1016/S0022-3913(11)60035-8.
5. Beuer F, Schweiger J, Edelhoff D. Digital dentistry: an overview of recent developments for CAD/CAM generated restorations. Br Dent J. 2008 May 10;204(9):505-11. doi: 10.1038/sj.bdj.2008.350.
6. Magne P, Belser U. Laboratory Procedures. In: Magne P, Belser U. Bonded Porcelain Restorations in the Anterior Dentition: A Biomimetic Approach. Berlin: Quintessence Publishing, 2002:293-334.
7. Coachman C, Calamita M, Schayder A. Digital smile design: uma ferramenta para planejamento e comunicação em odontologia estética. RevBrasDicas Odontol.2012;1:36-41.
8. Castro C, Saraiva S, Raphael A. DSD Natural Restoration: Sorrisos digitais e mais naturais. In: Uehara T, Sousa EL (eds). Clássico e Digital: o elo de equilíbrio entre as especialidades na prótese odontológica. São Paulo: Quintessence/Editora Napoleão;2020.
9. Saraiva S, Raphael A, Castro C. DSD Natural Restoration: Evolução no conceito DSD na busca por sorrisos naturais. In: Fonseca M (ed.) The Aesthetics Yearbook. São Paulo: Quintessence/EditoraNapoleão;2018.
10. Longo E, Frosecchi M, Marradi L, Signore A, de Angelis N. Guided periodontal surgery: a novel approach for the treatment of gummy smile. A case report. Int J Esthet Dent. 2019;14(4):384-392.
11. Schlichting LH, Resende TH, Reis KR, Magne P. Simplified treatment of severe dental erosion with ultrathin CAD-CAM composite occlusal veneers and anterior bilaminar veneers. J Prosthet Dent. 2016 Oct;116(4):474-482. doi: 10.1016/j.prosdent.2016.02.013.
12. Vailati F, Belser UC. Classification and treatment of the anterior maxillary dentition affected by dental erosion: the ACE classification. Int J Periodontics Restorative Dent. 2010 Dec;30(6):559-71.
13. Coachman C, Calamita MA, Sesma N. Dynamic Documentation of the Smile and the 2D/3D Digital Smile Design Process. Int J Periodontics Restorative Dent. 2017 Mar/Apr;37(2):183-193. doi: 10.11607/prd.2911.
14. Úry E, Fornai C, Weber GW. Accuracy of transferring analog dental casts to a virtual articulator. J Prosthet Dent. 2020 Feb;123(2):305-313. doi: 10.1016/j.prosdent.2018.12.019.
15. Coachman C, Ricci A, Calamita M, Yoshinaga LG. Desenho digital do sorriso: do plano de tratamento à realidade clínica. In: Paolocci B (ed.) Visagismo - A arte de personalizar o desenho do sorriso. São Paulo: VM Cultural Editora Ltda 2011; 145-160.
16. Mainjot AK, Dupont NM, Oudkerk JC, Dewael TY, Sadoun MJ. From Artisanal to CAD-CAM Blocks: State of the Art of Indirect Composites. J Dent Res. 2016 May;95(5):487-95. doi: 10.1177/0022034516634286.
17. Schulte AG, Vöckler A, Reinhardt R. Longevity of ceramic inlays and onlays luted with a solely light-curing composite resin. J Dent. 2005 May;33(5):433-42. doi: 10.1016/j.jdent.2004.10.026.
18. Lee JH, Um CM, Lee IB. Rheological properties of resin composites according to variations in monomer and filler composition. Dent Mater. 2006 Jun;22(6):515-26. doi: 10.1016/j.dental.2005.05.008.
19. Daronch M, Rueggeberg FA, De Goes MF, Giudici R. Polymerization kinetics of pre-heated composite. J Dent Res. 2006 Jan;85(1):38-43. doi: 10.1177/154405910608500106.