THE EFFECT OF A CHEMOMECHANICAL PROTOCOL TO ELIMINATE MICROORGANISMS FROM PULPECTOMIZED PRIMARY TEETH: THREE CASE REPORTS

Maysa Lannes **Duarte**[1], Daniele Vieira **Cassol**[1], Carolina Barbosa **Andrade**[1], Natalia Lopes Pontes **Iorio**[2], Andréa **Fonseca-Gonçalves**[1], Laura Guimarães **Primo**[1]

[1]Department of Pediatric Dentistry and Orthodontics, School of Dentistry, Universidade Federal do Rio de Janeiro, Rio de Janeiro, RJ, Brazil.
[2]Department of Basic Formation, School of Dentistry, Universidade Federal Fluminense, Nova Friburgo, RJ, Brazil.

Palavras-chave: Pulpectomia. Dente Decíduo. Microbiota. Camada de Esfregaço. Relatos de Casos.

RESUMO

Introdução: A descrição da comunidade bacteriana antes e após o preparo químico-mecânico (PQM) com remoção da *smear layer* (SL) em dentes decíduos pulpectomizados tem sido pouco relatada. **Objetivo**: Esses relatos de casos descrevem a presença de microrganismos totais e *Enterococcus faecalis* em canais radiculares de incisivos decíduos antes e após PQM com remoção de SL. **Relatos dos Casos**: Amostras microbiológicas foram coletadas do canal radicular de três crianças (3,66 ± 0,58 anos) com necrose (n = 2) e inflamação pulpar irreversível (n = 1) em incisivos decíduos superiores. Após o isolamento dos dentes com dique de borracha e antissepsia do campo operatório, as coletas das amostras foram realizadas com cones de papel absorvente estéril antes e após o PQM, que incluiu irrigação com hipoclorito de sódio 2,5% seguido de ácido cítrico 6% para retirada do SL. As amostras coletadas foram analisadas imediatamente ao final dos procedimentos clínicos. As placas foram incubadas em anaerobiose durante 48 horas a 37°C. Os resultados foram expressos em unidades formadoras de colônias (UFC)/mL. **Resultados**: Dois dos três dentes apresentaram microrganismos totais antes do PQM. Um incisivo não apresentava microrganismos na coleta inicial. Nenhuma UFC foi contada nas amostras coletadas após o PQM. Além disso, o *E. faecalis* não foi observado nenhum momento, nem antes, nem depois do PQM. **Conclusão**: Não foi detectado *E. faecalis* em nenhuma amostra, porém dois dos três canais radiculares apresentavam microrganismos antes do PQM. Nos casos em que foram encontrados microrganismos inicialmente, observou-se 100% de eliminação após o protocolo aplicado.

Keywords: Pulpectomy. Primary Teeth. Microbiota. Smear Layer. Case Reports.

ABSTRACT

Introduction: Description of the bacterial community before and after chemomechanical preparation (CP) with the removal of a smear layer (SL) in pulpectomized primary teeth has been little reported. **Objective**: These case reports describe the presence of total microorganisms and *Enterococcus faecalis* in root canals of primary incisors before and after CP with SL removal. **Case Reports**: Microbiological samples were collected from the root canals of three children (3.66±0.58 years old) with necrosis (n=2) and irreversible pulpal inflammation (n=1) in maxillary primary incisors. After teeth isolation with a rubber dam and antisepsis of the operative field, the sample collections were performed with sterile absorbent paper cones before and after the CP, which included irrigation with 2.5% sodium hypochlorite followed by 6% citric acid to remove the SL. The collected samples were analysed immediately at the end of the clinical procedures. The plates were incubated anaerobically for 48 hours at 37°C. The results were expressed as colony forming units (CFU)/mL. **Results**: Two of the three teeth showed total microorganisms before the CP. One incisor had no microorganisms in the initial collection. No CFU was counted in the samples collected after CP. Moreover, *E. faecalis* was not observed any time, either before or after the CP. **Conclusions**: *E. faecalis* was not detected in any sample, yet two of the three root canals had microorganisms before CP. In cases where microorganisms were initially found, 100% elimination was observed after the applied protocol.

Submitted: December 29, 2020
Modification: March 02, 2021
Accepted: March 18, 2021

***Correspondence to:**
Professor Dr. Laura Guimarães Primo
Disciplina de Odontopediatria da FO-UFRJ
Address: Av. Prof. Rodolpho Paulo Rocco, 325 – Cidade Universitária – CCS - CEP: 21941-913 - Rio de Janeiro – RJ –Brazil Fax/phone: +55 21 3938-2098
E-mail: lprimo@pobox.com

INTRODUCTION

Several irrigating solutions have been indicated to disinfection of root canal of primary teeth, with an emphasis on sodium hypochlorite (NaOCl) at different concentrations.[1,2] However, although NaOCl has good disinfection properties, it is ineffective in removing the smear layer (SL).[3] When the SL is not removed, it may have a detrimental effect on the outcome of pulpectomies.[4,5] Moreover, NaOCl has low ability to eliminate *Enterococcus faecalis*.[6] A sequence of NaOCl and citric acid has been recommended in this regard, since citric acid has appropriate effect on SL removal.[4,6,7]

Studies that have examined the bacterial community of infected root canals of primary teeth before and after chemomechanical preparation (CP) are scarce in the literature.[8-10] These studies show a reduction in microorganisms, however, unlike the present study, they did not associate the performance of pulpectomy with the presence of microorganisms before and after CP, especially after long-term monitoring. Therefore, the analysis of this long-term correlation becomes relevant.

Thus, the aim was to describe the presence of total microorganisms and *Enterococcus faecalis* in primary root canals before and after use a chemomechanical protocol for SL removal. In addition, perform long-term follow-up of these pulpectomies.

CASE REPORTS

Pulpectomies performed in primary maxillary incisors from three preschool children (3.66±0.58 years old) that attended the Pediatric Dental Clinic of the School of Dentistry at the Universidade Federal do Rio de Janeiro (UFRJ) were reported. After completing the Term of Free and Informed Consent, their medical histories were investigated and revealed no congenital or systemic health concerns. The patients had not undergone oral and/or systemic antibiotic therapy for at least three months prior to microbiological sample collection.[11] The baseline characteristics of the patients and tooth elements are described in Table 1.

Two teeth from two patients (Pa1 and Pa2) presented necrosis with the presence of fistula and periapical lesions. Thus, pulpectomy was performed during two visits. The third patient (Pa3) presented an element diagnosed with irreversible pulpal inflammation and the pulpectomy was performed in one appointment. Coronary restoration was performed with composite resin after root canal obturation.

Two operators performed the pulpectomies based on the protocol proposed by Barcelos et al.[4], with smear layer (SL) removal from primary teeth. The protocol includes manual instrumentation and irrigation with 2.5% sodium hypochlorite followed by 10 ml of 6% citric acid to SL removal and final irrigation with 10 ml of 0.9% saline solution.

To obtain the microbiological samples, the teeth were isolated from saliva contact with a rubber dam after local anaesthesia. A field antisepsis was performed after the teeth were isolated, with 2% chlorhexidine digluconate twice for 1 minute each. Samples were obtained using sterile absorbent paper cones, at the following times (C): C1 – before accessing the pulp chamber, a cone was wiped for 10 seconds on the dental crown. The cone was immediately inserted into a sterilized tube containing thioglycolate (Difco, Sparks, USA); C2 – immediately after accessing the pulp chamber with diamond bur mounted on a high-speed hand piece, a sample was collected rubbing the paper cone perpendicularly to the coronary opening for 10s. Subsequently, the cone was inserted into a sterilized tube also containing thioglycolate; C3 – with the completion of access before the introduction of the first file, a third cone was inserted into the root canal, and left for 60 seconds. It was then inserted into an eppendorf containing 450 µl of 0.9% saline solution; and C4 – after the chemomechanical preparation, the last cone was inserted into the canal for 60 seconds. Then, this cone was inserted into another eppendorf also containing 450 µl of 0.9% saline solution. All samples were collected with absorbent number 60 paper cones inserted up to the working length in C3 and C4. The samples were collected in duplicate.

At the end of the clinical procedures, the cones were immediately taken to the Multidisciplinary Laboratory of Dental Research at UFRJ. Tubes containing paper cones embedded in thioglycolate (C1 and C2) were incubated aerobically for 14 days at 37°C. The aim of this incubation was to confirm the absence of bacterial colonies, for sterility control.

The contents of eppendorfs with samples from C3 and C4 were homogenized in a vortex mixer for 30 seconds. Aliquots (50 µl) of the suspension collected at C3 and C4, as well as their serial dilutions (up to 10^{-3}) were seeded in duplicate in appropriate culture media: BHI (Difco, Sparks, USA) for total microorganisms and Enterococcosel Agar (Difco, Sparks, USA) for *Enterococcus faecalis*. The plates were incubated anaerobically for 48 hours at 37°C. The results were expressed as colony forming units (CFU)/mL.

Samples collected from Pa1 and Pa3 demonstrated complete elimination of all microorganisms after the chemomechanical preparation. There was no growth of *E. faecalis* from any of the samples collected before or after the CP. The material collected from Pa2 showed no growth of total microorganisms or *E. faecalis* in any of the samples (Table 2).

The patients were followed-up to evaluate the clinical and radiographic success of the pulpectomies performed. Patient Pa1 did not attend the root canal filling appointment and thus follow-up of the tooth was not possible. Pa2 had been under follow-up for 29 months, and the pulpectomy could be considered successful, since the tooth exfoliated naturally, and the permanent tooth did not show any sequels (Figure 1). Pa3 had been under follow-up for 17 months, and the pulpectomy could be considered successful since there was not pain, gingival abscess, fistula or edema, and any periapical radiolucency (Figures 2).

***Table 1**: Baseline characteristics of patients (Pa) and their teeth.*

	Pa1	Pa2	Pa3
Gender	Female	Male	Male
Age	04	04	03
Tooth	61	52	62
Cause of pulp pathology	Trauma	Trauma	Dental caries
Pulpal diagnosis	Pulp necrosis	Pulp necrosis	Irreversible pulpitis
Clinical aspects	Oblique enamel fracture	Concussion	Deep caries on all faces
Clinical signs and symptoms	Absence of clinical signs and symptoms	Presence of fistula between tooth 51 and 52 and absence of pulp tissue after root canal access	Pain
Radiographic changes	Presence of periapical lesion	No radiographic changes	Coronary destruction with pulp involvement and small external root resorption

***Table 2**: Average number of microorganisms collected at different times, before (C3) and immediately after the chemomechanical preparation (C4).*

	Pa1		Pa2		Pa3	
Collect	**C3**	**C4**	**C3**	**C4**	**C3**	**C4**
Total Microorganisms (CFU/mL)	9900	ND	ND	ND	60	ND
Enterococcus faecalis (CFU/mL)	ND	ND	ND	ND	ND	ND

Note: Pa – patient. ND – not detected.

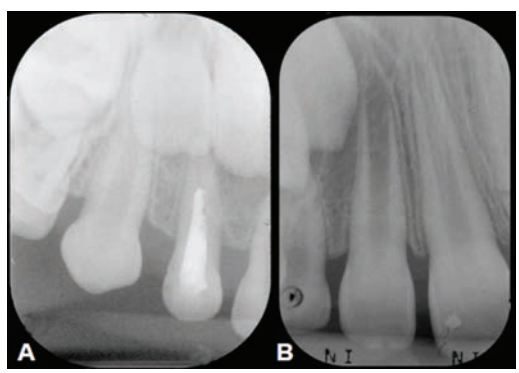

***Figure 1**: Radiographic performance of Pa2. A) Radiography performed immediately after root canal obturation and coronary restoration of primary maxillary right lateral incisor. B) After 29 months of treatment of primary maxillary right lateral incisor radiograph monitoring of the eruption of permanent maxillary right lateral incisor.*

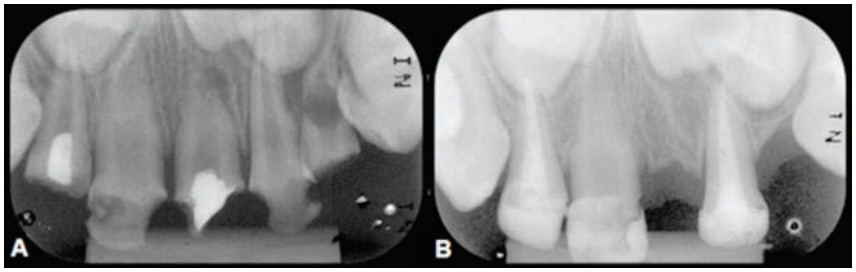

***Figure 2**: Radiographic performance of Pa3. A) Initial periapical radiograph evidencing primary maxillary left lateral incisor. B) Radiograph monitoring of primary maxillary left lateral incisor after 17 months of treatment.*

DISCUSSION

Irrigating solutions are used during pulpectomy in order to reduce intraradicular microorganisms and neutralize endotoxins, to perform vital or necrotic cell tissue dissolution, to lubricate the walls of the canal and to remove dentin particles.[12] None of the currently used irrigation solutions is ideal. Therefore, combinations of more than one solution are recommended.[4,7] In the present case reports case reports, the irrigation solutions used were 2.5% sodium hypochlorite followed by 6% citric acid. According to some authors,[8-10] sodium hypochlorite is efficient at decreasing the bacterial load when used during the chemomechanical preparation. However, this irrigant is not effective at removing the smear layer (SL), which has an important role in the success of pulpectomy.[4,5] The use of citric acid as an auxiliary irrigating solution is recommended since it removes the SL without altering normal dentinal structures,[13] being easily found in Brazil[4] and abroad.[13]

Our results showed 100% removal of bacteria from the root canals. This result may be unlikely to happen. However, we emphasize that the technique of microbial detection by bacterial colony counting was used. Molecular techniques, such as PCR-DGGE, may be more sensitive and useful for evaluating the microbiota of primary root canals.[11]

Most prevalence studies and assessments of bacterial load before and after chemomechanical preparations have investigated teeth with pulp necrosis.[8-11,14,15] Only one study described the prevalence of microorganisms in teeth with irreversible pulp inflammation, demonstrating a statistically significant difference between the numbers of bacterial cells found in teeth with irreversible pulpitis compared to necrotic teeth.[14] We observed that the tooth diagnosed with pulp necrosis and a periapical lesion had a higher number of microorganisms than those with irreversible pulp inflammation.

In addition, with regard to the pulp condition, microorganisms were found both in the tooth with dental trauma and with caries. It is worth mentioning that a greater number of total microorganisms was found before the CP in the root canal of the tooth that had suffered dental trauma since the tooth in question had pulp necrosis, while the other one with caries presented irreversible pulp inflammation.[14] This observation has clinical implications, since pulp necrosis or irreversible pulp inflammation can be caused by trauma or dental caries, and both situations leads to pulpectomy.[1]

Comparison of the performance of pulpectomy carried out on primary teeth due to caries or trauma, is scarce and its results are controversial. Randomized controlled clinical studies have shown no difference in treatment performance[4,16]. However, a prospective university-based study reported a lower frequency of survival of teeth treated endodontically by caries compared to those treated by trauma[17], suggesting perhaps less bacterial involvement in these cases. Therefore, the failure to treat traumatized teeth has a positive association with the preoperative condition of the tooth, such as the presence of periapical injury[18], reinforcing the importance of the pulp condition regardless the reason for treatment.

Among the anaerobic microorganisms, the prevalence of Enterococcus spp. in primary teeth with pulp necrosis is 50%.[15] However, in the reported cases, *E. faecalis* was not found in two teeth classified as pulp necrosis. This fact can be explained by the findings of Fabris et al.[15] that reported *E. faecalis* only in cases of necrotic teeth due to caries which had pulp exposure to the buccal environment, differently than observed in our two cases in which the teeth were diagnosed as necrotic due to trauma without exposure to the buccal cavity.

Enterococcus faecalis and surface microorganisms did not grow in any of the Pa2 samples. This is consistent with other study findings,[19] as nine of the samples collected from root canals of permanent necrotic teeth were free from bacteria. Inflammatory periapical diseases may be associated with two basic conditions: pulp necrosis associated with a rich and mixed microbiota, and aseptic traumatic necrosis, where rupture or lesion of the periodontal-pulpal vascular bundle induces aseptic pulpal necrosis.[20]

Good clinical and radiographic results of pulpectomy with SL removal with citric acid have already been reported[4,16].

Therefore, from the present case reports, the importance of using an irrigation sequence effective in elimination of microorganisms, favorable to treatment, is perceived. However, the present findings should be interpreted with caution due to the limitations inherent in this study model. The importance of carrying out more clinical research to assess the bacterial community present in root canals of primary teeth before and after chemical-mechanical preparation with removal of smear layer using citric acid is emphasized.

CONCLUSIONS

Microorganisms were present in two of the three root canals but *Enterococcus faecalis* was not detected in any sample. In cases where microorganisms were found, 100% elimination occurred after the applied protocol. Thus, we encourage the inclusion of substances that remove SL in the irrigation protocol, such as 6% citric acid, an effective and efficient solution, easily found in Brazil and abroad.

REFERENCES

1. American Academy of Pediatric Dentistry. Pulp therapy for primary and immature permanent teeth. The Reference Manual of Pediatric Dentistry. Chicago, Ill.: American Academy of Pediatric Dentistry 2020:384-92.

2. Smaïl-Faugeron V, Glenny AM, Courson F, Durieux P, Muller-Bolla M, Fron Chabouis H. Pulp treatment for extensive decay in primary teeth. Cochrane Database Syst Rev. 2018 May 31;5:1-430.

3. Pitoni CM, Figueiredo MC, Araújo FB, Souza MA. Ethylenediaminetetraacetic acid and citric acid solutions for smear layer removal in primary tooth root canals. J Dent Child. 2011;78 (3):131-7.

4. Barcelos R, Tannure PN, Gleiser R, Luiz RR, Primo LG. The influence of smear layer removal on primary tooth pulpectomy outcome: a 24-month, double-blind, randomized, and controlled clinical trial evaluation. Int J Paediatr Dent. 2012;22(5):369-81.

5. Pintor AVB, Santos MRM dos, Ferreira DM, Barcelos R, Primo LG, Maia LC. Does smear layer removal influence root canal therapy outcome? A systematic review. J Clin Pediatr Dent. 2016;40(1):1-7.

6. Estrela C, Silva JA, Alencar AHG de, Leles CR, Decurcio DA. Efficacy of sodium hypochlorite and chlorhexidine against Enterococcus faecalis – A systematic review. J Appl Oral Sci. 2008;16(6):364-8.

7. Götze GR, Cunha CBCS, Primo LSSG, Maia LC. Effect of the sodium hypochlorite and citric acid association on smear layer removal of primary molars. Braz Oral Res. 2005;19(4):261-6.

8. Valdez-Gonzalez C, Mendez-Gonzalez V, Torre-Delgadillo G, Flores-Reyes H, Gaitan-Fonseca C, Pozos-Guillen AJ. Effectiveness of oxidative potential water as an irrigant in pulpectomized primary teeth. J Clin Pediatr Dent. 2012; 37(1):31-5.

9. Tulsani SG, Chikkanarasaiah N, Bethur S. An in vivo comparison of antimicrobial efficacy of sodium hypochlorite and biopure MTADTM against Enterococcus faecalis in primary teeth: A qPCR study. J Clin Pediatr Dent. 2014;39(1):30-4.

10. Farhin K, Viral PM, Thejokrishna P, Sajjad M. Reduction in bacterial loading using MTAD as an irrigant in pulpectomized primary teeth. J Clin Pediatr Dent. 2015;39(2):100-4.

11. de Paula VA, de Carvalho Ferreira D, Cavalcante FS, do Carmo FL, Rosado AS, Primo LG, dos Santos KR. Clinical signs and bacterial communities of deciduous necrotic root canals detected by PCR-DGGE analysis: Research association. Arch Oral Biol. 2014;59:848-54.

12. Schäfer E. Irrigation of the root canal. Endod Topics 2007;1(1):11-27.

13. Hariharan VS, Nandlal B, Srilatha KT. Efficacy of various root canal irrigants on removal of smear layer in the primary root canals after hand instrumentation: a scanning electron microscopy study. J Indian Soc Pedod Prev Dent. 2010 Oct-Dec;28(4):271-7.

14. Ruviére DB, Leonardo MR, da Silva LA, Ito IY, Nelson-Filho P. Assessment of the microbiota in root canals of human primary teeth by checkerboard DNA-DNA hybridization. J Dent Child. 2007;74(2):118-23.

15. Fabris AS, Nakano V, Avila-Campos MJ. Bacteriological analysis of necrotic pulp and fistulae in primary teeth. J Appl Oral Sci. 2014;22(2):118-24.

16. Cassol DV, Duarte ML, Pintor AVB, Barcelos R, Primo LG. Iodoform Vs calcium hydroxide/zinc oxide based pastes: 12-month findings of a randomized controlled trial. Braz Oral Res. 2019;33

17. Brustolin JP, Mariath AA, Ardenghi TM, Casagrande L. Survival and Factors Associated with Failure of Pulpectomies Performed in Primary Teeth by Dental Students. Braz Dent J. 2017 Jan-Feb;28(1):121-128.

18. Tannure PN, Fidalgo TK, Barcelos R, Primo LG, Maia LC. Analysis of root canal treated primary incisor after trauma: two year outcomes. J Clin Pediatr Dent. 2012 Spring;36(3):257-62.

19. Gomes BPFA, Lilley JD, Drucker DB. Associations of endodontic symptoms and signs with particular combinations of specific bacteria. Int Endod J. 1996;29:69-75.

20. Consolaro A, Consolaro RB. Orthodontic movement of endodontically treated teeth. Dental Press J Orthod. 2013;18(4):2-7.