# IMPACT OF MESIODENS MANAGEMENT ON THE ORAL HEALTH-RELATED QUALITY OF LIFE OF A CHILD: A CASE REPORT

Magali Leal de **Melo**[1,2*], Marcelle Maciel Fernandes de **Azevedo**[1,2], Isabela **Floriano**[2,3], Patricia Nivoloni **Tannure**[1,4], Aline Borburema **Neves**[1], José Carlos Petorossi **Imparato**[2,5]

[1]School of Dentistry, Faculdade São Leopoldo Mandic – SLMANDIC, Rio de Janeiro, Rio de Janeiro, Brazil.
[2]School of Dentistry, Faculdade São Leopoldo Mandic – SLMANDIC, Campinas, São Paulo, Brazil.
[3]Department of Orthodontics and Pediatric Dentistry, Centro Universitário Uninovafapi, Teresina, Piauí, Brazil.
[4]School of Dentistry, Universidade Veiga de Almeida - UVA, Rio de Janeiro, Rio de Janeiro, Brazil.
[5]Department of Orthodontics and Pediatric Dentistry, Universidade de São Paulo – USP, São Paulo, São Paulo, Brazil.

**Palavras-chave:** Odontopediatria. Dente Supranumerário. Bullying. Qualidade de Vida. Felicidade.

**RESUMO**

**Introdução**: Mesiodente é um dente supranumerário presente na maxila anterior. Crianças com alterações nos dentes que podem afetar suas características faciais podem sofrer bullying e dificuldades de interação social. **Objetivo**: Relatar um caso clínico de tratamento em um paciente com mesiodente. Adicionalmente, correlacionar o tratamento do mesiodente ao impacto na qualidade de vida e felicidade por meio do *Child Perceptions Questionnaire* ($CPQ_{8-10}$) e da Escala Subjetiva de Felicidade (ESF). **Relato do caso**: Paciente de 7 anos tinha como queixa um dente entre os incisivos centrais superiores e diagnóstico de mesiodente. O paciente relatou sofrer *bullying* por conta disso. Na consulta inicial foram aplicados o $CPQ_{8-10}$ e o ESF. O tratamento realizado foi exodontia do mesiodente e acompanhamento. Quatro meses após a exodontia houve aproximação espontânea dos dentes 11 e 21, sem a necessidade de intervenção ortodôntica. Os resultados iniciais (22 pontos no $CPQ_{8-10}$ e média 2,5 no ESF) mostraram impacto negativo na qualidade de vida. Seis meses após a consulta inicial os questionários foram reaplicados e uma melhora nos resultados foi percebida (7 pontos no $CPQ_{8-10}$ e média 5,25 no SHS). **Conclusão**: O diagnóstico correto e o melhor momento para o tratamento foram fundamentais para prevenir problemas oclusais. Além disso, o tratamento melhorou significativamente a qualidade de vida da criança e a felicidade percebida.

**Keywords**: Pediatric Dentistry. Tooth Supernumerary. Bullying. Quality of Life. Happiness.

**ABSTRACT**

**Introduction**: Mesiodens is a supernumerary tooth present in the anterior maxilla. Children with teeth alterations that could affect their facial features may experience harassment and teasing, leading to difficulties in social interaction. **Objective**: To report a clinical case of treatment in a pediatric patient with mesiodens. Additionally, we aimed to correlate the mesiodens to the quality of life and happiness through the Child Perceptions Questionnaire ($CPQ_{8-10}$) and the Subjective Happiness Scale (SHS). **Case report**: A 7-year-old patient complaining about a tooth between the upper central incisors and esthetical problems his tooth caused, according to his grandmother. In the initial session, the CPQ8-10 and the SHS were applied. The treatment performed was mesiodent extraction and follow-up. Four months after extraction, teeth 11 and 21 spontaneously repositioned, without the need for orthodontic intervention. The initial results (22 points in CPQ8-10 and mean 2.5 in the ESF) showed a negative impact on quality of life. Six months after the initial session, the questionnaires were reapplied and an improvement in the results was observed (7 points in CPQ8-10 and mean 5.25 in SHS). **Conclusion**: The correct diagnosis and the best moment for treatment were keys for preventing occlusal problems in a patient with mesiodens. Additionally, mesiodens treatment significantly improved the child's quality of life and perceived happiness.

Submitted: July 29, 2021
Modification: December 02, 2021
Accepted: December 03, 2021

***Correspondence to**:
Magali Leal de Melo
Address: Rua Santana, 151, Centro, Mariana, MG, Brazil. Zip Code: 35420-000
Telephone number: +55 (31) 3557-1520 / +55 (31) 9 9961-1702
E-mail: magalileal@yahoo.com

## INTRODUCTION

Supernumerary is the presence of an anormal number of teeth compared to the normal dentition, and mesiodens is a supernumerary tooth present in the anterior maxilla. Almost 90% of supernumerary teeth are mesiodens, which erupt in the middle of upper central incisors[1]. The etiology of supernumerary teeth remains unknown and the prevalence ranges from 0.8% to 3.7% in different populations around the world.[4-7] In Brazil, the occurrence of supernumerary teeth is 3.8% in men, 2.0% in women, and 3.3% occur in permanent dentition and 0.7% in primary dentition. The incidence in the maxilla is 8 times higher than in the mandible.[1]

Erupted mesiodens are aesthetically unpleasant and can cause crowding or be positioned in the place of a normal tooth.[5] Studies have shown a significant relationship between bullying and the facial appearance.[6,7] Children with teeth alterations that could affect their facial features may experience harassment and teasing, leading to difficulties in social interaction.[8,9]

The Child Perceptions Questionnaire ($CPQ_{8-10}$) is an effective and efficient tool for health professionals to assess the impact in children's quality of life.[10] In addition, the Subjective Happiness Scale (SHS)[11] can also be used to demonstrate the relationship between severe malocclusion and the patient's happiness. Patients with malocclusion could perceive themselves as emotionally and socially less happy than those with esthetically normal teeth.[12] However, to date, no study has assessed the impact of a mesiodens tooth on the quality of life and happiness of pediatric patients.

Therefore, the objective of this study was to report a clinical case of treatment in a pediatric patient with mesiodens. Additionally, we aimed to correlate the mesiodens to the quality of life and happiness through the Child Perceptions Questionnaire ($CPQ_{8-10}$) and the Subjective Happiness Scale (SHS).

## CASE REPORT

This case report was approved by the Local Ethics Committee of São Leopoldo Mandic Faculty (protocol number 2.333.431). Patient's assent and guardian's consent were requested and approved.

A seven-year-old boy was attended in the Pediatric Dentistry Specialization Clinic of the Faculty São Leopoldo Mandic in Rio de Janeiro in April 2018 complaining about a tooth between the upper central incisors and esthetical problems his tooth caused, according to his grandmother. As a main complaint, the patient reported shyness due to this abnormal tooth and suffered bullying at school when his classmates called him "mountain tooth".

In the anamnesis evaluation, the patient did not have any history of syndromes, systemic diseases, or familiar history of the presence of supernumerary teeth or any other tooth abnormality. In the intraoral clinical examination, the patient was in the mixed dentition phase and in the Broadbent phenomenon (ugly duckling stage) (Figure 1A and B). The mesiodens tooth was diagnosed between the upper central incisors in the anterior region of the maxilla (Figure 1C, D and E).

During the initial consultation, the CPQ was applied to assess the oral health-related quality of life and the SHS to evaluate happiness. Both questionnaires were used to evaluate the bullying. The initial results (22 points on $CPQ_{8-10}$ and 2.5 on SHS) showed the impact on quality of life. The treatment plan was based on the correct diagnosis, evaluating the questionnaires, the patient's age, treatment risks and included the surgical removal of the central mesiodens tooth under local anesthesia (Figure 2A) and after that, to follow-up the case.

The other supernumerary tooth was maintained due to the difficult surgical access and major trauma that would be involved in the surgery. This decision was made considering the opinion of the patient's guardian, the patient himself and the surgery team. Additionally, this supernumerary tooth was not interfering with anything involved with the permanent central incisors development and was scheduled for follow-up.

Four months after the tooth extraction, in the follow-up consultation, there was spontaneous approximation of teeth 11 and 21, without any orthodontic intervention (Figure 2B). In the six-month follow-up, after the initial appointment, the questionnaires were reapplied and an improvement in the results was noticed (7 points on $CPQ_{8-10}$ and 5.25 on SHS).

Table 1 shows the results of the questionnaires applied before and after surgery. For the $CPQ_{8-10}$, the total score decreased 15 points after surgery, the oral symptoms score went from 2 to 3, and the functional limitation score decreased from 2 to 0. For the emotional well-being score, the reduction was from 9 to 0 and the social well-being decreased from 9 to 4 points. For the SHS, the average score before the surgery was 2.5, indicating the patient's unhappiness, and after the treatment, the score increased to 5.25, indicating a significant improvement in the patient's happiness.

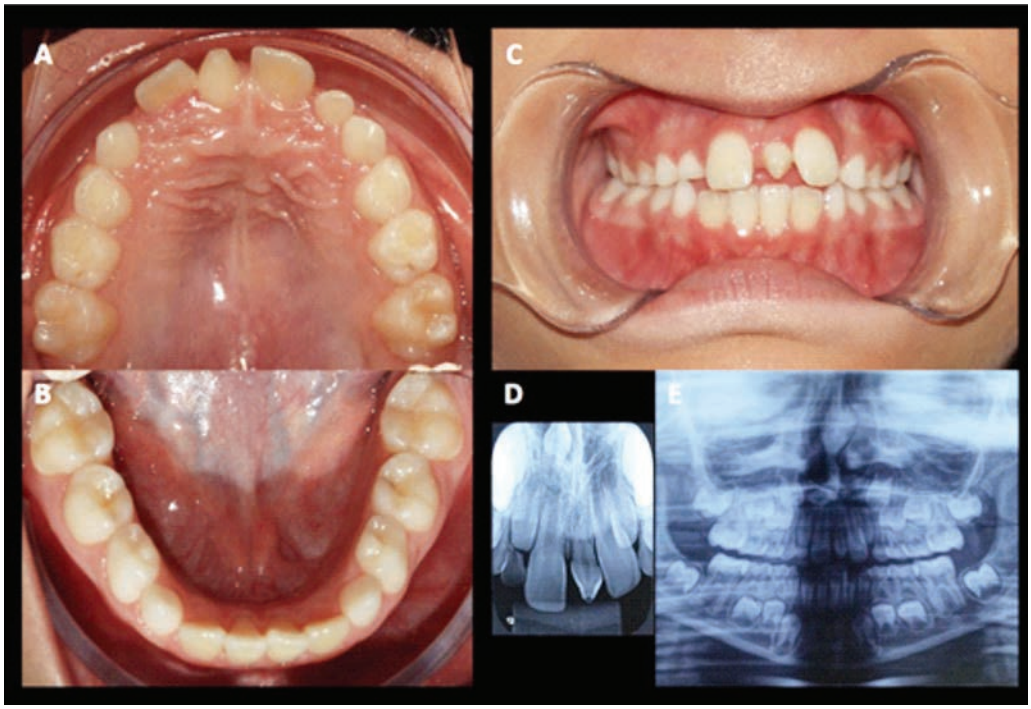


***Figure 1**: A) Patient's upper arch. B) Patient's lower arch arch. C) The mesiodens in anterior superior arch. D) Anterior superior periapical radiograph. E) Panoramic radiograph.*




***Figure 2**: A) Patient's upper arch after the mesiodens removal. B) Patient's after 6 months of surgery and the self-positioned incisors with any orthodontic intervention.*

***Table 1**: Quality of life assessment related to oral health with Child Perceptions Questionnaire - CPQ8-10.*

| CPQ8-10 QUESTIONS | SCORE BEFORE | SCORE AFTER |
|---|---|---|
| Oral symptoms 5 questions | 2 | 3 |
| Functional limitation 5 questions | 2 | 0 |
| Emotional well-being 5 questions | 9 | 0 |
| Social welfare 10 questions | 9 | 4 |
| **TOTAL** | **22** | **7** |

# DISCUSSION

This report aimed to describe the treatment of mesiodens in a 7-year-old patient. Additionally, it aimed to correlate the treatment to the quality of life and patient happiness. As a point, the supernumerary tooth is detected in radiographic examination while the mesiodens is clinically visible and easy to diagnose.[13-16] Thus, in this case report, the mesiodens diagnosis was made clinically. However, a second supernumerary tooth was found in the nasal floor through the panoramic and periapical radiographs.

It is important to note that the presence of supernumerary teeth can cause dental crowding, permanent teeth impaction, delayed or ectopic eruption, dental rotation, diastemas, resorption of adjacent teeth, eruption failures with dental retention, tooth displacement, impaired occlusion, and can compromise alveolar bone grafts and implant placement that can lead to other pathologies.[2] The clinical implications of supernumerary teeth are very important, and their early diagnosis can alert the dentist to the risk of associated anomalies in the same patient or in family members, making early intervention possible.[17] Each case must be evaluated individually to decide the better treatment option and whether to adopt an immediate or late surgical approach, for that, an accurate diagnosis is essential for decision making.[14] As in this patient, the mesiodens caused a spacing between the upper central incisors, and the proposed treatment consisted of extraction. The other supernumerary tooth was not removed at that time.

Several factors may determine the early or late intervention. The first factor is the patient's age and ability to tolerate surgical treatment.[18] The second factor is the stage of dental development and the mesiodens proximity to the permanent incisor; the risk of surgical trauma and the amount of bone removal must be considered.[19] In addition, the psychological impact of a mesiodens between the central incisors must be considered, as the esthetics plays an important role in social interactions and psychological well-being. Further, the appearance of the mouth and smile has a significant impact on judgments regarding facial attraction.[12,20]

In the present case report, to evaluate the quality of life and its association with happiness, the $CPQ_{8-10}$ was used in association with the SHS. The $CPQ_{8-10}$ consists of 25 items, comprising four subscales: oral symptoms, functional limitations, emotional well-being, and social well-being. Items are rated on a 5-point Likert scale, ranging from 0 to 4. The scores' sum can range from 0 to 100, with zero meaning no impact of the oral condition on the child's quality of life and 100 being the maximum impact. The instrument also contains two patient identification items (gender and age) and two general items about the child's oral health and how much oral and oral-facial changes affect their general well-being.[21] In this pediatric patient, the $CPQ_{8-10}$'s initial results and the decreasing of 15 points six months after the surgery (7 points in the second application of the CPQ) suggests a change in the quality of life, mainly in the emotional well-being score and social well-being, both with the reduction from 9 to 0 and from 9 to 4 points, respectively.

The oral symptoms domain is especially related to pain and has increased. Although it was a very slight increase, we believe that once the discomfort generated by the mesiodens is solved, the patient can turn his attention to other oral problems. The social well-being domain includes questions that associate teeth with self-perception, daily school activities and bullying. Despite not having received a zero score, after the treatment, we observed improvement in this domain, possibly related to an improvement in smile esthetics. However, it is worth noting that self-perception and bullying are processes and the impact on social well-being will most likely increase over time.

The SHS measures positive and negative aspects, assessing affective and cognitive factors with few items.[22] Comparing the initial and results in terms of happiness in this case report, it was possible to note that there was an increase in the patient's happiness, which was associated with the mesiodens's removal, since the score increased from 2.5 average to 5.25 average on the SHS. It is important to point out that an unpleasant facial appearance can stigmatize a person, hinder professional achievements, encourage negative stereotypes, and negatively affect self-esteem.[12]

## CONCLUSION

The correct diagnosis and the best moment for treatment were keys for preventing occlusal problems in a patient with mesiodens. Additionally, mesiodens treatment significantly improved the child's quality of life and perceived happiness.

## REFERENCES

1. Lana TS, Lancia M, Silva Filho OG, Garib DG, Ozawa. Prevalence of mesiodens in orthodontic patients with deciduous and mixed dentition and its association other dental anomalies. Dental Press J Orthod. 2013;18(6);93-99. doi: 10.1590/S2176-94512013000600014.
2. Correia FG, Ferreira FV, Friedrich LR, Pistóia AD, Pistóia GD. Prevalência de dentes supranumerários: estudo retrospectivo. Int J Dent, Recife. 2009;8(1):11-15.
3. Mukhopadhyay S. Mesiodens: a clinical and radiographic study in children. J Indian Soc Pedod Prev Dent. 2011;29(1):34-8. doi: 10.4103/0970-4388.79928.
4. Nunes KM, Mederios MV, Ceretta LB, Simões PW, Azambuja FG, Sônego FGF, *et al*. Dente Supranumerário: Revisão Bibliográfica e Relato de caso. Rev Odontol Univ Cid São Paulo. 2015;27(1):72-81. doi: 10.26843/ro_unicid.v27i1.247.
5. Berthold TB, Benemann E. Anomalia de número de dentes: Anodontia e Supranumerário. Rev Odonto Cienc, 1996;11(22);101-109.
6. Al-Omari IK, Al-Bitar ZB, Sonbol HN, Al-Ahmad HT, Cunningham SJ, Al-Omiri M. Impact of bullying due to dentofacial features on oral health-related quality of life. Am J Orthod Dentofacial Orthop. 2014 Dec; 146:734-739. doi: 10.1016/j.ajodo.2014.08.011.
7. Al-Bitar ZB, Al-Omari IK, Sonbol HN, Al-ahmad HT, Cunningham SJ. Bullying among Jordanian scoolchildren, its effects on school performance, and the contribution of general physical and dentofacial features. Am J Orthod Dentofacial Orthop. 2013;144:872-878. doi: 10.1016/j.ajodo.2013.08.016.
8. Seehra J, Newton JT, DiBiase At. Interceptive orthodontic treatment in bullied adolescents and its impact on self-esteem and oral-health-related quality of life. European Journal of Orthodontics. 2013; 35:615-621. doi: 10.1093/ejo/cjs051.
9. Serra-Negra JM, Paiva SM, Bendo CB, Fulgêncio LB, Lage CF, Corrêa-Faria P, *et al*. Verbal school bullying and life satisfaction among Brazilian adolescents: Profiles of the aggressor and the victim. Comprehensive Psychiatry. 2015; 57:132-139. doi: 10.1016/j.comppsych.2014.11.004.
10. Barbosa TS, Vicentin MDS, Gavião MBD. *Qualidade de vida e saúde bucal em crianças: Parte 1: Versão brasileira do* child perceptions questionnaire 8-10. Ciência & Saúde Coletiva. 2011; 16(10):4077-4085. Available from: http://www.cienciaesaudecoletiva.com.br/artigos/qualidade-de-vida-e-saude-bucal-em-criancas-parte-i-versao-brasileira-do-child-perceptions-questionnaire-810/3017?id=3017.
11. Rodrigues A, Silva JA. *O papel das características sociodemográficas na felicidade*. Psico-USF. 2010;15(1);113-123. doi: 10.1590/S1413-82712010000100012.
12. Da Rosa GN, Del Fabro JPD, Tomazoni F, Tuchtenhagen S, Alves LSA, Ardenghi TM. Association of maloclusion, happiness, and oral health: related quality of life (OHRQoL) in schoolchildren. Journal of Public Health Dentistry. 2016; 76:85. doi: doi.org/10.1111/jphd.12111.
13. Cal Neto JOAP, Cunha DL, Miguel JAM. *Diastemas Interincisais superiores associados a dente supranumerários: Considerações Clínicas e Relato de um caso*. J Bras Ortodon Ortop Facial. 2002;7(39);239-244.
14. Gunduz K, Çelenk P, Zengin Z, Sumer P. Mesiodens: a radiographic study in children. Journal of Oral Science. 2008;50(3):287-291. doi: 10.2334/josnusd.50.287.
15. Azenha MR, Zorzettto DLG, Marzola C, Moura LA, Handem RH. *Abordagem cirúrgica de dente supra-numerário (mesiodens) na região palatina: caso clínico*. Rev Port de Estomatol Cir Maxilofac. 2007;48(1):37-41. doi: 10.1016/S1646-2890(07)70059-6.
16. Ersin NK, Candan U, Alpoz AR, Akay C. Mesiodens in primary, mixed and permanent dentitions: a clinical and radiographic study. J Clin Pediatr. 2004;28(4);295-298. doi: 10.17796/jcpd.28.4.0k2w2734hp76x541.
17. Garib DG, Alencar BM, Ferreira FV, Ozawa TO. *Anomalias dentárias associadas: o ortodontista decodificando a genética que rege os distúrbios de desenvolvimento dentário*. Dental Press J. Orthod. 2010;15(2):138-157. doi: 10.1590/S2176-94512010000200017.
18. Assed S, Borsatto MC, de Freitas AC. Anomalias dentárias. In: Odontopediatria: bases científicas para a prática clínica. São Paulo: Artes Médicas; 2005.
19. Rocha SCC, Vidigal BL, Pereira AC, Fonseca MS, Manzi FR. *Etiologia, diagnóstico do mesiodens: Relato de caso Clínico Atípico*. Arquivo Brasileiro de Odontologia. 2012;8(2):49-54. Available from: http://periodicos.pucminas.br/index.php/Arquivobrasileirodontologia/article/view/5742.
20. Ellakany P, Fouda SM, Alghamdi M, Bakhurji E. Factors affecting dental self-confidence and satisfaction with dental appearance among adolescents in Saudi Arabia: a cross sectional study. BMC Oral Health. 2021;21:149-56. doi: 10.1186/s12903-021-01509-z.
21. Martins M, Ferreira FM, Oliveira AC, Paiva SM, Vale MP, Allison P J, *et al*. Preliminary validation of the Brazilian version of the Child Perceptions Questionnaire 8-10. EJPD 2009;10(3):135-40.
22. Lyubomirsky S, Lepper H. A measure of subjective happiness: preliminary reliability and construct validation. Social Indicators Research . 1999; 46, (2); 137-155. doi: 10.1023/A:1006824100041.