MAPPING OF SUPERNUMERARY ELEMENTS IN PATIENTS SEEKING ORTHODONTIC TREATMENT

Bruna Caroline Tomé **Barreto**[1*], Ingrid Cristina Pinto Da **Costa**[2], Margareth Maria Gomes De **Souza**[1], Sandra Regina **Torres**[3], Ana Maria **Bolognese**[1]

[1] Department of Pediatric Dentistry and Orthodontics, Rio de Janeiro, Rio de Janeiro, Brazil.
[2] Department of Oral Pathology and Diagnosis, Rio de Janeiro, Rio de Janeiro, Brazil.

Palavras-chave: Epidemiologia. Anormalidades dentárias. Dente supranumerário.

RESUMO

Introdução: Alterações de dimensão, número e forma são anomalias dentárias comumente observadas. **Objetivo**: O objetivo foi mapear a frequência de dentes supranumerários na população estudada, sua localização preferida e os tipos mais prevalentes. Além disso, avaliar a interferência que os dentes supranumerários podem causar na erupção ectópica da série dental normal. **Métodos**: A pesquisa possui desenho retrospectivo observacional. A coleta de dados foi realizada pela avaliação de prontuários odontológicos dos pacientes atendidos em uma clínica ortodôntica. Foram analisados radiografias, fotografias e modelos de gesso dental dos pacientes e as informações foram registradas em arquivos de protocolo do estudo. A coleta de dados foi realizada por uma estudante de graduação e uma da pós-graduação, previamente calibradas. A coleta durou dois meses e foram avaliados registros de 1984 a 2019. Os dados foram tratados no programa Microsoft Office Excel (version 2016) com análise descritiva dos dados. **Resultados**: Dos 920 prontuários analisados, 2,7% apresentavam pelo menos um dente supranumerário, com localização preferida na área superior anterior e na área parapremolar mandibular. O tipo mais prevalente foi o dente suplementar, com orientação de erupção normal e localização alveolar normal. **Conclusão**: Os dentes supranumerários da população estudada neste estudo mostraram pouca interferência na erupção ectópica da série dental normal. A maioria dos dentes supranumerários estava em posição de impactação. E, aproximadamente um terço dos dentes supranumerários apresentaram desvios de erupção.

Keywords: Epidemiology. Tooth Abnormalities. Tooth Supernumerary.

ABSTRACT

Introduction: Dimension, number and shape alterations are frequently observed dental anomalies. **Objective**: The aim of this study was to map the frequency, the preferred location and the most prevalent types of supernumerary teeth, in the studied population. In addition, to assess the interference that supernumerary teeth may cause in the ectopic eruption of the normal dental series teeth. **Methods**: This is an observational retrospective study. Data collection was performed by evaluation of dental records of patients treated in an orthodontic clinic. Patients' radiographs, photographs and gypsum dental models were analyzed and data recorded in protocol files, by previously trained undergraduate and postgraduate students. Records from 1984 to 2019 were evaluated, and evaluation lasted two months. Data were stored in Microsoft Office Excel (version 2016) for descriptive analysis. **Results**: From the 920 patients' records analyzed, 2.7% presented at least one supernumerary tooth, with preferred location on the anterior maxillary area and mandibular parapremolar area. The most prevalent type was the supplemental tooth, with normal eruption orientation and normal alveolar location. **Conclusion**: The supernumerary teeth of the studied population showed little interference in the ectopic eruption of the normal dental series. Most of the supernumerary teeth were impacted, and, approximately one third of the supernumerary teeth showed deviated eruptions.

Submitted: May 31, 2020
Modification: July 30, 2020
Accepted: August 22, 2020

***Correspondence to:**
Bruna Caroline Tomé Barreto
Address: R. Prof. Rodolpho Paulo Rocco, 325 - Cidade Universitária da Universidade Federal do Rio de Janeiro, Rio de Janeiro - RJ, 21941-617
Telephone number: +55 (21) 3938-2017
E-mail: bruna_barreto_@hotmail.com

INTRODUCTION

The dental eruption pathway begins in the germ intraosseous position moving towards the oral cavity, until tooth eruption is completed. Any deviation from the normal course of the tooth eruption into an atypical location is considered an ectopic eruption.[1] This pathological process of eruption may present multifactorial etiologies, being associated with genetic, local or systemic factors.[2,3] However, the impact of these factors is not consistently explained in the literature.

Several dental development anomalies described in the literature may be observed in clinical practice. Such deviations from normality may be related to the size, shape, number and the eruption pathway of teeth.[4] The identification of these anomalies is crucial for the correct diagnosis and, consequently, appropriate planning and treatment.

Supernumerary tooth, or accessory tooth,[5] constitutes a development disorder defined by the presence of one or more dental teeth beyond the number considered normal. The deciduous dentition consists of 20 teeth and the permanent dentition of 32 teeth.[6-9] Supernumerary teeth do not usually present the same anatomical features as teeth of normal series. They may be single or multiple, and may develop in the mandible, maxilla or on both arches. They are asymptomatic, in most of the cases, but may cause pain if related to pericoronitis.[10]

The recognition of the anatomical shape and the location and orientation of supernumerary teeth are important to determine the required clinical intervention. Supernumerary teeth may present different shapes: conical (small, conoid); tuberculate (small, with multiple cusps and rudimentary root); supplemental (similar to normal series) and odontoma (grouping of irregular-shaped teeth).[5,6,11-14] The location of supernumerary teeth may be defined as mesiodens (when located between the central maxillary incisors), parapremolars (when located in the premolars area), paramolars (when located in the molars area) and distomolars (when located distally to the molars teeth). Supernumerary teeth may also be rarely found in the maxillary sinus and nasal cavity.[12-14] As for the tooth orientation, the supernumerary teeth can be normal/vertical, oblique, inverted or transverse.[5,12,15]

The diagnosis of supernumerary teeth and their characteristics are obtained by clinical and radiographic means, mainly through panoramic radiograph, with complementary periapical radiographs.[11] The role of the orthodontist in the context of identification of these variations from normality is important. The aim of this study was to map the frequency, location and types of supernumerary teeth in the documentation of an orthodontic patient population. Another aim was to identify ectopic eruption of the normal dental series in the same population.

MATERIALS METHODS

The research has an observational retrospective design and was approved by the Research Ethics Committee of the Hospital Universitario Clementino Fraga Filho of the Federal University of Rio de Janeiro, under protocol 3.302.723. There was no need for sample calculation, as it was an epidemiological survey. The sample was selected from the analysis of orthodontic documentation requested for purposes of treatment and/or orthodontic monitoring, from the archives of the Orthodontics Clinic of the School of Dentistry, Federal University of Rio de Janeiro (UFRJ). The sample inclusion criteria was to be an orthodontic patient undergoing treatment or restraint at the Department of Pediatric Dentistry and Orthodontics, of the same school UFRJ, with complete orthodontic records and radiographs in good condition for analysis. Patients with syndromes, congenital deformities and systemic diseases, as well as incomplete orthodontic documentation, were not included.

After applying inclusion and exclusion criteria, dental records of 920 patients were selected and evaluated with the sole intention of locating patients with the presence of supernumerary elements. Data collect was carried out from orthodontic patients' records. Plaster models and photographs were inspected in order to detect erupted supernumerary teeth. However, imaging exams were fundamental for evaluation: panoramic and periapical radiographs or cone beam computed tomographies (CBCTs), depending on the availability. The oldest records had analogical radiographs, while the most recent ones had digital images.

Data collection was performed by two researchers (an undergraduate student – initials I.C.P.C. and a master's degree in orthodontics – initials B.C.T.C.), under the supervision of two experienced orthodontists (initials A.M.B. and M.M.G.S.). The researchers were initially trained by two experienced orthodontists (initials A.M.B. and M.M.G.S.). Then, data collection started in 30% of the sample and this investigation was repeated after 10-14 days of the initial data collection, to ensure that the reliability of the data was 100%. The collection lasted two months. Records from 1984 to 2019 that presented radiographs in good condition were evaluated. The data were stored in Microsoft Office Excel (version 2016) and the results were shown descriptively.

RESULTS

From the 920 patient's records, there were 25 records showing at least one supernumerary tooth, constituting 2.7% of the sample. No record was excluded. Mean age for the population was 12.5 (± 4.3) and 56% was male. The records from the included 25 orthodontic patients presented 41 supernumerary teeth, being 63.4% in the maxilla and 36.6% in the mandible. The normally oriented dental position was more prevalent, expressed by 68.3% of the cases, and the supplemental shape observed in 63.4% of the cases. (Table 1) The most common location were mesiodens (Figure 1) and parapremolar (Figure 2A), both found in 41.4% of the cases.

When the location was analyzed in relation to the correct axis of eruption, most of the sample was located in the center of the alveoli (26.8%) (Figure 3), and the other location were palatal (Figure 2B) and lingual (22% and 17%, respectively) (Figure 2C). Furthermore, 31.7% of the supernumerary teeth showed eruption deviations from the correct axis of the normal dental series (Figure 4), and 3 cases exhibited divergence of adjacent roots, no other case presented different type of change. Besides that, 9 (22%) of the supernumerary teeth could not have location classified along the long axis because they had only 2D images. Of these, only two caused an ectopic eruption (4.8%), and 29 teeth (70.7%) were impacted.

***Table 1**: Frequency of supernumerary dental anomalies in the studied population.*

		Total		Maxilla		Mandible	
		N=41	**%**	**N=26**	**63.4%**	**N=15**	**36.6%**
Eruption Pathway	Ectopic	N=2	4.8%	N=2	100%	N=0	0%
	Impacted	N=29	70.7%	N=16	39%	N=13	31.7%
Shape	Conical	9	22%	9	100%	0	0%
	Tuberculate	5	12.2%	3	60%	2	40%
	Supplemental	26	63.4%	13	50%	13	50%
	Odontoma	1	2.4%	1	100%	0	0%
Orientation	Normal	28	68.3%	16	57.1%	12	42.9%
	Oblique	8	19.5%	6	75%	2	25%
	Reverse	0	0%	0	0%	0	0%
	Transverse	5	12.2%	4	80%	1	20%
Location	Mesiodent	17	41.5%	17	100%	0	0%
	Distomolar	0	0%	0	0%	0	0%
	Parapremolar	17	41.5%	5	29.4%	12	70.6%
	Paramolar	5	12.2%	2	40%	3	60%
	Palate	2	4.8%	2	100%	0	0%
Location in relation to the axis of eruption	Palatal	9	22%	9	100%	0	0%
	Buccal	5	12.2%	3	60%	2	40%
	Lingual	7	17.0%	0	0%	7	100%
	In the long axis	11	26.8%	8	72.7%	3	27.3%
	Not classified	9	22%	-		-	
Divergence of roots	Mesiodent	3	7.3%	3	100%	0	0%

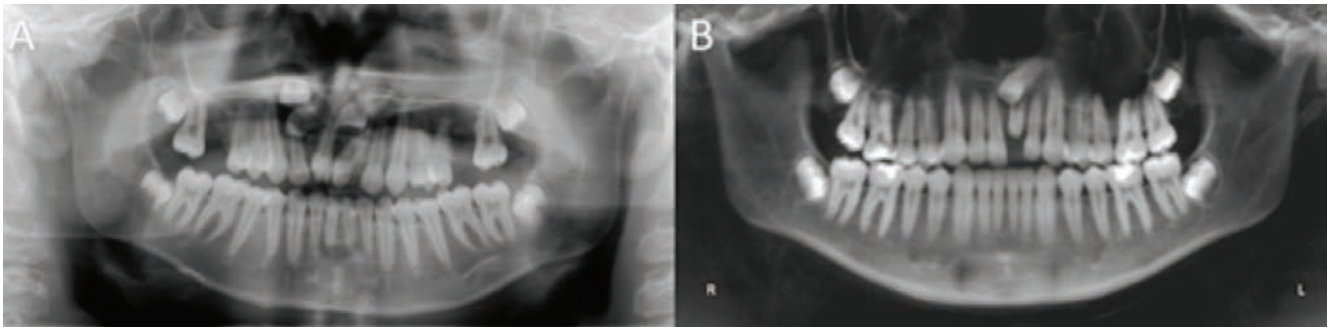

***Figure 1**: Mesiodentes: causing ectopic eruption of teeth 11 and 21 (A). Intercepting the correct axis of eruption of tooth 21 (B), on panoramic radiographs.*

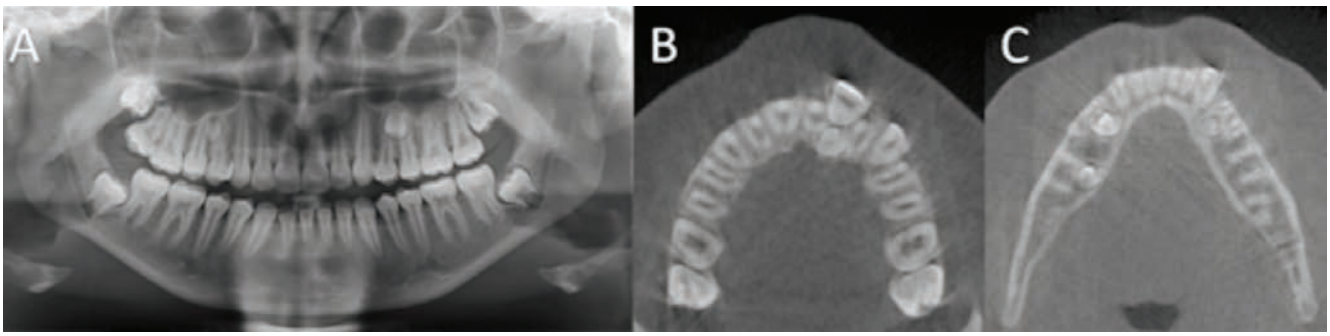

***Figure 2**: Supernumerary teeth observed in different patients: on panoramic radiograph in the upper premolars regions (A), the palatal position (B) and the lingual position in relation to the teeth of the normal series seen in axial sections of cone beam computed tomography (C).*



***Figure 3**: Supernumerary tooth occupying the position in the alveoli and displacing the tooth of the normal series for vestibular, intraoral upper arch occlusal view (A) and intraoral frontal view (B).*



***Figure 4**: Diastema caused by a supernumerary tooth visualized in cone beam computed tomography (A), two-dimensional projection of the cone beam computed tomography (B) and intraoral clinical view (C).*

DISCUSSION

This epidemiological study on the prevalence of supernumerary teeth in orthodontic documentation of a selected population found that 2.7% of the sample presented the problem. In the literature, this anomaly of number affects up to 2% of the population,[16-18] however the present study involved a distinct population, of individuals seeking orthodontic treatment. In addition, the institution demands accurate records, such as CBCTs, in order to achieve correct diagnosis and to provide the best treatment plan, especially in cases with supernumerary elements, as expected. A proper indication for a CBCT exam can be an excellent tool for the clinician, not only for the orthodontist, in the diagnosis of a supernumerary teeth, providing a better treatment plan.

It should be noted that more than half of the supernumerary teeth were presented in the supplemental form and exhibited normal eruption axis orientation, and just over a quarter were well located in the alveolar process, in relation to the axis. Although there are reports showing the predilection for the mandible in certain populations,[19,20] the literature shows that preferential area for the formation of supernumerary teeth is in the maxillary anterior segment, especially in cases where there are multiple supernumerary teeth.[4,11,14,16-21] In fact, in this sample, the frequency of supernumerary teeth in the maxilla occurred in more than half of the sample. The majority of these teeth were mesiodens, which is the most prevalent location described in the literature.[5,13,14,17] These mesiodens comprised slightly less than half of the cases in this study, which directly interferes in the aesthetics of the individual. The parapremolars were as frequent as the mesiodens and were located in the mandible in twelve of the cases, while only five were in the maxilla. Supernumerary teeth may also occur in the deciduous dentition, but the permanent dentition is more frequently affected.[5,11,12,16,19,21]

The gender of the patients with supernumerary teeth presented, approximately, a 1:1 ratio, while other authors reported a male/female ratio of 2:1.[4,5,12,13,16,17,19,21] We do not know the reason for this difference.

Despite all the data reported in the literature, the etiology of supernumerary teeth is not well established. Factors such as the hyperdevelopment of dental lamina, resulting from disturbances in the initiation stage of tooth formation may lead to the development of single or multiple supernumerary teeth (hyperdontia) or its absence (hypodontia).[12] Trauma involving the anterior region of the maxilla during the development of the dental follicle may also cause the development of supernumerary teeth, by tooth division.[5,12] It is also valid to consider the dichotomy theory of the tooth bud[19] that may lead to two teeth of the same size or a normal tooth and a dysmorphic one.[7] However, despite the various described theories, the literature highlights the hyperactivity of the dental lamina as the most likely etiology.[7,12,19]

Hereditary/genetic factors have been described in the etiology of supernumerary teeth, in which a genetic component would be linked to autosomal dominant inheritance with incomplete penetration.[4] The association with a hereditary syndrome may also occur. However, it is important to stress that the presence of supernumerary teeth is inherent to syndromes as cleidocranial dysostosis and Gardner syndrome, and may or not occur in association with cleft palate and cleft lip.[4,12,22]

Regarding the curious theory of atavism, researchers point out that the phenomenon of supernumerary teeth would be the resurgence of features lost for generations, in an attempt to revoke the dentition of the ancestors, i.e. the reappearance of teeth suppressed or eliminated in the evolutionary process, featuring a reverse evolution.[4,12,22]

Although there are controversies regarding the etiological factors, it is well known that supernumerary teeth can develop relevant clinical complications. When supernumerary teeth are impacted, they may delay or prevent the eruption of other teeth, lead to rotations or deviations from the normal pathway, cause root resorption to adjacent teeth, and also develop cysts with possible bone destruction.[5] Once the supernumerary teeth have erupted, they may cause crowding, teeth misalignment in the arches and possible midline diastema. In any case, they will cause some sort of malocclusion.[12,13]

There are controversies in relation to the management of supernumerary teeth.[11] First question is the indication for dental extraction as soon as supernumerary is identified. However, this can lead to psychological insecurity in children, and may promote ankylosis, root canal or adjacent tooth deformation. Furthermore, if postponing dental extraction until the root of the adjacent tooth is completely formed is recommended, this also shows consequences as weakening of the eruptive force of the normal permanent teeth, losing space in the arches and promoting crowding. The choice of treatment will be influenced by factors such as: patient's age and collaboration, stage of development of the adjacent teeth and the supernumerary tooth position, due to the surgical access and bone loss.[5,16,23] Some authors state that supernumerary teeth interfering with occlusion must be extracted, as long as it doesn't hurt the root development of the adjacent teeth.[24]

As an epidemiologic study, this research has the limitation of evaluating a restricted population, since there was only access to patients who sought a solution to the

problem that they themselves recognized. However, the representative prevalence of dental anomalies has not shown important differences, when compared to other studies.

This epidemiological study is of scientific importance, since there is a growing interest in the epidemiology scenario by researchers. From data collection and identification of suggestive images at the moment of diagnosis, it is possible to modify the planning approach and guidance to the patient, aiming at the improvement of the results during and at the end of treatment, demonstrating the clinical importance of the research.

CONCLUSION

The frequency of supernumerary teeth in the studied population was of 2.7%, with preferred location on the anterior maxillary area and mandibular parapremolar area. The most prevalent types of supernumerary teeth were the supplemental form, with normal eruption orientation and normal axial alveolar location. The supernumerary teeth of patients in this study showed minor interference in the ectopic eruption of the normal dental series. Most of the supernumerary teeth were impacted, and approximately one third showed eruption deviations from the correct axis, and only few cases exhibited divergence of adjacent roots.

ACKNOWLEDGEMENTS

This work was carried out with the financial support of the Coordenação de Aperfeiçoamento de Pessoal de Nível Superior (CAPES) - Financing Code 001.

REFERENCES

1. Barberia-Leache E, Suarez-Clua MC, Saavedra-Ontiveros D. Ectopic eruption of the maxillary first permanent molar: characteristics and occurrence in growing children. Angle Orthod. 2005;75:610–615.

2. Proff P, Bayerlein T, Fanghanel J, Allegrini S Jr, Gedrange T. Morphological and clinical considerations of first and second permanent molar eruption disorders. Ann Anat. 2006;188:353–361.

3. Hwanga S, Choib YJ, Leec JY, Chungd C, Kime K. Ectopic eruption of the maxillary second molar: Predictive factors. Angle Orthodontist, 2017 Vol 87, No

4. Neville BW, Damm DD, Allen CM, Bouquot JE. Patologia Oral e Maxilofacial. 3ª ed. Rio de Janeiro: Elsevier Editora; 2009.

5. Rocha AML, Neto JC, Souza MMG. Supernumerary Teeth in Maxillary Incisors Zone. J Bras Ortodon Ortop Facial, Curitiba, 2002 v.7, n.41, p.389-396.

6. Garvey MT, Barry HJ, Blake M. Supernumerary Teeth -An Overview of Classification, Diagnosis and Management. J Can Dent Assoc 1999; 65:612-6

7. Mallineni SK. Supernumerary Teeth: Review of the Literature with Recent Updates. Conference Papers in Science. Volume 2014, Article ID 764050, 6 pages.

8. Demiriz L, Durmuþlar MC, Mýsýr AF. Prevalence and characteristics of supernumerary teeth: A survey on 7348 people. J Int Soc Prev Community Dent. 2015 May; 5(Suppl 1): S39–S43.

9. Khandelwal P, Rai AB, Bulgannawar B, Hajira N, Masih A, Jyani A. Prevalence, Characteristics, and Morphology of Supernumerary Teeth among Patients Visiting a Dental Institution in Rajasthan. Contemp Clin Dent. 2018 Jul-Sep; 9(3): 349–356.

10. Soares AB, Ferreira-Filho UG, Marzola C, Toledo-Filho JL, Barbosa JL, Haagsma IB. Supermumerary teeth prevalence in the Municipality of Curitiba, Paraná, Brazil, and their Positions in the Dental Arch on 3000 Panoramic Radiographs. 2010. Brazilian journal of buccomaxillofacial surgery. V10 N1 P. 23 – 32.

11. Scheiner MA, Sampson WJ. Supernumerary teeth: A review of the literature and four case reports. Australian Dental Journal 1997;42:(3):160-5.

12. Castilho JB, Guirado CG, Magnani MBBA. A literature review on supernumerary teeth. RFO UPF, Passo Fundo, v.2, n.2, p.25·32, jul. /dez.1997.

13. Akgun OM, Sabuncuoglu F, Altug A, Altun C. Non-syndrome patient with bilateral supernumerary teeth: Case report and 9-year follow-up. European Journal of Dentistry. January 2013 - Vol.7.

14. Coelho A, Macho V, Andrade D, Macedo P, Areias C. Prevalence and distribution of supernumerary teeth in a pediatric population - A radiographic study. Rev Port Estomatol Med Dent Cir Maxilofac. 2011;5 2(4):189–192.

15. Parolia A, Kundabala M, Dahal M, Mohan M, Thomas MS. Management of supernumerary teeth. J Conserv Dent. 2011; 14(3): 221-4.PMid:22025821 PMCid:3198547. http://dx.doi.org/10.4103/0972-0707.85791

16. Moura WL, Cravinhos JCP, Moura CDVS, Freire SASR, Monteiro AMO, Pinheiro DAS, et al. Prevalence of supernumerary teeth in patients attended at the University Hospital of UFPI: a retrospective study of five years. Rev Odontol UNESP. 2013 May-June; 42(3): 167-171

17. Negrete D, Carvalho PEG, Fuziy A, Torres FC, Triviño T, Flaiban E. Supernumerary teeth prevalence in Orthodontic patients. Rev. Odontol. Univ. Cid. São Paulo 2015; 27(1): 6-13, jan-abr.

18. Syriac G, Joseph E, Rupesh S, Philip J, Cherian SA, Mathew J. Prevalence, Characteristics, and Complications of Supernumerary Teeth in Nonsyndromic Pediatric Population of South India: A Clinical and Radiographic Study. J Pharm Bioallied Sci. 2017 Nov; 9(Suppl 1): S231–S236.

19. Corrêa FG, Ferreira FV, Friedrich LR, Pistóia AD, Pistóia GD. Prevalence of supranumerary teeth – retrospective study. Int J Dent, Recife, 8(1):11-15, jan./mar.,2009

20. Loreto AFV, Kelmer F, Oliveira RV. Supernumerary in the region of jaw interfering in occlusion: diagnosis, and treatment planning of a case. Revista UNINGÁ Review. Vol.21,n.1,pp.27-31 (Jan – Mar 2015).

21. Diaz A, Orozco J, Fonseca M. Multiple hyperodontia: Report of a case with 17 supernumerary teeth with non syndromic association. Med Oral Patol Oral Cir Bucal. 2009 May 1;14 (5):E229-31.

22. Gupta A, Nagar P, Khandeparker RVS, Munjal D, Sethi HS. Hyperactive Dental Lamina in a 24-Year-old Female – A Case Report and Review of Literature. Journal of Clinical and Diagnostic Research. 2015 Aug, Vol-9(8): ZE01-ZE04.

23. Fader M, Kline SN, Spatz SS, Zubrow HJ. Gardner's syndrome (intestinal polyposis, osteomas, sebaceous cysts) and a new dental discovery. OS, OM e OP. 1962 February. Volume 15. Number 2.

24. Reis LFG, Giovanini A, Namba EL, Silva ELFM, Garcia MA. Supernumerary teeth interfering in the orthodontic treatment. RSBO v. 3, n. 2, 2006.