SURGICAL TREATMENT OF ANKYLOGLOSSIA USING AN OPHTHALMIC TOPICAL ANESTHETIC AND A TENTACANNULA FOR TONGUE ELEVATION: A CASE REPORT

Leógenes Maia **Santiago**[1]*, Eduardo Sérgio Donato **Duarte Filho**[1], João Carlos Amorim **Lopes**[2], Fernanda Maria Barros **Guerra**[3], Carlos Frederico de Moraes **Sarmento**[4], Dellano Fernandes da Silva **Santos**[5]

[1]Dentistry College, ASCES-UNITA University Center, Caruaru, PE, Brazil; Departament of Periodontology, University of Pernambuco, Arcoverde, PE, Brazil
[2]Dental Medicine College, Portuguese Catholic University, Viseu, Portugal
[3]Post-Graduate Program in Dentistry, Potiguar University, Natal, RN, Brazil
[4]Dentistry College, Federal University of Pernambuco, Recife, PE, Brazil
[5]Dentistry College, ASCES-UNITA University Center, Caruaru, PE, Brazil

Palavras-chave: Freio Lingual. Fonética. Administração Tópica. Anestesia local. Procedimentos cirúrgicos orais. Instrumentos cirúrgicos.

RESUMO

Introdução: A anquiloglossia caracteriza-se pela presença de um freio lingual curto que pode inserir-se desde o rebordo alveolar até o ápice lingual e, até promover uma verdadeira fusão da língua ao assoalho. Um freio lingual curto poderá gerar vários problemas como distúrbios fonéticos. **Objetivo**: descrever uma técnica cirúrgica para tratamento da anquiloglossia utilizando um anestésico tópico oftálmico e uma tentacânula para elevação da língua. **Relato do caso**: Uma paciente com 15 anos de idade foi encaminhada para cirurgia do frênulo lingual devido à comprometimento da fala. O exame clínico revelou a presença de anquiloglossia, dificultando a pronúncia dos fonemas T, D, L e, reduzindo a mobilidade da língua. A técnica cirúrgica escolhida foi a frenectomia lingual. Um anestésico tópico oftálmico foi aplicado inicialmente nas bordas laterais do freio com o paciente na posição vertical e na presença de aspiração adequada. Com o auxílio de uma tentacânula, a língua foi elevada e o frênulo foi gradualmente liberado com uma tesoura serrilhada Goldman-Fox. O anestésico tópico foi continuamente gotejado para o local cirúrgico durante a cirurgia. Resultados: Nenhuma dor pós-operatória foi relatada pelo paciente, a cicatrização ocorreu normalmente e não houve recorrência da inserção anormal do frênulo. **Conclusão**: As vantagens dessa técnica em comparação aos métodos convencionais que utilizam anestesia infiltrativa, incluem menor trauma e uma avaliação mais precisa dos movimentos da língua durante a cirurgia, pois haverá um melhor controle da mobilidade do paciente quando comparado às técnicas infiltrativas.

Keywords: Lingual frenum. Phonetics. Topical administration. Local anesthesia. Oral surgical procedures. Surgical instruments.

ABSTRACT

Introduction: Ankyloglossia is characterized by the presence of a short lingual frenum that can be inserted from the alveolar ridge to the lingual apex and, until promoting a true fusion of the tongue to the floor. A short lingual frenum can generate several problems such as phonetic disorders. **Objective**: To describe a surgical technique for the treatment of ankyloglossia using a topical ophthalmic anesthetic and a tentacannula for tongue elevation. **Case report**: A 15-year-old female was referred for lingual frenulum surgery due to speech impairment. Clinical examination revealed the presence of ankyloglossia which was both hindering the pronunciation of T, D, L phonemes and reducing tongue mobility. The surgical technique chosen was a lingual frenectomy. An ophthalmic topical anesthetic was initially applied to the lateral borders of the frenum with the patient in an upright position and in the presence of adequate aspiration. With the aid of a tentacannula the tongue was raised and the frenulum gradually released with a Goldman-Fox serrated scissor. The topical anesthetic was continuously trickled onto the surgical site during surgery. Results: No postoperative pain was reported by the patient, healing occurred normally and there was no recurrence of abnormal frenulum insertion. **Conclusion**: The advantages of this technique in comparison to conventional methods which use infiltrative anesthesia include less trauma and a more precise evaluation of tongue movements during surgery, because there will be better control of mobility for the patient when compared to infiltrative techniques.

Submitted: April 22, 2020
Modification: June 08, 2020
Accepted: June 22, 2020

***Correspondence to:**
Leógenes Maia Santiago
Address: Frei Caneca, 360 - Boa Vista, Garanhuns, PE, Brazil
ZIP CODE: 55292-515
Telephone Number: +55 (87) 99809-3729
E-mail: leogenessantiago@asces.edu.br

INTRODUCTION

Etymologically, ''ankyloglossia'' originates from the Greek words ''agkilos" (curved) and ''glossa" (tongue).[1] Ankyloglossia, commonly known as tongue-tie, is a congenital oral anomaly characterized by a short, thick lingual frenulum, a membrane connecting the ventrum of the tongue to the floor of the mouth.[2] Ankyloglossia varies in degree of severity, from mild cases characterized by mucous membrane bands to complete ankyloglossia in which the tongue is tethered to the floor of the mouth.[3-5] The anomaly may contribute to difficulty in the articulation of specific tongue-thrust sounds. It has also been implicated as a cause of poor sucking, chewing or swallowing.[5] Some have also suggested that ankyloglossia contributes to periodontal disease[3] and to lower incisor diastema[6] due to its high insertion in the alveolar ridge.

The attachment of the lingual frenulum in newborn babies goes from the tip of the tongue to the lower jaw.[7] The tongue is an important oral structure for the newborn infant because it affects swallowing and nutrition. As the jaw grows vertically, there is an increase in vertical dimension, as well as lingual enlargement and tooth eruption. The lingual frenulum, then migrates to its definite position in the middle portion of the ventral tongue. With ankyloglossia, however, the lingual frenulum has an anterior attachment near the tip of the tongue and may also be unusually short.[8]

The mobility of the tongue is related to the lingual frenulum, which originates from an embryonic fusion of the tongue and floor of the mouth. These two structures are later separated as normal growth occurs.[8]

The treatment of ankyloglossia may be either conservative or radical. Conservative treatment includes speech therapy which promotes stretching of the tongue via exercises and may help the child to pronounce sounds more clearly. The radical approach is the surgical removal/repositioning of the frenum.[9]

Authors have referred to three methods of lingual frenulum surgery: a frenectomy, a procedure which involves the removal of the frenulum; a less extensive clipping of the frenulum (sometimes referred to as frenotomy), and surgical repositioning of the lingual frenulum attachment which is sometimes referred to as frenuloplasty.[10,11]

A study investigating methods of assessment and management of ankyloglossia was conducted among health workers of three different areas: otolaryngologists, speech pathologists and dentists. There was a consensus regarding the assessment of tongue-tie among the professionals, but there was disagreement regarding the primary indication for surgery.[12]

Frenectomy for tongue-tie release using a topical ophthalmic anesthetic 1% was first indicated for infants,[13] because local infiltrative anesthesia was thought to represent a risk. In the technique used the topical anesthetic is applied to the ventral surface of the tongue. This technique has also been used in adults without any postoperative complications and minimal bleeding and discomfort as long as it is indicated and executed properly.[14]

The frenectomy procedure requires a clear view of the operative field and complete stabilization of the tongue,[15] which may be accomplished by using a grooved surgical retractor also known as "tentacannula" which is commonly used in medicine for the drainage of abscesses.

The purpose of this clinical case report is to present a different frenectomy technique with the use of an topical ophthalmic anesthesic and the aid of a tentacannula for tongue elevation on a teenage patient with speech articulation problems.

CASE REPORT

A 15-year-old female patient complaining of improper speech was referred by a speech pathologist for surgical correction of ankyloglossia. Oral examination revealed short and forward ankyloglossia[16] (Figure 1) and restriction of tongue tip elevation which hampered proper articulation of tongue sounds – such as "t", "d" and "l". Patient without any systemic or oral changes other than ankyloglossia.

The procedure chosen was a frenectomy using a tentacannula (Thimon, Sao Paulo, SP, Brazil) (Figure 2) for tongue elevation. The tentacannula, at its active end, has a slit in which the frenulum settles and a flat side surface next to this slit, in which the tongue ventrum comes into contact. Posteriorly, an ophthalmic anesthesic applied to the tongue ventrum adjacent to the frenulum (Figure 3), after initial drying with gauze in the frenulum region. The composition of this anesthetic is: each ml (31 drops) contains 10 mg of tetracaine hydrochloride (0.322 mg/drop) and 1 mg of phenylephrine hydrochloride (0.032 mg/drop). The use of a powerful aspirator placed on the floor of the mouth is paramount (Figure 4) and the patient should be operated in an upright position in order to avoid swallowing the ophthalmic solution.

Before the surgical procedure, an extra-oral antisepsis was performed with 1% chlorhexidine digluconate and mouthwash with 0.12% chlorhexidine digluconate for 1 minute.

After adequate anesthesia was confirmed, the tentacannula was used to elevate the tongue and tense the frenulum and cuts were made along the tongue ventrum

with a Goldman-Fox scissor (Figure 5). During the procedure, an ophthalmic topic anesthesic "Oculum" (Allergan®, São Paulo, Brazil, www.allergan.com.br) was continuously trickled onto the surgical site and the patient was asked to move the tongue to allow visualization for subsequent cuts until complete release of the frenulum.

The anesthetic step from the form of use to its quantity could be described in detail in the following way: two bilateral aspirators are placed in the frenulum region and two gauzes are also placed bilaterally to prevent the flow of eye drops to the oral floor region. After lifting the tongue with the aid of the tentacannula, 4 drops are slowly deposited, at intervals of 30 seconds on average, in the region of the frenulum where the beginning of the frenectomy with the Goldman-Fox serrated scissors will begin. After 2 minutes, the sensitivity was checked with a small touch on the region with tweezers. After the absence of sensitivity, frenectomy can be started. In this case, the placement of two more gutters laterally to the site of the beginning of the primary surgical wound was also complemented, not requiring the addition of drops until the end of the procedure. In all, 18 drops were deposited.

After release of the frenulum, the surgical wound was sutured with a 4-0 Ethicon® silk-suture (Johnson-Johnson®, Sao Paulo, Brazil, www.jnjbrasil.com.br) (Figure 6). There was no excessive bleeding or pain during the procedure. Postoperative instructions were given as non-narcotic analgesics were prescribed to alleviate possible discomfort and the patient was discharged (Dipyrone 500mg was instituted every 6 hours on the first day and a more pasty and cold diet).

During follow-up reattachment of the frenum by excessive scarring was not observed and the patient did not report postoperative pain. The patient was then referred back to the speech language pathologist for proper post-surgery exercises in order to achieve a successful outcome. The patient was followed up for 6 months and, after returning at 1 year, didn't show any sign of recurrence.

Attention is drawn in the present case report that, taking into account that in the anesthetic tube in concentrations at 2% there is 36mg of the anesthetic, it can be related that, in the case of collyrium, with a condition of at most 18 drops, around 5mg of anesthetic (tetracaine) is used. Since it is associated with a vasoconstrictor, phenylephrine, a sympathomimetic agent with vasoconstrictor action, there is a limitation to systemic absorption of tetracaine, prolonging the anesthetic effect. Considering that the desensitization conditions are not obtained in the amount of drops indicated above, the infiltrative technique would be considered again for use in the procedure.



***Figure 1**: Intraoral view of the patient with ankyloglossia.*



***Figure 2**: Tentacannula.*



***Figure 3**: Use of the ophthalmic topical anesthetic and tentacannula.*

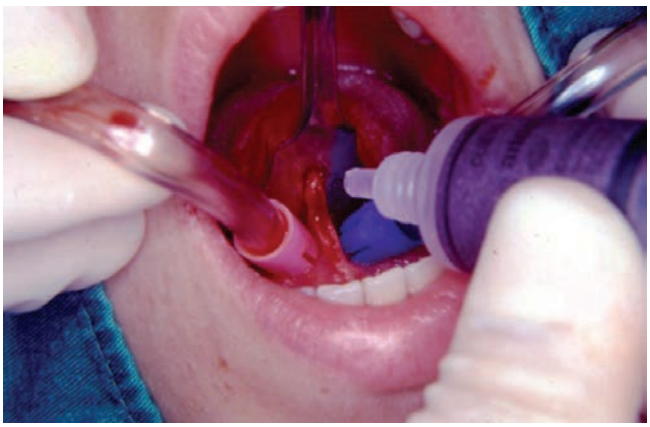

***Figure 4**: Aspiration essential to avoid swallowing the anesthetic.*

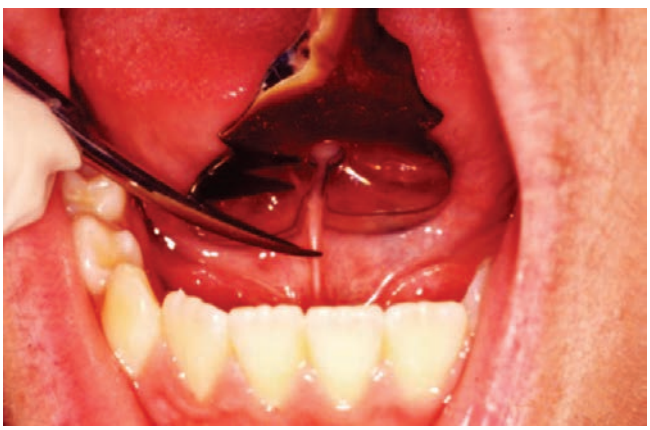

***Figure 5**: Elevation of the tongue and cut of the tongue ventrum.*

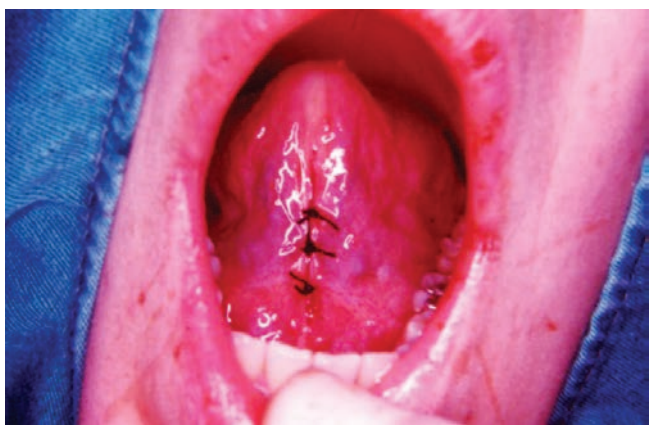

***Figure 6**: Suture.*

DISCUSSION

Ankyloglossia, or tongue-tie, is a congenital anomaly in which a short, lingual frenum or a highly attached genioglossus muscle restricts tongue movement. This can lead to a range of problems such as difficulties in breast feeding in infancy, swallowing, mandibular prognatism and speech articulation defects[8,9] as presented in our case report.

A short lingual frenum limits tongue movements hampering adequate pronunciation of certain words[9]. Clinically, the patient in our case report was not able to articulate lingual sounds and sibilants such as T, D and L as a manifestation of symptomatic tongue-tie.[5,17] Evidence[3] indicates that three in each 10000 children with tongue-tie have difficulty in the articulation of certain speech sounds.

There is no consensus in the literature as to the optimal time for surgery. Some advocate early surgical intervention, as soon as the frenum is diagnosed as abnormall.[4] Correction at an early age reduces the risk of development of incorrect speech movements and swallowing. Others, on the other hand, suggest that surgery must be delayed until the age of four or five.[5,17] Optimal management of tongue tie including timely and appropriate surgical intervention should involve a multidisciplinary team with the participation of dentists, speech pathologists and pediatricians, the latter in the case of infants.[8]

Although the frenectomy technique using topical anesthesia and a tentacannula was originally indicated for babies,[13] adults may be treated using the same technique if proper evaluation and precautions are undertaken.[14] The use of the tentacannula in a lingual frenectomy is a tool that facilitates the procedure by keeping the tongue in a stable position allowing a better view of the operative field.[15]

In the frenectomy procedure here reported the tentacannula was used to hold the tongue up towards the roof of the mouth and make the frenum taut, facilitating its delimitation and subsequent excision of the area of tissue to be eliminated[7]. The greatest advantages of the use of a tentacannula is that the tongue is elevated without the need for transfixation of its tip with a suture as performed in conventional frenectomy techniques and is a good alternative to the the tongue stabilization (a big problem for professionals in performing frenectomy).

The lingual frenectomy presented in this paper was performed as recommended in literature: the initial cut begins at the free border of the frenum and proceeds posteriorly.[7] Each cut provides some release, allowing visualization for subsequent cuts. Extreme care must be taken not to incise any vascular tissue or cause damage to Wharton's ducts. Once tissue margins are undermined and wound edges are approximated, closure may be achieved

with a simple sutures.[18] It must be said however that whereas standard frenectomies may be carried by the general practitioner, ankyloglossia due to the anomalies of the genioglossus muscle, previously mentioned[8,9] should only be surgically treated by oral surgeons.[10]

According to the literature,[8] there weren't postoperative complications, the discomfort is brief and less when moving the tongue. The patient should be referred to a speech therapist for postoperative exercises.

The option for topical anesthesia used, as well as tentacannula, advantages and disadvantages in relation to other formulations available for anesthesia and techniques can be explained as follows: taking the necessary precautions, this technique has the advantage of allowing the patient to have greater control over the movement of the tongue during the transoperative stage, which helps to verify the release by the movements performed by the patient. In addition, the possibility of not using infiltrative anesthesia can be a differential for patients more anxious or reactive to local anesthesia. It should also be emphasized that the design of the tentacannula enables an adequate immobilization of the tongue, effectively exposing the lingual frenum, which facilitates the surgical stage, mainly in its use in pediatric patients, for example.

CONCLUSION

This technique has been used in adults/teenagers patients and among its main advantages is the fact that the patient can be operated without the standard infiltrative local anesthesia which is more easily accepted and allows the patient a better control of tongue movement during the procedure.

A number of surgical procedures have been used to treat ankyloglossia. This article reported on the possibility of performing lingual frenectomies in adults/teenagers with the use of an ophthalmic topical anesthetic and a tentacanula for tongue retraction. It is proposed that with proper training this relatively simple frenectomy technique may be performed by the general dentist.

In short, the advantages of this technique in comparison to conventional methods which use infiltrative anesthesia include less trauma and a more precise evaluation of tongue movements during surgery, because there will be better control of mobility for the patient when compared to infiltrative techniques.

REFERENCES

1. Friggi MNP, Orsi RM, Chelotti A. Pediatric surgical technique: lingual frenotomy. J. Bras. Odontopediatr. Odontol. Bebe. 1998;1(3):101-15.

2. Hooda A, Rathee M, Yadav SPS, Gulia JS. Ankyloglossia: a review of current status. The Internet Journal of Otorhinolaryngology. 2010;12(2):7p.

3. Neville BW, Damm DD, Allen CM, Bouquot JE. Oral and maxillofacial pathology. 3rd ed. St. Louis: Saunders/Elsevier; 2009.

4. Berg KL. Two cases of tongue-tie and breastfeeding. J Hum Lact. 1990;6(3):124-6.

5. Godley FA. Frenuloplasty with a buccal mucosal graft. The Laryngocospe. 1994;104(3):378-81.

6. Verco PJW. Case report and clinical technique: argon beam electrosurgery for tongue ties and maxillary frenectomies in infants and children. European Archives of Paediatric Dentistry. 2007;8:15-19.

7. Guedes-Pinto AC. Odontopediatria. 7th ed. Sao Paulo: Santos; 2006.

8. Correa MSNP. Pediatric dentistry in the childhood. 2nd ed. Sao Paulo: Santos, 2005.

9. Gregori C, Campos AC. Surgery oral-dental-alveolar. 2nd ed. Sao Paulo: Sarvier; 2005.

10. Marzola C. Preprosthetic surgery. 3rd ed. Sao Paulo: Pancast; 2004.

11. Abreu MER, Mezzomo LAM, Viegas VN, Pagnoncelli RM. Laser and its use in inferior labial frenectomy – case report. Journal of Dental Science. 2002;17(37):250-3.

12. Brito SF, Marchesan IQ, Bosco CM, Carrilho ACA, Rehder MI. Lingual frenulum: classification and conduct according to speech language pathologist, odontologist and otorhinolaryngologist perspective. Rev. CEFAC. 2008;10(3):343-51.

13. Walter LRF, Ferelle A, Issao M. Dentistry for baby: pedodontics from birth until three years old. Sao Paulo: Artes Medicas, 1997.

14. Kotlow LA. Ankyloglossia (tongue-tie): a diagnostic and treatment quandary. Quintessence Int. 1999;30(4):259-62.

15. Formolo E, Orabe PMP, Isolan TMP, Caldart LF. Lingual frenectomy using Tentacanule. RGO. 1997;45(1):29-32.

16. Marchesan IQ. Protocolo de avaliação do frênulo da língua. Rev. CEFAC. 2010;12(6):977-89.

17. Wright, JE. Review article – tongue-tie. Journal of Paediatrics and Child Health. 1995;31(4):276-8.

18. Freitas R. Tratado de cirurgia bucomaxilofacial. Sao Paulo: Santos; 2008.