MULTIDISCIPLINARY CONSERVATIVE MANAGEMENT OF DENTAL FRACTURE IN YOUNG PATIENT: CASE REPORT

Aline dos Santos **Letieri**[1], Lucas Alves **Jural**[2], Paula Moraes **Lima**[1], Cinthia Marques **Sperduto**[2], Jeane Batista dos **Santos**[2], Lívia Paes **Borges**[3], Luiza Seabra Martins **Mattos**[3], Thaís Rodrigues Campos **Soares**[1], Gisele Damiana da Silveira **Pereira**[2], Lucianne Cople **Maia**[1*]

[1] Department of Pediatric Dentistry and Orthodontics, School of Dentistry, Universidade Federal do Rio de Janeiro, Rio de Janeiro, RJ, Brazil.
[2] School of Dentistry, Universidade Federal do Rio de Janeiro, Rio de Janeiro, RJ, Brazil.
[3] Department of Dental Clinic, School of Dentistry, Universidade Federal do Rio de Janeiro, Rio de Janeiro, RJ, Brazil.

Palavras-chave: Fraturas dos Dentes. Traumatismos Dentários. Tratamento Conservador. Restauração Dentária Permanente.

RESUMO

Introdução: O manejo de dentes permanentes fraturados por traumatismo dentário em pacientes jovens é desafiador e requer uma abordagem eficiente. **Objetivo:** Descrever o tratamento conservador e multidisciplinar em um caso de traumatismo dentário de um menino de 13 anos de idade. **Relato do caso:** Ao exame clínico foi verificada uma fratura de esmalte e dentina no incisivo central superior esquerdo e uma fratura complicada no incisivo lateral superior direito, com extensão subgengival da margem na face palatina, e não foram observados edema ou deslocamento dentário. Ao exame radiográfico, não foram verificadas alterações pulpares ou perirradiculares. Foi proposta realização de aumento da coroa clínica do incisivo lateral superior direito para posterior realização do tratamento endodôntico. Para os dois dentes traumatizados foi proposta a realização de restauração direta com resina composta, proporcionando um tratamento menos invasivo ao incisivo lateral superior direito, ao invés de submetê-lo a um tratamento protético, como a colocação de uma coroa total cerâmica, principalmente devido à pouca idade do paciente. Na visita de dois anos de acompanhamento, observou-se a manutenção da saúde dos tecidos periapicais e ausência de alterações clínicas. **Conclusão:** As restaurações se mantiveram em boas condições e a estética foi considerada satisfatória pelos profissionais, paciente e pais.

Keywords: Tooth Fractures. Tooth Injuries. Conservative Treatment. Dental Restoration Permanent.

ABSTRACT

Introduction: The management of fractured permanent teeth due to dental trauma in young patients is a challenge that requires an efficient approach. **Objective**: Describe a conservative and multidisciplinary treatment of a case of dental trauma in a 13 years-old boy. **Case report:** At clinical examination was verified enamel and dentin fracture in the left upper central incisor and a fracture with pulp exposure in the right upper lateral incisor, with subgingival extension of its margin at lingual surface, and no swelling or tooth displacement was observed. At radiographic evaluation, no pulp or periradicular disturbances were verified. It was proposed the surgical lengthening of the clinical crown of the right upper lateral incisor for later performing endodontic treatment. It was decided to make direct composite resin restorations in both fractured teeth, instead of doing a prosthetic treatment in the affected lateral incisor, such as the placement of a full ceramic crown, in an attempt to perform a less invasive treatment, mainly due to the age of the patient. At a two years follow-up visit was observed the maintenance of the health of periapical tissues and the absence of clinical alterations. **Conclusion:** The restorations were kept in good conditions and aesthetics was considered satisfactory by professionals, patient and parents.

Submitted: February 12, 2020
Modification: March 10, 2020
Accepted: March 30, 2020

***Correspondence to:**
Lucianne Cople Maia
Disciplina de Odontopediatria da Faculdade de Odontologia - UFRJ
Address: Caixa Postal: 68066 – Cidade Universitária - CCS - Zip Code: 21941-971 - Rio de Janeiro – RJ – Brazil
E-mail: rorefa@terra.com.br
Fax/phone: +5521 39382101

INTRODUCTION

Traumatic dental injuries are a public dental health problem worldwide and its prevalence among schoolchildren with 12 to 15 years old varies between 14.4% to 33.8%.[1] It is more prevalent in the permanent dentition[1] and the coronal fracture of maxillary anterior teeth can represent up to 22% of injuries to hard tissues, negatively affecting the health-related quality of life (OHRQoL) of children and adolescents,[2] while the restorative treatment of these injuries has a positive impact on the OHRQoL of these individuals.[3] This is mainly due to its anatomical characteristics and position in the dental arch.[4] Sport activities are the major cause related to its occurrence in the age group between 7 to 15 years[1] and children in mixed dentition period are considered a group at risk.[5]

The management of dental fractures is challenging, since the procedures should be directed to minimize undesired consequences,[1] requiring at least two treatment options. It is necessary not only the reconstruction of the tooth form, but also the perfect mimic of its color, besides considering the age and behavior of the patient.[6]

There are different types of operative procedures, including direct and indirect techniques, and this may influence aesthetic results and longevity of restoration. In cases of severe loss of coronary structure in anterior teeth, it is common to perform crown or fragment reattachment, in order to ensure a satisfactory aesthetically result through a simpler and faster technique. In cases in which the fractured tooth fragments are not available, the most indicated treatments consist of making indirect restorations, such as full ceramic crown. However, following a current trend of minimal intervention, direct placement with composite resins have been performed, because it is more conservative, repairable, predictable and less expensive option.[6,7]

The purpose of this manuscript is to report the unusual multidisciplinary conservative approach of a case of a 13 years-old boy with extensive permanent maxillary lateral incisor fracture and its successful two years follow-up.

CASE REPORT

A 13-years-old boy was referred to the Centro de Vigilância e Monitoramento de Traumatismos Dentoalveolares da Universidade Federal do Rio de Janeiro, Brazil (CVMT FO-UFRJ), with chief complain of two anterior teeth fractured. According to him and his mother, he had fallen and hit his mouth on the sidewalk. His first appointment was in an emergency public service one hour after the trauma, where it was done the endodontic access in the right upper lateral incisor and were given diet and oral hygiene instructions. Analgesics and an antimicrobial solution (Chlorhexidine 0,12%) for local application for one week were prescribed.

Patient medical history was not relevant and there was no history of previous dental trauma in both dentitions. The patient reported having the deleterious habit of onychophagia. Patient was in mixed dentition; no caries lesions were observed, and the oral hygiene was satisfactory.

After completing the Term of Free and Informed Consent, data from clinical examination were collected, combined with mother's report, allowed the diagnosis of concussion, as the type of injury that affected the supporting tissues of maxillary anterior tooth. In relation to hard tissues, the left maxillary central incisor presents an uncomplicated enamel and dentin fracture and the right upper lateral incisor, enamel and dentin fracture with pulp exposure, with temporary filling present, and subgingival extension of the fracture margin at lingual surface. Radiographic evaluation showed no signs of periapical neither pulp changes in left maxillary central incisor, but right upper lateral incisor showed a suggestive periapical lesion (Figure 1).

Patient was instructed to maintaining the hygiene of the affected area with soft toothbrush. All the possible treatments were explained to patient and his mother. To perform the full exposure of the fractured margins of lateral incisor, the following options were given: orthodontic extrusion of this element or surgical lengthening of the clinical crown. Regarding the restorative procedure to be used for this same tooth, the options were making a crown full of porcelain or a direct light-cured composite resin restoration.

After discussing about the advantages and disadvantages of each of the proposed procedures, choice was to perform a more conservative approach. The surgical lengthening of the clinical crown and the endodontic treatment of the right upper lateral incisor was performed (Figure 2). After these first steps, direct restorations were realized in right lateral and left central maxillary incisors with direct composite resins (Filtek™ Z350 XT®; 3M ESPE; Brazil) (Figure 3). All clinical procedures were done under local anesthesia (ALPHACAINE® 1:100.000; DFL; Brazil) and with rubber dam isolation.

At a two-years follow-up visit, clinical and radiographic evaluation was performed, and oral hygiene instructions were reinforced. Direct restorations showed up intact and their aesthetics were considered satisfactory for both the professional and the patient and his mother. The importance of maintaining the follow-up visits was explained to them. We could observe the success of the unusual conservative technique that was employed in this case, with no clinic or radiographic abnormality symptoms (Figure 4).

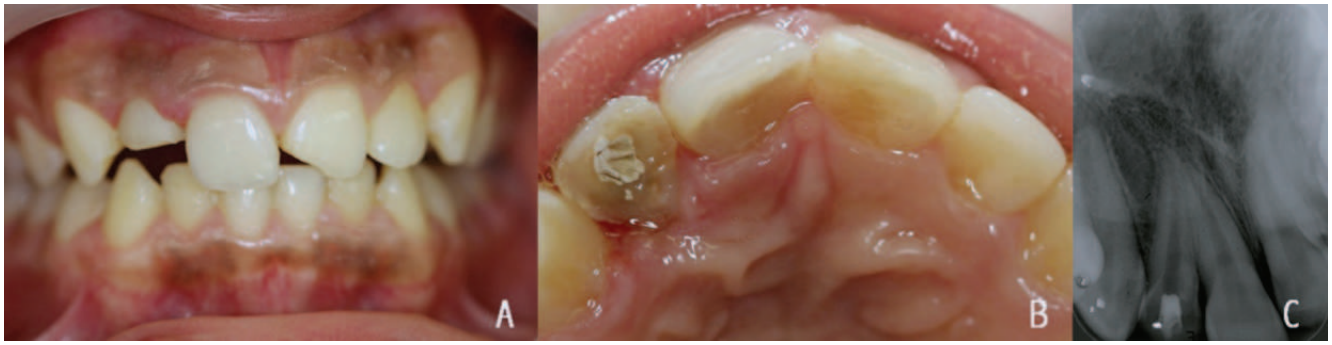

***Figure 1**:* (A) Initial frontal view showing the enamel and dentin fracture in the left upper central incisor and enamel and dentin fracture with pulp exposure in the right upper lateral incisor; (B) the occlusal photography and (C) the periapical radiography of the right upper lateral incisor.



***Figure 2**:* (A) Periapical radiography of the right upper lateral incisor after endodontic treatment and (B) the clinical aspect just after the endodontic treatment.

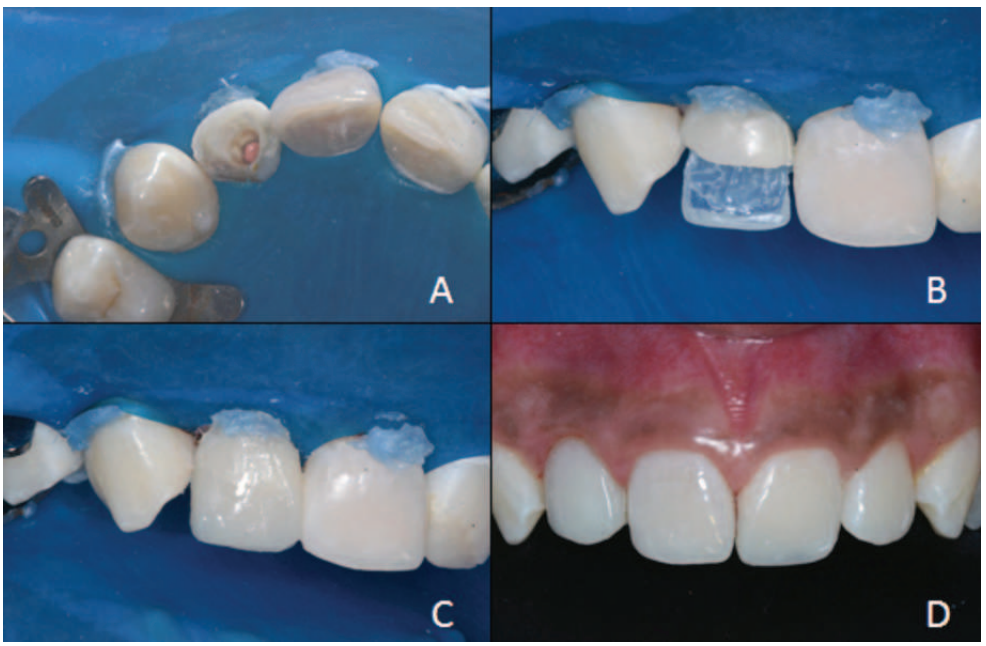

***Figure 3**:* (A) Occlusal view after rubber dam isolation; (B) reconstruction of the palatine surface; (C) aspect after direct restoration and (D) final image just after the restorative treatment of the left upper central incisor and the right upper lateral incisor.

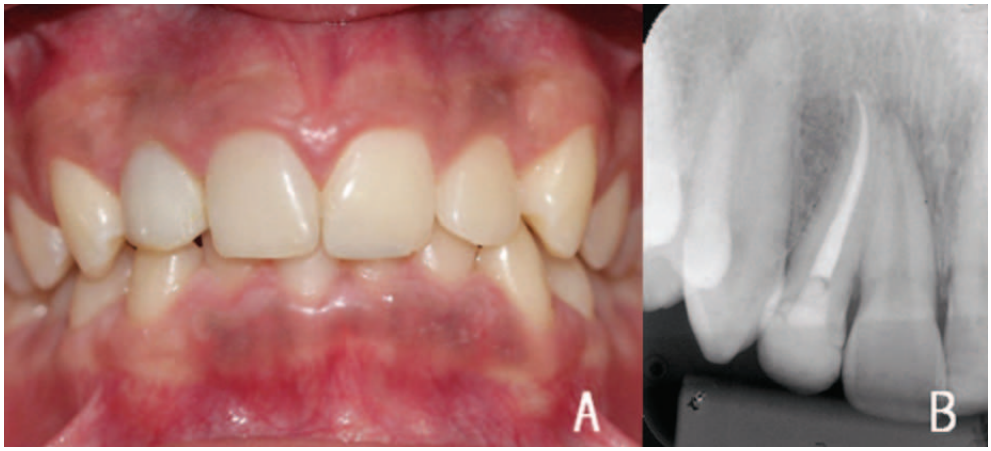

Figure 4: (A) Clinical view and (B) periapical radiographic after a two-year follow-up.

DISCUSSION

Cases of coronary dental fracture require a multidisciplinary approach, which allows a more complete, efficient and safe treatment.[8] Furthermore, management of patients at mixed dentition are a challenge, because they often require a pediatric dental approach to behavior, but also need of care on other dental areas. In the present case, the proposed treatment, based on the guideline of International Association of Dental Traumatology (IADT),[9] covered different dental specialties: pediatric dentistry, periodontics, endodontics and operative dentistry. It was fundamental for the success observed in this case.

It is important to note the role of the pediatric dentists in cases of dental trauma, since in most cases they will make the first contact with the newly injured patients. Therefore, these professionals should be prepared to make a quick and accurate diagnosis and formulate an appropriate treatment plan.[10] When necessary, it is crucial to referral the patient to other professionals to carry out the specific interventions, as was done in the present case.

It has been demonstrated that untreated dental fracture of permanent teeth in children may impact their quality of life.[2] Therefore, demands of patient and parents need to be considered and discussed with the dentist to choose the best treatment to be employed, in order to restore function and aesthetics of affected teeth.[11] Different treatment options were proposed to the patient and her mother in this case; advantages and disadvantages of each of them were explained and discussed with the professional. It was chosen a conservative approach, although the aesthetic desires of the patient were achieved.

Furthermore, it is important to note that treatment for injured teeth should be performed as early as possible, since the consequences are most frequently observed in a period of 3 months after trauma, and the most common complications are pulp necrosis and progressive inflammatory resorption.[12]

In the view of minimally invasive dentistry, injuries resulting from dental trauma have received an increasingly conservative approach, both in primary and permanent dentition.[12] Extensive coronary fractures, as in this case, has been treated with direct composite resin restorations, instead of conducting indirect techniques, such as total crowns. This is because this is a simple, fast and cheaper alternative and ensure a good aesthetic quality and predictability of results [7,8,11,13], being excellent in cases of young patients [7], as in the present case.

Absence of clinical and radiographic changes were verified at two-years follow-up visit. Patient and professional considered the aesthetics of the restorations as satisfactory. It was not observed marginal leakage or color change, which are, after secondary caries, the main causes for replacement of restorations [14].

CONCLUSION

The treatment proposed in the present case was a successful conservative approach for management of a complicated tooth fracture in a young patient.

ACKNOWLEDGMENT

This study was financed in part by the Coordenação de Aperfeiçoamento de Pessoal de Nivel Superior (CAPES) – Finance code 001 and CNPq (159961/2018-1).

REFERENCES

1. Zaleckiene V, Peciuliene V, Brukiene V, Drukteinis S. Traumatic dental injuries: etiology, prevalence and possible outcomes. Stomatologija, 2014; 16(1), 7-14.

2. Soares JP, Barasuol JC, Torres FM, Giacomin A, Gonçalves BM, Klein D, et al. The impact of crown fracture in the permanent dentition on children's quality of life. Dent Traumatol. 2018; 34(3):158–163.

3. Magno MB, Jural LA, Nogueira ADV, Lenzi MM, Pithon MM, Maia LC. Impact of crown fracture treatment on oral health-related quality of life of children, adolescents, and their families: A prospective clinical study. Int J Paediatr Dent. 2019; 29(1):86–93.

4. Bastone EB, Freer TJ, McNamara JR. Epidemiology of dental trauma: A review of the literature. Aust Dent J, 2000; 45(1):2-9.

5. Patel M, Sujan S. The prevalence of traumatic dental injuries to permanent anterior teeth and its relation with predisposing risk factors among 813 years school children of Vadodara city: An epidemiological study. Journal of Indian Society of Pedodontics and Preventive Dentistry, 2012; 30(2):151.

6. Joiner A. Tooth colour: a review of the literature. Journal of dentistry, 2004; 32:3-12.

7. Bello A, Jarvis RH. A review of esthetic alternatives for the restoration of anterior teeth. J Prosthet Dent, 1997; 78:437-40.

8. Patil PG, Nimbalkar-Patil SP, Karandikar A.B. Multidisciplinary treatment approach to restore deep horizontally fractured maxillary central incisor. J Contemp Dent Pract, 2014; 15(1):112-115.

9. Diangelis AJ, Andreasen JO, Ebeleseder KA, Kenny DJ, Trope M, Sigurdsson A, et al. Guidelines for the Management of Traumatic Dental Injuries: 1. Fractures and Luxations of Permanent Teeth. International Association of Dental Traumatology, 2013; 36(6):317-327.

10. Cortes MIS, Marcenes W, Sheiham A. Impact of traumatic injuries to the permanent teeth on the oral health related quality of life in 12-14-year old children. Community Dent Oral Epidemiol, 2002; 30(3):193-198.

11. Francisconi LF, Freitas MCCA, Oltramari-Navarro PVP, Lopes LG, Francisconi PAS, Mondelli RFL. Multidisciplinary approach to the establishment and maintenance of an esthetic smile. Quintessence International 2012; 43:853-858.

12. Soares TRC, Luiz RR, Risso PA, Maia LC. Healing complications of traumatized permanent teeth in pediatric patients: a longitudinal study. International Journal of Paediatric Dentistry, 2014; 24:380–386.

13. Velo MMDAC, Coelho LVBF, Basting RT, Amaral FLBD, França FMG. Longevity of restorations in direct composite resin: Literature review. RGO-Revista Gaúcha de Odontologia, 2016; 64(3), 320-326.14 – Mjör IA, Moorhead JE, Dahl JE. Reasons for replacement of restorations in permanent teeth in general dental practice. International dental journal, 2000; 50(6), 361-366.