THE FUNCTIONAL ARCHITECTURE OF THE STOMATOGNATHIC SYSTEM AND OROFACIAL AESTHETIC REPOSITIONING DURING THE AGING PROCESS

Marvin do **Nascimento**[1]*, Caroline Grijó e **Silva**[1], João Victor França **Moura**[1], Bruno dos Santos **Fausto**[2], Andrea Damas **Tedesco**[1]

[1] Department of Dentistry Clinic, Dental School of the Federal University of Rio de Janeiro, Rio de Janeiro, RJ, Brazil.
[2] School of Fine Arts, Federal University of Rio de Janeiro, Rio de Janeiro, RJ, Brazil.

Palavras-chave: Envelhecimento. Envelhecimento da Pele. Preenchedores Dérmicos. Sistema Estomatognático.

RESUMO

Introdução: O envelhecimento facial implica em cuidados especiais e um tratamento diferenciado. Desse modo, a nova vertente da Odontologia Neo moderna busca, por meio da Harmonização Orofacial, o equilíbrio funcional e estético entre o aparelho estomatognático e a face. **Objetivo:** Esse artigo busca compreender, por meio de uma revisão de literatura, as consequências estéticas do reposicionamento do aparelho estomatognático e envelhecimento orofacial. **Fonte dos dados:** A presente revisão de literatura consistiu em um viés qualitativo nas plataformas PubMed e Google Acadêmico, nos ultimos 10 anos, sem restrição de idiomas. Os critérios de inclusão consistiram em estudos clínicos, livros, dissertações, teses ou revisões de literatura que abordavam os tópicos de interesse. **Síntese dos dados:** Foram recuperados nas bases de dados 231 artigos. Após a aplicação de um limite de publicação de 10 anos, 111 permaneceram e, com base nos critérios de inclusão e exclusão, 20 artigos foram selecionados e incluídos nesta revisão. **Conclusão:** Com as limitações do presente estudo, pode-se concluir que o processo de envelhecimento é natural e previsível e pode ser mutável e maleável por meio de procedimentos que restauram os nutrientes de suporte perdidos. A estética pode ser alcançada como uma consequência funcional do reposicionamento do sistema estomatognático e do envelhecimento orofacial.

Keywords: Aging. Skin Aging. Dermal Fillers. Stomatognathic System.

ABSTRACT

Introduction: Facial aging implies special care and personalized treatment. Thus, the new strand of Neomodern Dentistry seeks, through Orofacial Harmonization, the functional and aesthetic balance between the stomatognathic system and the facial aspect. **Objective**: This article seeks to disclose, through a literature review, the aesthetical consequences of the stomatognatic system repositioning and orofacial aging. **Data source**: The present literature review consisted in researches up to May 2019 using PubMed and Google Academic electronic databases. A 10-year publication limit was applied in the research. No language restriction was applied. Inclusion criteria were clinical investigations, books, dissertations, thesis or literature reviews that addressed the topics of interest. **Data synthesis**: A total of 231 articles were retrieved from databases. After applying a 10-year publication limit, 111 remained and, based on the inclusion and exclusion criteria, 20 articles were selected and included in this review. **Conclusion**: Considering the limitations of the present study, it can be concluded that the aging process is natural and predictable and can be changeable and malleable through procedures that restore the support nutrients that were lost. The aesthetics can be achieved as a functional consequence of the stomatognathic system repositioning due to orofacial aging.

Submitted: January 7, 2020
Modification: March 30, 2020
Accepted: May 14, 2020

***Correspondence to:**
Marcus Vinícius Manhães Ribeiro do Nascimento
Address: Rua Professor Rodolpho Paulo Rocco, 325 - Ilha do Fundão, Rio de Janeiro, RJ, Brazil. Zip Code: 21941-971
Telephone number: +55 (21) 96642-8431
E-mail: mvnascimento@hotmail.com.br

INTRODUCTION

Neomodern dentistry is under a new face, surpassing all restored paradigms by restructuring functionally the Stomatognathic System (SS) in facial aging. Thus, the search for functional and aesthetic restoration is directly qualified with the individual's self-estem. Therefore, the procedures or intervals of interaction have as one of their goals, to rehabilitate the functions included in oral motor skills.

The SS is presented as a functional organs and tissues complex of orofacial structures, that with participation of the jaw, defines usual functionalities. The composition of the SS comprises: Temporomandibular Joint (TMJ); facial neuromuscular component; periodontal ligament; dental surfaces and occlusion.[1]

The submission to the aging supply provides in intrinsic and extrinsic ways, important factors that alter the orofacial homeostasis, and therefore, the anatomophysiological modifications from aging significantly affects the structuring of the SS.[2]

Orofacial harmonization has as its purpose the patient's demand, which is established by functional therapies with aesthetic and cosmetic consequences applied to the SS that goes beyond isolated smile components. The biggest acquisition is based on health, functional stability, aesthetics, youthfulness, harmony and well-being.[3] Thinking about this aspect, this article seeks to understand and present the aesthetic consequences of the functional repositioning of the stomatognathic system.

Study design

Electronic searches up to May 2019 were conducted using PubMed and Google Academic electronic databases. The descriptors "aging", "skin aging", "dermal fillers", "stomatognathic system", limited to the title and abstracts fields. A 10-year publication limit was applied in the search. No language restriction was applied. Inclusion criteria were clinical investigations, books, dissertations, theses or literature reviews that addressed the use of orofacial harmonization showing their main indication, techniques used and facial components, skin aging and stomatognathic system. Factors such as age, follow-up time, interventions, trauma and craniofacial deformities, among other variables, were not considered, since the purpose of this review is not to follow up in stages of the aging process in different clinical conditions, but to demonstrate the functional and aesthetic differences of the stomatognathic system and orofacial aging.

SYNTHESIS OF DATA

Initially, 159 and 72 references were retrieved from PubMed and Google Academic, respectively. After the application of a 10-year publication limit, 84 and 27 remained, and based on the inclusion and exclusion criteria, 20 papers were selected and included in this review.

SUMMARY OF THE FINDINGS

Main characteristics of the selected studies regarding the stomatognatic system and orofacial aging (Table 1).

Stomatognathic System Aging Process

The SS is composed of sensory functions that represent the overall oral sensation, and motor functions that are characterized by oral activity with mandibular cooperation.[1]

Motor functions are responsible for oral motor skills, which the main one is the mandibular posture. However, it can be further divided into two groups of dynamic functions: classical (chewing, sucking, swallowing, speech articulation, speech-singing and mouth breathing) and adaptive (yawning, kissing, bite, facies, mimic, vocalization, spitting, blowing, laughing). Sensitive functions deal only with oral sensitivity.[2]

When thinking about the structural constitution, the SS can be divided into: static structures and dynamic structures. Static structures are related to any articular bone structure composed of supporting organs and tissues, represented by the elements: bones (jaw, hyoid, maxilla, cranial base, and cervical spine), TMJ (temporomandibular joint), teeth (occlusal area, periodontium), tendons (aponeuroses and ligaments). The dynamic structures, on the other hand, are composed by: nerves (motor and sensory) and muscles.[2,6]

The aging process affects the stomatognathic system just as linearly as it affects the rest of the body. In the neuromuscular system, there is a progressive decrease in the nerve plexuses that innervate the muscles, increasing the time of muscle response. The aging of the neuromuscular system becomes visible due to decreased activity of the chewing muscles.[1,2,3] As a result, the insufficiency of stomatognathic musculature is directly linked to the formation of static facial wrinkles, since the neuromuscular portion is closely linked to bone, connective tissue and skin.[3] In bone structures, less osteoblastic activity will occur in parallel with the osteoclastic action, leading to bone absorption, with consequent atrophy of specific parts of the maxilla and jaw[3,2] and enlargement of the orbital and piriform cavities.

Facial Squareness

The structural presentation of the face during youth is identified as a triangle, with the base facing upwards, characterizing a thin and defined youthful face, following the proportions of beauty described in the literature (Figure 1).

***Table 1**: Summary of research on stomatognathic system and orofacial aging*

	Muscle and Fat	Bone	Skin	References
Young face	Has a thick layer of submuscular adipose tissue	Presence of bone support and regular osteoblastic and osteoclastic activity	More prominent contours, more marked surface, and more projected curve lines	**Coimbra et al., 2014[7] Gitirana et al., 2013[8]**
	Facial muscles have the specific function of transferring each contractile movement to the adjacent tissue	Cranial-facial growth, increased face height and increased mandibular length	Increased thickness of the epidermis and dermis for better tension of collagen fibers	**Albert et al., 2007[12] Mendelson & Wong, 2012[18] Couto, 2007[29]**
	While facial fat does not exist as a homogeneous object on the face, it is a set of dynamic compartments that can be evaluated, increased and modified	Occurs or continuously expands facial bones, this does not progressively increase certain facial anthropometric measures with age, such as a nasal spine from the nose to an anterior region and a facial width	Cutaneous stiffness due to white subcutaneous tissue paper and a network of collagen fibers	**Fitzgerald & Rubin, 2014[15] Wollina et al., 2017[17]**
	Facial muscles play a great role in imitation and facial expression, important for facial aesthetics and human communication	Cranifacial growth with regular osteocyte activity. Bone tissue acting with good bone base for support and support	A dermis has a structural support of collagen fibers and provides skin resistance and elasticity. This keeps the skin cleaner, more resistant to mechanical changes	**Douglas, 1994[2] Madeira, 2004[30] Guirro and Guirro, 2004[31] Sovinski, 2012[32]**

	Progressive decrease in the muscles tone, displacement of fat portions and the increase of skin causing flaccid aspect	Less osteoblastic activity will occur in parallel with the osteoclastic action, leading to bone absorption	The convex facial features become straighter, increasing facial ptosis	**Manavpreet et al., 2015[9]** **Coleman et al., 2006[10]**
	There is loss of strength and muscle tone due to the decrease in volume, consistency and speed at which muscle tension can be developed and released	Bone formation activity decreases in relation to resorption. Thus, the jaws and jaw undergo atrophy due to disuse	Premature aging due to UV exposure. Degradation and delay in the collagen fibers production	**Fisher et al., 2002[4]** **Freitas Junior et al., 2008[3]** **Shaw et al., 2011[19]**
Old Face	Increased muscle bonus, shorter range of motion, and resting muscle bonus is closer to the maximum hiring bonus. Some superficial fat compartments undergo hypertrophy during aging of	Glabella protrusion, lateral translation of the orbits, expansion of supraorbital, increased depth of the cheeks, increase in the length, width and vertical dimensions of the nose; and increased vertical height in the occlusal region associated with increased chin prominence	Fall of the upper eyelid, appearance of nasolabial lines, lateral lines in the nose, mouth and orbit, reduction of the lip thickness and length of the nose and chin, concealed appearance of the cheeks, protrusion of the nose and ears caused by craniofacial convexity	**Cotofana et al., 2016[14]** **Sadick et al., 2015[16]**
	Limitation of facial expressions, repetitive muscle contractures resulting in a change in fat and, therefore, accentuation of furrows and wrinkles, with a transformation of dynamic facial lines into static facial lines	Craniofacial and alveolar remodeling progresses, increased mandibular length	Decreased skin thickness and tissue repair processes	**Porto, 2008[11]** **Horizonte, 2012[27]**



***Figure 1**: Face during youth represented by a triangle, with the base facing upwards, characterizing a thin and defined young face. Stomatognatic tissues naturally well positioned.*

With the fundamental modification of the established aging process, this triangle is reversed due to loss of volume and definitions of facial angles and gravitational tissue ptosis as previously discussed.[7]

The face is divided into three parts that seek the regularization of homeostasis and facial symmetry, namely:
- Upper third: extends from the hair insertion line (trichium point) to the glabella,
- Middle third: from the glabella to the subnasal point and,
- Lower third: from the subnasal point to the chin.

The most noticeable changes during aging of the upper third of the face are due to chronic sun exposure, facial mimic muscle contracture throughout life and its domains under the epidermis and dermis with loss of tissue elasticity.[7,8] These factors, when associated with the action of gravity and constant periorbital contracture, lead to decreased visual amplitude with advancing age.[9] According to Sadick et al, the appearance of tired eyelid occurs due to excess skin that generates a skin fold as a result of the loss of elasticity associated with advancing age. The appearance of frontal ptosis occurs due to the loss of stability of the upper eyelid and the temporal support of the lateral portion of the eyebrow.[10] The appearance of periorbital wrinkles and the darkened pigmentation of this region occur as a result of infraorbital subcutaneous tissue aging and melanocyte activity in the dermis.[9]

In the middle third of the face, changes in endogenous factors such as decreased production of fibroblasts in the dermis, loss of stiffness, increased flabbiness and osteocytic and chondrocytic changes are observed intensely.[7,8] Aging leads to decreased fat replacement, which results in a smaller volume of fat pads, giving the appearance of empty cheeks.[10] Changes in adipose tissue in the oropharyngofacial region may also dimensionally affect the zygomatic bone region. A nasolabial fold develops due to weakening of the supporting ligaments that hold tissues to the zygomatic bone.[9] The chronological reduction of adipose tissue leads to weakening of the orbital septum, which suggests a protrusion of the lower or upper eyelid, the first located in the middle third, while the second in the upper third. However, there may still be sinking traces of the eyelid region, which indicates depletion of the eyelid hypodermis.[7] The aging of the nose follows the same characteristics as the other parts of the middle third, presenting less muscle and ligament tension. Supporting structures may become inelastic resulting in loss of definition of the back and tip. Nasal cartilage, as well as the ear, increases in volume over time. Associated with the bony opening of the piriform cavity, there is a fall of the nose and, consequently, stretching of the middle facial third. Therefore, in addition to supporting tissues, bone and cartilage elements also have an effect on age, with irregularities of the most visible bone and cartilage portions.[11]

In the lower third, changes occur mainly due to

neuromuscular structures associated with oropharyngofacial facies, such as changes related to connective tissue related to loss of subcutaneous fat and type III collagen fibers. These changes generate a greater appearance of sagging skin, also due to the lack of support due to the remodeling of bone and cartilage structures that occur with aging.[7,8] Repeated contraction of the orbicularis muscle of the lips throughout life, loss of fat in this region and reduction of the dermal components, vertical wrinkles form on the cutaneous portion of the lips, known as barcodes. With aging, from adolescence to old age, the vermilion of the lips is affected by an average narrowing of 3.6mm. The clinical aspect of lip length increases significantly by 1.4mm between 40 and 50 years of age.[12] The anterior portion of the mandible protrudes, becomes thinner and rotates in axial rotation. And yet, there is three-dimensional loss of the entire middle facial third structure due to resorption of the sustaining periodontium.[8,9] As a structural component of the integumentary system, the skin and its appendages present a set of different histological tissues, which are organized harmoniously to adjust the integument in its primary functions.

The skin consists of epidermis that originates from the skin ectoderm, formed by a lining epithelium; and dermis, formed by attached connective tissue, originating from the mesoderm. Just below is the hypodermis, tissue not considered as a constituent structure of the skin by histologists, but a connective tissue whose function is to connect the integument to the adjunct structures. However, pathologists classify the hypodermis as the deepest subcutaneous layer of the skin, which, in anatomical view, will be recognized as superficial fascia.[8]

The composition of the epidermis has different cell types, such as keratinocytes, melanocytes, Langerhans cells, and Merkel cells. Keratinocytes are the main morphological species, constituting approximately 95% of the cellular composition and function linked to keratin production. Histologically, the epidermis is organized into: basal layer, spiny layer, granular layer, lucid layer and corneal layer.[12,13]

The epidermis has variable thickness and can be classified into thin skin when it has high keratinization; and thick skin when little keratinized. This division refers not only to the consistency of the skin, but also to the histological characteristics of the epidermis.[8]

In young skin, epidermal ridges, which are projections of epidermal tissue into the dermis, are responsible for the interactions between these two tissues. In the dermis, these projections are surrounded by loose connective tissue present in the most superficial layer of the dermis called papillary dermis. Epidermal ridges aim to increase nutrient availability by increasing the epidermis-dermis contact area, since the epidermis is an avascular structure and depends on nutrition from the dermis.[8,9]

Among with aging process, this epidermis-dermis interaction becomes weakened by shrinkage of the dermal papillae, which eventually reduces the contact area. As a result, the integument becomes more fragile and susceptible to exposure to injurious trauma. The cutaneous proliferative mitotic activity of the epidermis is conserved. Thus, the keratin corneal layer that structures the epithelial layer remains stabilized. The epidermis has a cellular refresh rate that happens approximately 20 to 30 days. The literature shows that the rate of epidermal renewal drops over time at a rate of 30% from 30 years and 50% at 80 years, changing epithelial thickness, specifically the spinous layer.[9,13]

The composition of the dermis can be classified into: papillary dermis and reticular dermis. The papillary dermis is in direct contact with the epidermis, and is basically composed of loose connective tissue. The reticular dermis consists of dense unmodified connective tissue, consisting primarily of collagen and elastin fibers. Richly composed of glycosaminoglycans (GAGs), the fundamental substance of the dermis, structures formed by linear polymer disaccharide units, which repeat continuously in a long chain structure, basically made up of a hexosamine (N-acetylglycosamine or N-acetylgalactosamine) linked to a uronic acid.[8,14]

Over the course of aging, the skin becomes whitish due to morphofunctional changes. There is less vasculocapillary tone directly influencing the homeostatic thermoregulation, and consequently, a lower tissue oxygenation, which ends up generating a small nutritive contribution and, consequently, the reduction of tissue hydration. There is a lower extracellular matrix (ECM) constitution, and as a result the decrease in collagen fibers productivity due to the lower fibroblastic production that is directly associated with sagging and cutaneous atrophy. There is also a reduction in the synthesis of GAGs that can lead to inconstant levels of deep dehydration.[9,13,14]

A skeletal facial aspect occurs due to the loss of

dimension of the adipose tissue involving the subcutaneous lining of the face, making the facial grooves more evident, which added to the flaccidity of the hypodermis directly affect the contours of the face. The stomatognathic muscle group during youth can affect the grooves and cranial bone projections, together with the composition of subcutaneous and adipose tissue. And they are also responsible for the structuring of harmonically positioned facial segments.[9]

Facial Muscles Action Associated with Submuscular Fat Compartments

At a young age, the face has more prominent contours, more marked surface, and more projected curve lines. This aspect is directly associated with the submuscular adipose layer that acts as an efficient surface contact for the facial muscles sliding. With the aging process, the convex facial features become straighter, the range of muscle action is increased, and the submuscular adipose tissue layer decreases, increasing facial pstosis.[7]

The frontal musculature, in its upper third, has a thick layer of submuscular adipose tissue. However, a centric extended bone deflation with superior and inferior rounding occurs throughout life. This occurs due contractive forces and muscle pressure acting under the functional center region. In the glabellar portion, due to the great depressing action of the corrugator supercilii and procerus, important changes occur, contributing to the disposition of the tiredness and discontent aspect. Therefore, the displacement of fat portions in the eyelid region and the increase of skin causes flaccid aspect to this region.[7,15]

In the ocular area, the muscles around the eyes, the orbicularis, are directly indicated by the aging effect of the face, causing protrusive repositioning of the orbicular fat segments, resulting in the fall of the final portion of the eyebrow and generating eyelid fat fragments, favoring the appearance of periocular rhytids and greater chances of cutaneous ptosis in the eyelid region. The result of repetition of the contraction of the corrugator supercilii muscle segregates deep fat fragments, which ultimately wear suggesting orbital bone.[15,16]

The movements of the major and minor zygomatic muscles disperse the submuscular adipocyte layer of the lower region, generating a jugal sphere deflation. The mimic muscles have repeated and combined contractures in the periorbital and peribucal sections, which in addition to expelling the adipocyte fragments, also generate great pressure on the underlying bone. With this, the appearance of perioral rhytids occurs, along with the volume and lip contour loss.[17]

In the depressor angulli oris muscle, along with the elevation made by the mentalis muscles, fat is expelled from the submuscular layer towards the upper middle cervical region, which eventually increases the excess of skin. With the aging process there is also an increase in the resting tone of the depressor angulli oris muscle, which deeps the labio-mental crease and increase the commissure depression.[7,15]

Facial Bone Remodeling

Facial bone loss interferes in the facial soft tissues. These are chronological changes that produce glabellar protrusion, lateral orbit translation, depth increase, lateral cheek expansion, three-dimensional enlargement of the nose and chin. There is prominence of the medial orbital fat pad, also associated with resorption of the upper edge of the orbital bone.[18]

Severe soft tissue changes associated with the aging process affect the middle zygomatic section. The maxilla is the structure that presents greater reconfiguration in aging, and it can be observed by the emptying of the cheek. The loss of the maxillary projection generates a tissue decrease in the nose and upper lip support, contributing to the increase of the piriform opening, and consequently causing the ptosis of the centrofacial region and stretching of the nose to the upper lip. There is also progression of deformity advancement of tear-trough lines, nasolabial fold, zygomatic fat, and is most often chronologically characteristic due to fat reduction or ptosis.[19]

In the lower facial third, due to aging, the vertical maxillary decrease influences the dental and skeletal structures, decreases the exposure of the superanterior teeth, directly interfering with the smile.[7]

OROFACIAL HARMONIZATION PROCEDURES

In order to promote the balance of the stomatognathic system, symmetry of the face as well as issues associated with system functions such as pain, masticatory dysfunction, also soften aging and improve quality of life, materials have been developed that can be applied both intra oral and extra oral areas (Table 2).[20]

***Table 2**: Main Orofacial Harmonization procedures*

Procedures	Orofacial Indications	References
Botulinum toxin	Produced by the bacterium *Clostridium botulinum*, it has seven serotypes called A-G that will be used to correct cases of bruxism, masseter hypertrophy, sialorrhea, smile asymmetry, accentuated gingival exposure and temporomandibular dysfunctions for safe application on head and neck structures. Aesthetic changes caused by senescence, such as wrinkles, are largely counteracted by treatment with botulinum toxin.	**Martins et al., 2016**[21] **Tamura, 2010**[38] **Tamura, 2010**[39] **Jabbari, 2016**[41]
Wire lift	Wire lift is a modern and minimally invasive approach, effective and durable compared to other materials. They induce collagen formation in the body promoting the treatment of sagging skin, wrinkles, as well as facial lifting. Thus they are indicated for treatments aimed at facial rejuvenation in order to reduce the effects of skin aging.	**Wan et al., 2019**[22] **Tavares et al., 2020**[49] **Obourn et al., 2018**[50] **Suh et al., 2015**[51]
Bichectomy	The surgery to remove part of the buccal fat pad or Bichat's fat pad, called bichectomy surgery, may contribute to orofacial harmonization. Performed for both aesthetic and functional purposes, it is indicated for individuals who present excessive volume of the buccal adipose body and want a better facial contour, besides enabling correction of masticatory defects. On the other hand, older people with an advanced elastosis process and who have a tapered face, this procedure is not indicated.	**Faria et al., 2018**[23] **Moura et al., 2018**[45] **Bernal Rodriguez et al., 2018**[46] **Storrer et al., 2019**[44]
Polycaprolactone	Polycaprolactone is a biomaterial considered bioabsorbable polymer. Extremely versatile, it can be used in applications directly on epidermal, muscle, bone and also cartilage tissues. Its use does not requires the collection of autogenous and allogeneic materials, promotes a shorter clinical treatment time and less formation of inflammatory processes and discomforts. It is degraded by a process that will result in the release of carboxylic acid occurring hydrolysis and cleavage of ester groups.	**Almeida, 2018**[28] **Jeong et al., 2019**[57] **Kwon et al., 2019**[58] **Kim., 2019**[59]

DISCUSSION

The aging process is subjective and depends on some variables. Older people may have more aging traits than younger, and the reverse is also true. According to Douglas,[2] there are two moments for the aging process: anatomophysiological development and its involution. Some factors contribute to this, namely: radiation, smoking, diet and stress. Couto[29] reports that during aging there is a reduction in thickness in the epidermis and a decrease in dermal space, compared to a young or intermediate group. In Freitas Junior[3] studies the aging is a multifactorial phenomenon and can be explained by genetics (chronological aspect of genetic mechanisms) and environment (random limiting factors that reduce adaptive capacity). Fisher[4] believed that the orofacial aging process occurs due to endogenous and exogenous consequences. Endogenous mechanisms are basically characterized by congenital and cumulative factors, that is, changes in natural cellular levels linked to physiological aging, such as the formation of superficial wrinkles and skin atrophy. On the other hand, the cumulative exogenous aging system is assisted by exposure to external environmental, physical and chemical conditions, which gradually accelerate aging. The main agents responsible for exogenous aging are ultraviolet radiation and smoking, which can cause deep wrinkles on the face, decreased dermal hydration, skin staining, and increased stratum corneum. Changes in fibrous elements and fundamental substances also occur with the aging process. The fibrous elements undergo alterations in the collagen system with a lower production of type I and type III collagenous fibers, the main constituent fibers of the dermis. With this, the skin takes on a more wrinkled and slender appearance. In the elastic system, there is less synthesis of elastic fibers leading to a greater aspect of sagging. There is also progressive loss of fundamental substances such as glycosaminoglycans (GAG), the main one being hyaluronic acid, resulting in less dermal hydration.[4,8,29] The visual modification of the face to the detriment of aging occurs through the formation of 3 types of wrinkles.

- Dynamic wrinkles: these are lines of expression that appear during facial mimes and disappear at rest. They are related to facial mimic.

- Static wrinkles: they are formed by the inertia of movements related to muscle fatigue, resulting from facial expressions during the individual's life. Presenting on the skin even at rest.

- Gravitational Wrinkles: these are folds formed by ptosis that occurs in all facial support tissue such as the skin and fatty pads.[30,31,32]

In this way, the effects of the aging process applied to the SS and the orofacial region may have a minimally invasive intervention, the orofacial harmonization procedures, which seek to propose a new tissue repositioning of the structures that were affected by aging, maintaining the functional and having aesthetics consequences. The facial mimic muscles contractions cause depressions in the form of lines or perpendicular pits to the fibers, which eventually turn into wrinkles, also called ridges or folds. The movements repetition during stomatognathic functions causes the appearance of these expression marks (Figure 2).[29,30,33]

In addition, the bone structure of the face has areas of resorption, which has its morphology altered over time. The orbit, for example, has resorption areas in the lower left third of the orbital floor. In this context, there is resorption of this area causing loss of muscle support, decreasing the tone of this muscle. Fillers, such as hyaluronic acid, can be used to reset this volume, and fill spaces caused by the loss of collagen structure. In addition, they can be used for facial contouring by reshaping the damaged structures to return a favorable aesthetic alignment to the face.[34,35] Hyaluronic acid filling is classified as a safe procedure, showing signs of inflammation as mild and moderate severity effects, which usually last for a week. [36,37] Fillers are indicated when it is too late to use botulinum toxin, which is the case with static wrinkles. They will improve the structure, which, as a result of loss of lift, becomes flabby. Grooves that are formed across the face throughout the aging process can be filled with hyaluronic acid to regain the volume of the area. An example is dark circles, which tend to deepen and move lower, giving an air of tiredness. This region forms the nasojugal groove, known as the tear trough, which extends from the medial corner of the orbit. The buccinator muscle region around the lips can be completed to eliminate the so-called "barcode" that comprises the region of the upper lip lines.[34,38,39] Botulinum toxin, on the other hand, can be used preventively in the dynamic wrinkle.[40] It can be applied to correct the horizontal forehead lines, on the upper part of the face, which has the effect of raising the eyebrows. It can also be used to correct the glabellar frown lines between the eyebrows. Not only is it used to correct marionette and periorbital lines.[21,41,42] The marionette groove is caused by congenital and external factors. It is the result of continued use of the mouth angle depressor muscle, which originates from the anterior region of the oblique line of the jaw and fits into the angle of the mouth. Being responsible for pain and suffering expressions, its overuse leads to a scar that causes a depressing appearence to the mouth comissure (Figure 3).[34,43,44]

In addition, the dermis components reduction and disorganization caused by the aging process contribute to

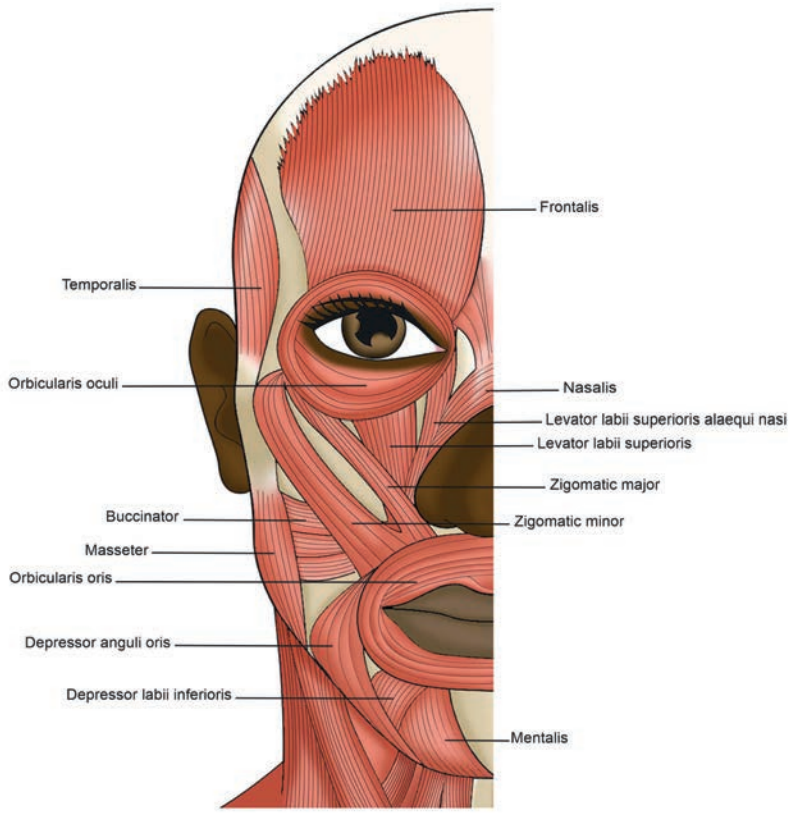

***Figure 2**: The shape of muscle lines in opposite direction of facial wrinkles. The contraction of the orofacial musculature associated to the factors that lead to the aging process, generates these facial grooves, marks and wrinkles. This is associated with bone remodeling, fat loss and skin thickness, which contributes to the facial squaring process.*

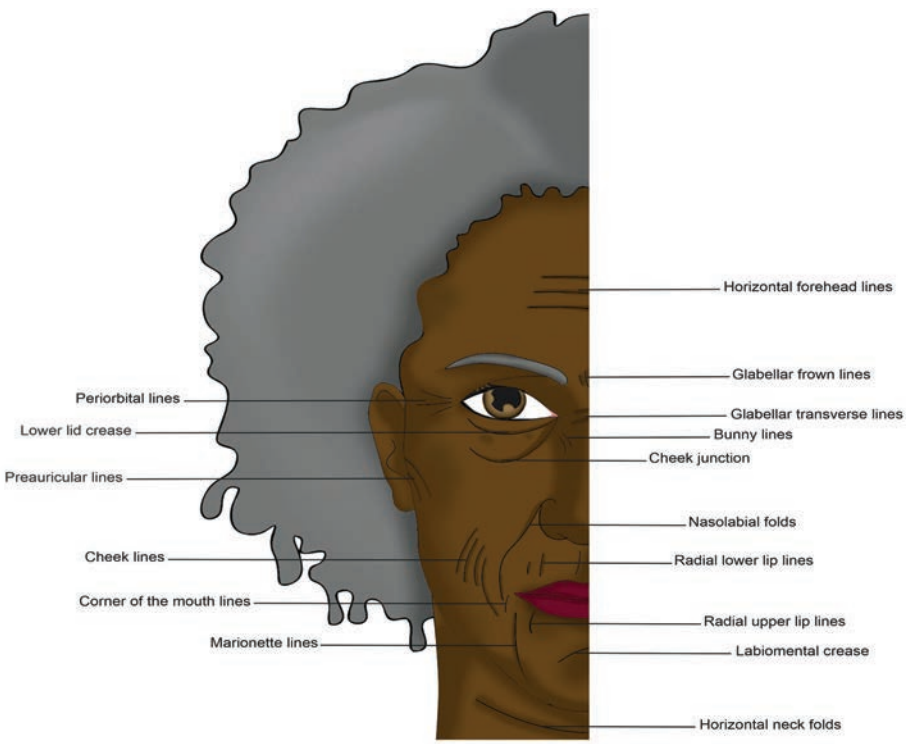

***Figure 3**: Major facial wrinkles caused by the aging process. The aging process is uniquely interpreted by each patient. They can have different representations and aesthetic intervention may not be required. Thus, the procedures have to be outlined as a functional repositioning that has the aesthetic as a consequence.*

the evolution of this deformity. The production of components that are essential for a youthful appearance, such as collagen and elastic fibers, decrease over time. Just as fat and bones are reabsorbing and muscles are losing their support strenght. In this context, injection of botulinum toxin type A into the depressor muscle of the mouth is indicated for this sign treatment. Bae GY[40] conducted a study in Korea of 16 cases in which botulinum toxin type A injections associated with hyaluronic acid were applied to treat marionette groove. In this study, out of the sixteen patients, none were dissatisfied and only four had collateral effects such as speak difficulty, playing instruments and lip herpes.[40] The bichectomy can help to provide a thinner aspect of the face, similar to an inverted triangle and more common in female faces. There are two approaches to achieve this thin aspect: intra oral incisions removing partially or entirely the buccal fat and the ones associated with facial lifting procedures. The first one is considered safer, however, there's no significant differences between both procedures related to complications in literature.[45,46,47] The repositioning of the fallen facial third should take into account the individuals yearnings, who needs to be carefully listened in order to understand what he wants to be restored. The individual's perspective on his own aging and the extent which they accept and wishes to change it is unique and variable. It is up to the professional to seek and identify which elements generate distress to the patient, combining what is spoken with the scientific knowledge about the anatomical structures involved. Cabral et al[48] describe that it is indispensable for the dentist surgeon to be sensitive to understand what really matters to the patient, since the origin of the disharmony can be very personal.

CONCLUSION

Considering the limitations of the present study, it can be concluded that the aging process is natural and predictable and can be changeable and malleable through procedures that restore the support nutrients that are lost. The aesthetics can be achieved as a functional consequence of the stomatognathic system repositioning due to orofacial aging. The art of harmonization is part of this process, making it lighter and more beautiful, and bringing well-being to the individual. A new Neomodern Dentistry philosophy is created, giving a positive perspective to those who pass through the aging process, which should not be feared but manipulated. Orofacial Harmonization becomes not only a hope of recovering what has been lost, but a prevention to keep what is feared to lose. It is, then, a strand that seeks to promote greater facial understanding, highlighting the smile, as one of the most amazing and unforgettable facies of the human being, and bringing life to the face which is part.

REFERENCES

1. Gedrange T, Kunert-Keil C, Heinemann F, Dominiak M. Tissue Engineering and Oral Rehabilitation in the Stomatognathic System. Biomed Res Int.; 2017 Jan. doi:10.1155/2017/4519568

2. Douglas CR. Tratado de Fisiologia Aplicada às Ciências da Saúde. 6ª ed., São Paulo: Robe Editorial. 1994.

3. Freitas Junior AC, Almeida EO, Antenucci RMF, Gallo AKG, Silva EMM. Envelhecimento do aparelho estomatognático: alterações fisiológicas e anatômicas. Revista Odontológica de Araçatuba. 2008 Jan/Jun 29: 1.

4. Fisher GJ, Kang S, Varani J, Bata-Csorgo Z, Wan Y, Datta S, et al. Mechanisms of Photoaging and Chronological Skin Aging. Arch Dermatol. 2002 138(11): 1462-1470. doi:10.1001/archderm.138.11.1462

5. Cavalcanti, NA, Azevedo, JF, Mathias, P. Harmonização Orofacial: A odontologia além do sorriso. Rev. Bahiana de Odontologia. 2017 8(2): 28-29. doi: 10.17267/2596-3368dentistry.v8i2.1454.

6. Messina G, Giustino V, Martines F, Rizzo S, Pirino A, Scoppa F. Orofacial muscles activity in children with swallowing dysfunction and removable functional appliances. Eur J Transl Myol. 2019 Aug 29(3):8267. doi:10.4081/ejtm.2019.8267

7. Coimbra DD, Uribe NC, Oliveira BS. "Quadralização facial" no processo do envelhecimento. Surgical & Cosmetic Dermatology, 2014 6(1): 65-71.

8. Gitirana LB. Coleção Conhecendo. Histologia dos tecidos. 1ª. ed. Rio de Janeiro: PUBLIT Soluções Editoriais, 2013. v. 1. 252p

9. Manavpreet K, Rakesh KG, Sanjeev S. Analysis of facial soft tissue changes with aging and their effects on facial morphology: A forensic perspective. Egyptian Journal of Forensic Sciences, 2015 5(2): 46-56. doi:10.1016/j.ejfs.2014.07.006

10. Coleman SR, Grover R. The Anatomy of the Aging Face: Volume Loss and Changes in 3-Dimensional Topography. Aesthetic Surgery Journal, 2006 Jan; 26(1): 4-9. doi:10.1016/j.asj.2005.09.012

11. Porto MJ. O nariz no envelhecimento: um estudo através de auto-retratos [dissertation]. Brasília (GO): Universidade Católica de Brasília, 2008.

12. Albert AM, Ricanek K, Petterson E. A review of the literature on the aging adult skull and face: implications for forensic science research and applications. Forensic Sci Int, 2007 172(1). doi: 10.1016/j.forsciint.2007.03.015

13. Tanikawa C, Takata S, Takano R, Yamanami H, Edlira Z, Takada K. Functional decline in facial expression generation in older women: A cross-sectional study using three-dimensional morphometry. PLoS One. 2019 jul 14(7). doi:10.1371/journal.pone.0219451

14. Cotofana S, Fratila AA, Schenck TL, Redka-Swoboda W, Zilinsky I, Pavicic T. The anatomy of the aging face: a review. Facial Plast Surg 2016 32 (3) 253-260. doi: 10.1055/s-0036-1582234

15. Fitzgerald and Rubin. Filler placement and the fatcompartments; Dermatol Clin, 2014 32: 37-50.

16. Sadick N, Dorizas A, Krueger N, Nassar A. The Facial Adipose System: Its Role in Facial Aging and Approaches to Volume Restoration. Dermatologic Surgery, 2015 41: 333–S339. doi:10.1097/DSS.0000000000000494

17. Wollina U, Wetzker R, Abdel-Naser MB, Kruglikov IL. Role of adipose tissue in facial aging. Clin Interv Aging. 2017 dec;12:2069–2076. doi:10.2147/CIA.S151599

18. Mendelson B, Wong CH. Changes in the facial skeleton with aging: implications and clinical applications in facial rejuvenation. Aesthetic Plast Surg. 2012; 36(4):753–760. doi:10.1007/s00266-012-9904-3

19. Shaw RB, Katzel EB, Koltz PF. Yaremchuk MJ, Girotto JA, Kahn DM, Langstein HN. Aging of the Facial Skeleton: Aesthetic Implications and Rejuvenation Strategies. Plast Reconstr Surg. 2011 jan;127:374–383. doi:10.1097/PRS.0b013e3181f95b2d

20. Papazian MF, da Silva LM, Crepaldi AA, Crepaldi MDLS, & de Aguiar AP. Principais aspectos dos preenchedores faciais. Revista Faipe. 2018 sep; 8(1): 101-116.

21. Martins RR, Silveira AMM, Raulino Neto JDS, Martins JCG, Pessoa CV. Toxina botulínica tipo A no tratamento de rugas: uma revisão de literatura. Centro Universitário Católica de Quixadá, 2016; 3(1).

22. Wan D, Dayan E & Rohrich RJ. Safety and Adjuncts in Face Lifting. Plastic and Reconstructive Surgery, 2019; 144(3), 471e-484e. doi: 10.1097/prs.0000000000005898

23. Faria CADC, Dias RCS, Campos AC, Daher JC, Costa RSC, & Barcelos LDP. Bichectomy and its contribution to facial harmony. Rev. Bras. Cir. Plást. 2018; 33(4): 446-452. doi:10.5935/2177-1235.2018RBCP 0164

24. Cruz ASLO. Harmonização orofacial com ácido hialurônico: vantagens e limitações [monography]. Governador Mangabeira (BA): Faculdade Maria Milza; 2018.

25. Vargas A, Amorim N & Pitanguy I. Complicações tardias dos preenchimentos permanentes. Revista Brasileira de Cirurgia Plástica. 2009 24(1): 71-81.

26. Machado Filho CDAS, dos Santos TC, Rodrigues APLJ & da Cunha MG. PolyLlactic acid: a biostimulating agent. Surgical & Cosmetic Dermatology. 2013 5(4): 345-350.

27. Horizonte, B. Desenvolvimento de um Compósito de Ácido Hialurônico de Fosfato de Cálcio Bifásico para Reparação de Estruturas Anatômicas Subdérmicas [dissertassion]. Belo Horizonte (MG): CEFET-MG; 2012.

28. Almeida CLD. Preparo e caracterização de esponjas à base de quitosana e policaprolactona (PCL) [monography]. João Pessoa (PB): Universidade Federal da Paraíba; 2018.

29. Couto JPA; Nicolau RA. Estudo do envelhecimento da Derme e Epiderme-Revisão Bibliografica. São José dos Campos (SP); 2007; 2035-2036.

30. Madeira MC. Anatomia da face: bases anaìtomofuncionais para a praìtica odontoloìgica. 4ª ed., São Paulo: Sarvier, 2004.

31. Guirro E, Guirro R. Fisioterapia dermato-funcional. São Paulo: Manole; 2004.

32. Sovinski SRP. Estética facial e funções orofaciais em indivíduos com deformidade dentofacial [dissertation]. Bauru (SP): Universidade de São Paulo; 2012. doi:10.11606/D.25.2012.tde-01112012-150142.

33. Oliveira AC, Anjos CAL, Silva EHAA, Menezes PL. Aspectos indicativos de envelhecimento facial precoce em respiradores orais adultos. r - ono evista de tualização Cient fica, Barueri S , 2007 Jul-Set; 19(3): 305-312.

34. Tamura BM. Facial topography of the injection areas for dermal fillers, and associated risks. Surg Cosmet Dermatol 2013; 5(3): 234238.

35. Pascali, M, Quarato D, Carinci F. Filling Procedures for Lip and Perioral Rejuvenation: A Systematic Review. Rejuvenation Research. 2018. doi:10.1089/rej.2017.1941

36. Percec I, Bertucci V, Solish N, Wagner T, Nogueira A, Mashburn J. An Objective, Quantitative, Dynamic Assessment of Hyaluronic Acid Fillers That Adapt to Facial Movement. Plast Reconstr Surg. 2020 Feb; 145(2):295-305. doi: 10.1097/PRS.0000000000006461

37. Moradi A, Allen S, Banco D, Marmur E, Fagien S, Glaser D A, et al. A Prospective, Multicenter, Randomized, Evaluator-Blinded, Split-Hand Study to Evaluate the Effectiveness and Safety of Large-Gel-Particle Hyaluronic Acid with Lidocaine for the Correction of Volume Deficits in the Dorsal Hand. Plast Reconstr Surg. 2019 144(4):586e–596e. doi:10.1097/PRS.0000000000006070

38. Tamura B. Facial anatomy and the application of fillers and botulinum toxin – Part I. Surg Cosmet Dermatol. 2010 2(3): 195-204.

39. Tamura B. Facial anatomy and the application of fillers and botulinum toxin – Part II. Surg Cosmet Dermatol. 2010 2(4): 291-303.

40. Bae GY, Na JI, Park KC, Cho SB. Nonsurgical correction of drooping mouth corners using monophasic hyaluronic acid and incobotulinumtoxinA. J Cosmet Dermatol. 2019; 00: 1-8. doi:10.1111/jocd.13010

41. Jabbari B. History of Botulinum Toxin Treatment in Movement Disorders. Tremor Other Hyperkinet Mov (N Y). 2016 nov 28 6:394. doi:10.7916/D81836S1

42. Herd CP, Tomlinson CL, Rick C, Scotton WJ, Edwards J, Ives N, et al. Botulinum toxins for the prevention of migraine in adults. Cochrane Database Syst Rev. 2018 jun 25 ;6(6):CD011616. doi:10.1002/14651858.CD011616.pub2

43. Rohrich Rod. Training the Generation X Plastic Surgeon: Dispelling the Myths?. Plastic and reconstructive surgery, 2001 108(6): 1733-1734. doi:10.1097/00006534-200111000-00047

44. Haddock NT, Saadeh PB, Boutros S, Thorne CH. The tear trough and lid/cheek junction: anatomy and implications for surgical correction. Plast Reconstr Surg. 2009 april; 123(4): 1332-1340. doi: 10.1097/PRS.0b013e31819f2b36

45. Moura LB, Spin JR, Spin-Neto R, Pereira-Filho VA. Buccal fat pad removal to improve facial aesthetics: an established technique?. Med Oral Patol Oral Cir Bucal. 2018 jul 1 ;23(4):e478–e484. doi:10.4317/medoral.22449

46. Bernal Rodriguez CG, Kraul LF, Cardoso TW, Eduardo CP, Aranha ACC, De Freitas PM. Photobiomodulation in the Postoperative of Bichectomy Surgeries: Case Series. Photomedicine and Laser Surgery, 2018; 36(7), 391–394. doi:10.1089/pho.2017.4407

47. Storrer CLM, Muller LL, Pissaia JF, Andrade CF, Trevisani CRT, Deliberador TM. Treatment of Miller Class I Gingival Recession with Using Nonpedicle Adipose Tissue after Bichectomy Surgical Technique: A Case Report. Case Rep Dent. 2019 dec:1049453. doi:10.1155/2019/1049453

48. Cabral L, Monteiro PAA, Ramires MA, Lima CP, Kunz PM. Visagismo: A Arte da Personalização do Sorriso. Revista Gestão & Saúde, 2017; 17(2): 62-72.

49. Tavares JP, Oliveira CACP, Torres RP, Bahmad JF. Rejuvenescimento facial com fios de sustentação. Braz. j. otorhinolaryngol. 2017 Dec; 83(6):712-719.

50. Obourn CA, Williams EF. A Decade of Thread-Lifting-What Have We Learned Over the Last 10 Years? JAMA Facial Plast Surg. 2018 20(5):349–350. doi:10.1001/jamafacial.2018.0737

51. Suh DH, Jang HW, Lee SJ, Lee WS, Ryu HJ. Outcomes of Polydioxanone Knotless Thread Lifting for Facial Rejuvenation. Dermatologic Surgery, 2015 41(6), 720-725. doi:10.1097/dss.0000000000000368

52. Oshihara W, Fujieda H, Ueno Y. A New Poly(Methyl Methacrylate) Membrane Dialyzer, NF, with Adsorptive and Antithrombotic Properties. Scientific Aspects of Dialysis Therapy, 2016 230-236. doi:10.1159/000450806

53. Behshad R. Commentary on Polymethylmethacrylate Collagen Gel Injectable Dermal Filler for Full Face Atrophic Acne Scar Correction. Dermatologic Surgery, 2019;45(12), 1567-1569. doi:10.1097/dss.0000000000001969

54. Molinero-Mourelle P, Canals S, Gómez-Polo M, Solá-Ruiz M, del Río Highsmith J, Viñuela A. Polylactic Acid as a Material for Three-Dimensional Printing of Provisional Restorations. The International Journal of Prosthodontics, 2018;31, 349–350. doi:10.11607/ijp.5709

55. Bass LS. Injectable Filler Techniques for Facial Rejuvenation, Volumization, and Augmentation. Facial Plastic Surgery Clinics of North America, 2015;23(4), 479–488. doi:10.1016/j.fsc.2015.07.004

56. de Almeida AT, Figueredo V, da Cunha ALG, Casabona G, Costa de Faria JR, Alves EV, et al. Consensus Recommendations for the Use of Hyperdiluted Calcium Hydroxyapatite (Radiesse) as a Face and Body Biostimulatory Agent. Plast Reconstr Surg Glob Open. 2019 mar 14;7(3):e2160. doi:10.1097/GOX.0000000000002160

57. Jeong GJ, Ahn GR, Park SJ, Hong JY, Kim BJ. A randomized, patient/evaluator blinded, split face study to compare the efficacy and safety of polycaprolactone and polynucleotide fillers in the correction of crow's feet The latest biostimulatory dermal filler for crow's feet. Journal of Cosmetic Dermatology. 2019. doi:10.1111/jocd.13199

58. Kwon T, Han SW, Yeo IK, Kim JH, Kim JM, Hong J, et al. Biostimulatory effects of polydioxanone, poly d, l lactic acid, and polycaprolactone fillers in mouse model. Journal of Cosmetic Dermatology. 2019. doi:10.1111/jocd.12950

59. Kim JS. Changes in Dermal Thickness in Biopsy Study of Histologic Findings After a Single Injection of Polycaprolactone-Based Filler into the Dermis. Aesthet Surg J. 2019;39(12):NP484–NP494. doi:10.1093/asj/sjz050