MIDPALATAL SUTURE MATURATION ASSESSMENT BY INDIVIDUALS WITH DIFFERENT LEVELS OF ACADEMIC DEGREE USING CONE BEAM COMPUTED TOMOGRAPHY

Taiane dos Santos **Lopes**[1], Cinthia de Oliveira **Lisboa**[1], Ilana Oliveira **Christovam**[2], Claudia Trindade **Mattos**[1*]

[1]Department of Orthodontics, School of Dentistry, Fluminense Federal University, Niterói, RJ, Brazil.
[2]Department of Orthodontics, University of Vassouras, Vassouras, RJ, Brazil.

Palavras-chave: Tomografia Computadorizada de Feixe Cônico. Palato Duro. Técnica de Expansão Paltina.

RESUMO

Objetivo: Avaliar a confiabilidade da classificação dos estágios de fusão da sutura palatina mediana em adolescentes do sexo feminino através de tomografia computadorizada cone beam (TCCB) por aluno da graduação em dois tempos (intraexaminador) e comparado a um ortodontista (interexaminador). **Métodos:** Foram selecionadas tomografias de 40 meninas na faixa etária de 14 a 19 anos feitas previamente ao tratamento ortodôntico. No *software* InVivo Dental 5.1 as imagens da cabeça foram orientadas de forma padronizada. Os cortes axiais desejados foram selecionados por um pesquisador ou por cada examinador e cada imagem resultante foi classificada quanto ao estágio de fusão da sutura palatina mediana. Os operadores realizaram todas as classificações duas vezes com intervalo de duas semanas entre as sessões, cada um individualmente. O coeficiente kappa ponderado de acordo com Landis e Kock foi utilizado para avaliar a concordância intraexaminador e interexaminador. **Resultados:** O kappa intraexaminador do aluno da graduação foi de 0,824 pra cortes pré-selecionados e 0,692 para os orientados por ele mesmo, e do ortodontista foi de 0,919 e 0,695, respectivamente. O coeficente kappa entre eles foi 0,479 e 0,300. **Conclusão:** Apesar do aluno de graduação ser mais inexperiente, sua concordância intraexaminador foi muito boa, semelhante à do ortodontista. No entanto, a concordância entre eles não foi boa, demonstrando necessidade de aprimoramento no treinamento do método.

Keywords: Cone-Beam Computed Tomography. Hard Palate. Palatal Expansion Technique.

ABSTRACT

Objective: Our aim was to analyze the reliability of midpalatal suture maturation assessment in females in the final growth period using cone-beam computed tomography (CBCT) by an undergraduate student in two time periods (intra-examiner) and compared to an orthodontist (inter-examiner). **Methods:** Forty pretreatment CBCT images of 14 to 19-year-old females were selected. Images were oriented in the InVivo Dental 5.1 software. Axial slices were selected either by a researcher (preselected slices – suture-PS) or by the examiners (free scanning and slice selection – suture-FS) and each image was classified according to its midpalatal suture maturation stage. The examiners analyzed all images individually and twice, with a two-week interval between sessions. The weighted kappa coefficient according to Landis and Kock was used to assess intra- and inter-examiner agreement. **Results:** The Kappa intra-examiner of the undergraduate student was 0.824 for suture-PS and 0.692 for suture-FS, and the orthodontist was 0.919 and 0.695, respectively. Inter-observer agreement was higher for suture-PS (>0.479) than for suture-FS (>0.300). **Conclusion:** The intra-observer kappa coefficient was very good for the undergraduate student, similar to the orthodontist. However, inter-examiner agreement was not good, indicating a need for development in the method training.

Submitted: December 18, 2019
Modification: January 20, 2020
Accepted: January 24, 2020

***Correspondence to:**
Claudia Trindade Mattos
Address: Rua Mário Santos Braga, 30, 2º andar, sala 214, Campus do Valonguinho, Centro, Niterói, RJ, Brazil. Zip code: 24020-140
Telephone number: + 55 (21) 2622-1621
E-mail: claudiatrindademattos@gmail.com

INTRODUCTION

Rapid maxillary expansion (RME) is a treatment indicated to increase the transversal dimension of maxilla through the opening of midpalatal suture. This treatment is applied in cases of skeletal atresia[1]. In individuals in the final stages of skeletal maturity, this expansion can be difficult due to closure of midpalatal suture, and can cause accentuated buccal tipping, bony fenestration, gingival recession and alveolar plate resorption.[2-5]

The fusion of the midpalatal suture can extend from infancy until the age of 30 years and is variable between individuals of the same age.[6] The individual evaluation of stages of midpalatal suture maturation before RME may improve diagnosis and contribute to the success of treatments because such evaluation helps determine whether conventional treatments can be implemented or surgically assisted rapid maxillary expansion is necessary.

Angelieri et al.[7] proposed a qualitative method of midpalatal suture maturation classification via cone beam computed tomography (CBCT). This method can improve diagnosis and treatment planning. Midpalatal suture maturation has five stages (A, B, C, D, and E). At stages A, B, and C, the midpalatal suture is still open; at stage D, it closes in the palatine bone; and at stage E, the midpalatal suture is totally closed.

The method proposed by Angelieri et al.[7] should be used by clinical orthodontists because it may be utilized to predict the ideal treatment choice for a successful individual RME. This method should be simple and practical to contribute to treatment planning. Many authors[8-14] analyzed the proposed method,[7] but none of them evaluated the reliability of the assessment of midpalatal suture maturation at different levels of academic degree.

This study aimed to analyze the assessment of midpalatal suture maturation in females in the final growth period via CBCT used by an undergraduate student in two time periods (intra-examiner). Results were compared with those obtained by an orthodontist (inter-examiner).

MATERIALS AND METHODS

The research protocol was approved by the Ethics and Research Committee from Universidade Federal Fluminense (CAAE #37656014.8.0000.5243). Cone-beam computed tomographies from 14 to 19-year-old females were selected. All CBCT images had been acquired before orthodontic treatment for clinical reasons (in cases which were necessary to improve the diagnosis). CBCTs were obtained with the i-CAT 3D scanner (2.0.2.1 Xoran Technologies, Ann Arbor, Michigan). The images were acquired at 12 bits in a 360 µ rotation by using a 20-s cycle, expanded field of view (220 mm), and voxel size of 0.4 mm. The images were stored in the DICOM format (Digital Imaging and Communications in Medicine).

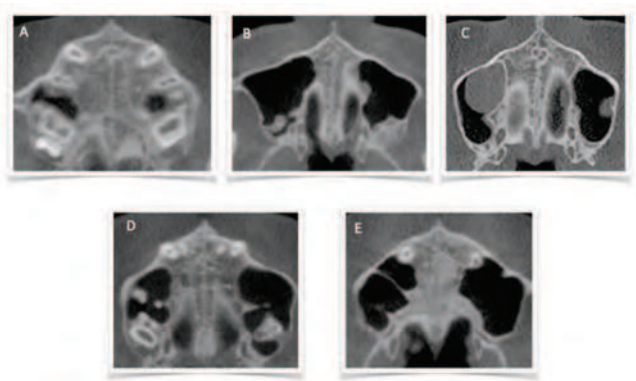

***Figure 1**: The midpalatal suture maturation stages A, B, C, D, and E, according to the method proposed by Angelieri et al.[7]*

All CBCT images were assessed using InVivo Dental 5.1 (Anatomage, San Jose, California). Head orientation was performed in the software in accordance with previously described methods[7] by checking all the planes of space and ensuring that the anteroposterior long axis of the palate was horizontal. The images were later classified into five maturation stages[7]: 1) at stage A, the midpalatal suture was almost a straight high-density sutural line with minimal or no interdigitation; 2) at stage B, the midpalatal suture assumes an irregular shape and appears as a scalloped high-density line; 3) at stage C, it is categorized as "bony islands" throughout the midpalatal suture; 4) at stage D, the midpalatal suture fuses in the palatine bone; and 5) at stage E, the midpalatal suture fuses in the maxilla (Figure 1).

Two observers (TSL and IOC; an undergraduate student and an orthodontist) were trained and calibrated to perform all assessments by using CBCT scans that were not included in this study. The undergraduate student was in the last academic year in dentistry, while the orthodontist had a previous experience in interpreting CBCT images and had already been trained to apply the proposed method. Each examiner was considered calibrated when the weighted kappa coefficients between two time assessments and between his/her classifications and those from their trainer were above 0.5.

They were blinded to the subjects' age and independently performed all assessments twice with a 2-week interval between sessions. The observers conducted the following evaluations: suture assessment in CBCT-predetermined slices (suture-PS) and suture assessment in CBCT through free scanning and slice selection by each observer (suture-FS).

For the suture-PS evaluation, a third researcher (COL)performed the head orientation and selected the axial cross-sectional slice for all patients. The researcher also coded and randomly organized the images in a presentation (Microsoft Office PowerPoint 2007; Microsoft, Redmond, Washington) with a black background, displayed sequentially on a high-definition computer monitor for assessment by the examiners. For suture-FS, the evaluators freely performed head orientation, selected slices, and classified the maturation stages of the midpalatal suture from the images (as described in a previous method)[7].

Statistical Analysis

A weighted kappa coefficient was used to test the intra-observer and inter-observer agreement for suture-PS and suture-FS. Kappa coefficients were categorized in accordance with the methods of Landis and Kock[15] (poor, 0–0.19; fair, 0.20–0.39; moderate, 0.40–0.59; substantial, 0.60–0.79; and almost perfect, 0.80–1.00).

RESULTS

Table 1 shows intra- and inter-examiner kappa coefficient agreements for the methods analyzed. The intra-observer agreements were almost perfect for suture-PS for undergraduate student and orthodontist. When evaluators freely performed head orientation, slice selection, and classification of the maturation stages of the midpalatal suture the agreements were substantial for both observers. The inter-examiner weighted kappa coefficient was moderate for suture-PS and poor for suture-FS.

Table 2 shows the student's agreement percentage compared with the orthodontist's assessments of suture-PS and suture-FS. The student's agreement percentages were smaller at stages B and D. The student's disagreement percentages compared with the orthodontist's assessments were mostly from only one stage of difference at these stages (Table 3). For suture-FS, the largest disagreement percentage was detected at stage C, and no important difference was found between one stage or more than of stages of differences between the undergraduate student's assessments compared with the orthodontist's assessments (Table 3).

***Table 1**: Intra- and inter-observer agreement (kappa coefficient).*

Assessment type	Intra-observer		Inter-observer
	Student	Orthodontist	Student X Orthodontist
Suture-PS	.824	.919	.479
Suture-FS	.692	.695	.300

Note: *Suture-PS: suture assessment in CBCT predetermined slices; Suture-FS: suture assessment in CBCT through free scanning and slice selection by the observer.*

***Table 2**: Student's agreement percentual compared to the orthodontist assessments*

Stage	Student's percent agreement	
	Suture-PS	Suture-FS
A	50%	50%
B	40%	14%
C	57%	36%
D	25%	12.5%
E	46.1%	57%

Note: *Suture-PS: suture assessment in CBCT predetermined slices; Suture-FS: suture assessment in CBCT through free scanning and slice selection by the observer*

***Table 3**: Student's disagreement compared to the orthodontist assessments.*

Stage	Student's disagreement			
	Suture-PS		Suture-FS	
	1 stage	More than 1 stage	1 stage	More than 1 stage
A	0	3	0	2
B	6	0	6	0
C	0	3	5	4
D	2	1	5	2
E	2	5	0	3
TOTAL	10 (45.5%)	12 (54.5%)	16 (59%)	11 (41%)

Note: *Suture-PS: suture assessment in CBCT predetermined slices; Suture-FS: suture assessment in CBCT through free scanning and slice selection by the observer; 1 stage: one stage of difference between the undergraduate student assessment compared to the orthodontist assessments; More than 1 stage: more than one stage of difference between the undergraduate student assessment compared to the orthodontist assessments.*

DISCUSSION

Rapid maxillary expansion may be complicated in individuals at the end of growth because of skeletal maturation. An individual evaluation of midpalatal suture maturation may improve diagnosis and treatment planning, indicating either conventional or surgical treatment is appropriate. In our study, females aged 14–19 years were assessed because they were at their final growth stages or at the critical stage to achieve the success of RME.

A systematic review[16] found three types of assessments of midpalatal suture maturation: quantitative, semi-quantitative and qualitative evaluations. Angelieri *et al.*[7] proposed a novel qualitative methodology using CBCT for individual evaluation of midpalatal suture maturation. This method should be simple to use in order to be implemented in clinical practice in orthodontics. The method was proposed and validated through a study[7] in which three evaluators, who introduced and proposed the method, tested 30 random CBCTs and the weighted kappa coefficients were calculated.

In some articles,[8,9,11-14] the evaluators who had a previous experience in interpreting CBCT images classified midpalatal suture images. Barbosa et al.[10] assessed the reliability of the individual assessment of midpalatal suture maturation as conducted by orthodontists and radiologists with varied age and experience, and some of them had no experience in CBCT. However, no article has reported midpalatal suture maturation assessment by people without an experience in diagnostic imaging exams or by undergraduate students. In our article, the undergraduate student, who had never used CBCT, underwent training, mastered the use of the method proposed by Angelieri et al.,[7] and categorized the suture at appropriate stages.

The intra-observer agreement for suture-PS was almost perfect between the undergraduate student and the orthodontist. These results were similar to previous findings,[7,8,11-14] which were obtained by observers who had a previous experience in analyzing CBCT images. On the basis of these findings, we might infer that the method proposed by Angelieri et al.[7] might be learned by people who were not familiar with the software and who had never analyzed CBCT images.

Although in a recent article[10] some examiners who had no previous experience with CBCTexams analyzed the midpalatal suture maturation and reached fair to moderate agreement rates other previous articles showed that the undergraduate student has success in analyzing and performing different diagnostic methods using CBCT images. Additionally, in other studies, the group with the lowest level of orthodontic experience had the best performance in analyzing the cervical vertebrae maturation method[17] and undergraduate students showed better volumetric landmark location in 3-dimensional images than orthodontic residents,[18] confirming that the level of experience do not always improve reliability.

The intra-observer weighted kappa coefficients of suture-FS were substantial for both observers. The results were almost identical, so the level of academic degree and prior use of CBCT images did not influence image processing and midpalatal suture classification. The results were lower than those of the method with predetermined slices, showing that the head orientation and the selection of axial cross-sectional slices might hamper method execution by the undergraduate student and the orthodontist.

The training of the method and the calibration of observers in using the software have been used in some studies that analyzed diagnostic methods involving CBCT.[18,19,20] For the qualitative assessment of midpalatal suture maturation, our results might indicate that previous training is essential regardless of the level of academic degree because the method is based on the visual evaluation of straightness, shape, interdigitation, and density of sutural line.

The inter-examiner agreements for suture-PS and suture-FS were moderate and fair, respectively. These results suggested that the observers developed an individual technique and standardized classification performance after they underwent training. However, the method was qualitative and subjective, so differences could be observed in this standardization. As a result, inter-observer agreement was low. Another study[21] proposed an objective and quantitative method of fractal analysis by using a CBCT image to evaluate the maturity of the midpalatal suture. The results revealed an almost perfect intra-examiner agreement (0.84) and a substantial inter-examiner agreement (from 0.67 to 0.72). This method might help enhance the reliability of midpalatal suture stages.

Although the results obtained by the undergraduate student and the orthodontist were similar, we emphasized that the exploration of CBCT in dental schools might improve the utilization of this technology in clinical practice. CBCT has been shown to be an excellent modality for maxillofacial imaging, and numerous applications in the oral and maxillofacial region have been reported[22,23]. The use of 3D CBCT images in oral radiology courses further familiarizes students with 3D anatomy and prepares them to interpret 3D images.[23]

This study was limited by the use of images of only females of a particular age range. Further studies should be conducted to confirm our results by involving different

examiners and using images of different individuals.

The intra-observer kappa coefficients of the undergraduate student and the orthodontist using predetermined slices were almost perfect. This result indicated that people without any related experience could learn and apply the method of midpalatal suture classification. However, the inter-examiner agreements were moderate and fair, indicating that each observer might develop a different assessment method.

REFERENCES

1. Korbmacher H, Schilling A, Püschel K, Amling M, Kahl-Nieke B. Age-dependent three-dimensional microcomputed tomography analysis of the human midpalatal suture. J Orofac Orthop 2007; 68 (5): 364-76.

2.Fricke-Zech S, Gruber RM, Dullin C, Zapf A, Kramer FJ, Kubein-Meesenburg D, Hahn W. Measurement of the midpalatal suture width. Angle Orthod 2012;82 (1):145-50.

3. Ciambotti C, Ngan P, Durkee M, Kohli K, Kim H. A comparison of dental and dentoalveolar changes between rapid palatal expansion and nickel-titanium palatal expansion appliances. Am J Orthod Dentofacial Orthop 2001; 119:11–21.

4. Handelman CS, Wang L, Begole EA, Haas AJ. Nonsurgical rapid maxillary expansion in adults: Report on 47 cases using the Haas expander. Angle Orthod 2000;70: 129-144.

5. Kilic N, Kiki A, Oktay H. A comparison of dentoalveolar inclination treated by two palatal expanders. Eur J Orthod 2008; 30:67-72.

6. Knaup B, Yildizhan F, Wehrbein H. Age-related changes in the midpalatal suture. A histomorphometric study. J Orofac Orthop 2004,65 (6), 467-74.

7. Angelieri F, Cevidanes LH, Franchi L, Gonçalves JR, Benavides E, McNamara JA. Midpalatal suture maturation: classification method for individual assessment before rapid maxillary expansion. Am J Orthod Dentofacial Orthop 2013;144 (5): 759-69.

8. Tonello DL, Ladewig VM, Guedes FP, Ferreira Conti ACC, Almeida-Pedrin RR, Capelozza-Filho L. Midpalatal suture maturation in 11- to 15-year-olds: A cone-beam computed tomographic study. Am J Orthod Dentofacial Orthop. 2017; 152(1):42-48.

9. Angelieri F, Franchi L, Cevidanes LH, McNamara JA Jr. Diagnostic performance of skeletal maturity for the assessment of midpalatal suture maturation. Am J Orthod Dentofacial Orthop 2015; 148:1010-101610.

10. Barbosa NMV, Castro AC. Conti F, Capelozza-Filho L, Almeida-Pedrin RR, Cardoso MA. Reliability and reproducibility of the method of assessment of midpalatal suture maturation: A tomographic study. Angle Orthod 2019; 89:71–77

11. Isfeld D, Flores-Mir C, Leon-Salazar V, 2019, Lagravere M. Evaluation of a novel palatal suture maturation classification as assessed by cone-beam computed tomography imaging of a pre- and postexpansion treatment cohort. Angle Orthod. 2019; 89:252–261.

12. Sayar G, Kilinç DD. Rapid maxillary expansion outcomes according to midpalatal suture maturation levels. Prog Orthod 2019; 20:27.

13. Jimenez-Valdivia LM, Malpartida-Carrillo V, Rodríguez-Cárdenas YA, Dias-Da Silveira HL, Arriola-Guillén LE. Midpalatal suture maturation stage assessment in adolescents and young adults using cone-beam computed tomography. Prog in Orthod 2019; 20:38.

14. Ladewig VM, Capelozza-Filho L, Almeida-Pedrin RR, Guedes FP, Cardoso MA, Ferreira Conti ACC. Tomographic evaluation of the maturation stage of the midpalatal suture in postadolescents. Am J Orthod Dentofacial Orthop 2018;153:818-24

15. Landis JR, Koch GG. The measurement of observer agreement for categorical data. Biometrics 1977; 33:159-174.

16. Isfeld D, Lagravere M, Leon-Salazar V, Flores-Mir C. Novel methodologies and technologies to assess mid-palatal suture maturation: a systematic review. Head Face Med. 2017;13:13.

17. Rongo R, Valleta R, Bucci R, Bonetti GA, Michelotti A, D'Antò V. Does clinical experience affect the reproducibility of cervical vertebrae maturation method? Angle Orthod 2015; 085: 841-847.

18. Miguez-Contreras M, Jimenez-Trujillo I, Romero-Maroto M, López-de-Andrés A, Lagravère MO. Cephalometric landmark identification consistency between undergraduate dental students and orthodontic residents in 3-dimensional rendered cone-beam computed tomography images: A preliminary study. Am J Orthod Dentofacial Orthop 2017;151:157-166.

19. Neiva MB, Soares AC, Lisboa CO, Vilella OV, Motta AT. Evaluation of cephalometric landmark identification on CBCT multiplanar and 3D reconstructions. Angle Orthod. 2015;85(1):11-7.

20. Engel TP, Renkema AM, Katsaros C, Pazera P, Pandis N, Fudalej PS. The cervical vertebrae maturation (CVM) method cannot predict craniofacial growth in girls with Class II malocclusion. Eur J Orthod 2016;38(1):1-7.

21. Kwak KH, Kim SS, Kim YI, Kim YD. Quantitative evaluation of midpalatal suture maturation via fractal analysis. Korean J Orthod. 2016; 46:323–330.

22. Parashar V, Whaites E, Monsour P, Chaudhry J, Geist JR. Cone beam computed tomography in dental education: A survey of U.S., U.K., and Australian dental school. J Dent Educ 2012; 76(11):1443-1447.

23. De Vos W, Casselman J, Swennen GR. Cone-beam computerized tomography (CBCT) imaging of the oral and maxillofacial region: a systematic review of the literature. Int J Oral Maxillofac Surg 2009; 38:609-25.