INTEGRATED TREATMENT BETWEEN ORTHODONTICS AND PEDIATRIC DENTISTRY USING THE ULECTOMY TECHNIQUE: CASE REPORT

João Victor Frazão **Câmara**[1*], Flávio de Mendonça **Copello**[1], Bárbara Pilla **Tavares**[1], Aline Borburema **Neves**[1], Antônio Carlos de Oliveira **Ruellas**[1], Andréa Vaz Braga **Pintor**[1]

[1]Department of Pediatric Dentistry and Orthodontics, School of Dentistry, Federal University of Rio de Janeiro, RJ, Brazil.

Palavras-chave: Dente Impactado. Ulectomia. Odontopediatria. Ortodontia.

RESUMO

Introdução: Eventualmente na clínica odontológica, pode ser observada a impacção de dentes, que pode acarretar transtornos para o desenvolvimento da oclusão. **Objetivo:** Objetivou-se relatar um caso clínico no qual a técnica cirúrgica de ulectomia foi utilizada, associada ao tratamento ortodôntico para auxiliar a erupção dentária de um incisivo central superior. **Relato de Caso:** Paciente do sexo masculino, 13 anos de idade, Classe I de Angle na fase de dentição mista, com dente 21 incluso e espaço reduzido para sua erupção em função da migração dos dentes adjacentes. Foi montado aparelho fixo com bráquetes prescrição Edgewise, utilizando arco 0,20" aço inoxidável com ômega justo e mola ativa entre os dentes 11 e 22 para recuperação do espaço do 21, mas não observou-se a erupção passiva. Constatou-se presença de tecido gengival fibroso que, ao toque, evidenciava a borda incisal do referido dente. O paciente foi encaminhado para clínica de Odontopediatria para a realização da ulectomia. O procedimento cirúrgico minimamente invasivo, consistiu na exérese do tecido gengival que revestia a coroa do dente 21 não irrompido, permitindo sua erupção no arco dentário. Após a cirurgia, o dente irrompeu e o tratamento ortodôntico corretivo prosseguiu. **Conclusão:** A técnica da ulectomia associada ao tratamento ortodôntico permitiu restabelecer condições para desenvolvimento da dentição com características estético-funcionais satisfatórias.

Keywords: Impacted tooth. Ulectomy. Pediatric dentistry. Orthodontics.

ABSTRACT

Introduction: In the pediatric dental clinic the impacted teeth can be observed eventually, which can lead to the development of occlusion disorders. **Objective:** This study aimed to report a clinical case in which the surgical technique of ulectomy was used in conjunction with orthodontic treatment to aid the eruption of a maxillary central incisor. **Case Report:** Male patient, 13 years old, Angle Class I in the mixed dentition stage, with the tooth 21 impacted and reduced space for its eruption due to the migration of adjacent teeth. Fixed appliance was mounted with Edgewise brackets using 0.20" stainless steel archwire with tight omega and active spring between teeth 11 and 22 to recover the space of 21, but the passive eruption was not observed. A fibrous gingival tissue was found, which by palpation revealed the incisal edge of the tooth 21. The patient was referred to a pediatric dental clinic for a ulectomy. The minimally invasive surgical procedure consisted of the excision of the gingival tissue that covered the crown of the tooth 21 allowing its eruption in the dental arch. After the surgery, the teeth erupted and corrective orthodontic treatment continued. **Conclusion:** The ulectomy technique associated with orthodontic treatment allowed to reestablish conditions for the development of dentition with satisfactory aesthetic and functional characteristics.

Submitted: October 8, 2019
Modification: November 25, 2019
Accepted: December 3, 2019

***Correspondence to:**
João Victor Frazão Câmara
Address: Alameda Doutor Octávio Pinheiro Brisolla, 6-65, Jardim Brasil, Bauru - São Paulo – Brazil. - Zip code 17012-059.
Telephone number: +55 (21)98384-4255
Email: jvfrazao92@hotmail.com

INTRODUCTION

In the pediatric dental clinic during the monitoring of the developing dentition, alterations in the pattern of eruption may result in tooth inclusion or impaction that can lead to disorders to the normal development of occlusion.[1,2] Included or unerupted tooth occurs due to a failure during the eruption process in relation to the chronology of eruption expected for the population, although its development is normal. Likewise, tooth impaction refers to the condition when the tooth is prevented from erupting by a mechanical barrier.[3]

In addition, it is essential to have space in the dental arch for proper positioning of the impacted tooth. Based on these considerations, the treatment can include the extraction of impacted tooth[4] in unfavorable cases or surgical exposure and assisted eruption in cases with good prognosis[5] or supervision in cases of systemically compromised patients.[6] The surgical procedure consists of the excision of the tissue that covers the incisal or occlusal face of permanent or deciduous teeth in order to allow eruption in the dental arch. Detailed clinical and radiographic examinations of the area are necessary for a correct indication of this surgical technique.[7,8] The ulectomy is indicated for cases in which there is gingival fibrosis with no remnant of bone tissue on the incisal or occlusal face of the impacted tooth.[9]

This study aims to present a clinical case in which the surgical technique of ulectomy associated with orthodontic treatment used for the assisted eruption of an impacted maxillary left central incisor in a young patient, avoiding major changes in occlusion.

CASE REPORT

A 13-year-old male patient came to the Orthodontics Clinic of the School of Dentistry of the Federal University of Rio de Janeiro for a first appointment presenting as chief complaint the lack of eruption of the left maxillary central incisor. The patient had no general health issues and had not sought dental treatment to solve the eruption problem of the tooth 21, until the current dental appointment. It was observed by anamnesis and clinical examination that the patient was at the mixed dentition period, presenting: Angle Class I malocclusion, a 3.5 mm overjet, a 40% overbite, upper dental midline was shifted 2.5mm to the left, a slightly convex profile and nasal-oral breathing (Figure 1).

Patient's parents reported that he was previously referred to the extraction of a supernumerary tooth in the region of the tooth 21. At the intraoral clinical examination, it was verified that the tooth 21 was not present and was possibly impacted due to the previous supernumerary in that area and also due to the migration of the adjacent teeth, resulting in a lack of space in the arch perimeter. (Figure 2).

The periapical radiographic examination of the area was performed in order to complement the clinical diagnosis. The root of the tooth 21 presented more than 2/3 of formation (stage 8 of Nolla's classification) with the crown covered only by mucous tissue, without bone remnants. The roots of teeth 21 and 22 show slight distal curvature. Thus, the suggested treatment option was space opening (with braces, archwire and coil spring) to allows spontaneous eruption of element 21, considering the possibility of a ulectomy procedure, if the passive eruption did not occur.

The standard edgewise brackets (Morelli, São Paulo, Brazil) were bonded to the upper arch only: cemented bands (American Orthodontics, Sheboyan, USA) with convertible tube accessory (Morelli, São Paulo, Brazil). The brackets were bonded on the teeth 12, 11 and 22. For the space opening, it was used biomechanics with compressed open coil spring (Morelli, São Paulo, Brazil) in the region between elements 11 and 22 in a 0.20" passive stainless steel archwire" with flush omegas tied to the tube. A protective tube (Morelli, São Paulo, Brazil) was used in regions where there were no accessories attached. The space had been opened in approximately two months, but there was no spontaneous eruption of element 21, as also seen in periapical radiography (Figure 3 A and 3B).

Then, the patient was referred to the Pediatric Dental Clinic of the Federal University of Rio de Janeiro for the ulectomy procedure.

After the antisepsis of the oral cavity with 0.12% chlorhexidine digluconate (Periogard™, Colgate Palmolive, São Paulo, Brazil), topical anesthetic Benzotop (Nova DFL, Rio de Janeiro, Brazil) was used followed by infiltration anesthesia (Figure 3C) with a 2% Lidocaine anesthetic cartridgewith Adrenaline 1: 100,000 (Alphacaine, Nova DFL, Rio de Janeiro, Brazil) with complementation on the area of the incisal edge covered by the mucous tissue and intrapapillary anesthesia in the area of the tooth 21 (Figure 3D).

With the aid of a n° 15 scalpel blade (Unoject, Rio de Janeiro, Brazil), an elliptical incision, in the mesiodistal direction, was performed around the gingival mucosa to be removed (Figure 3E) aiming to the exposure of the incisal edge of the tooth by the tissue excision (Figures 3F and 3G).

Neither surgical cement placement nor postoperative medication were necessary. Hemostasis was performed with sterile gauze and saline solution.

After 14 days the patient was evaluated showing a complete healing of the region and a good evolution with evidenced spontaneous tooth eruption (Figure 4A). The patient proceeded to the comprehensive orthodontic treatment without extractions due to the good profile and small arch discrepancy (Figure 4B).



***Figure 1**: Extraoral photographs of the patient.*



***Figure 2**: Intraoral photographs of the patient, evidencing the space closure in the region of the tooth 21.*

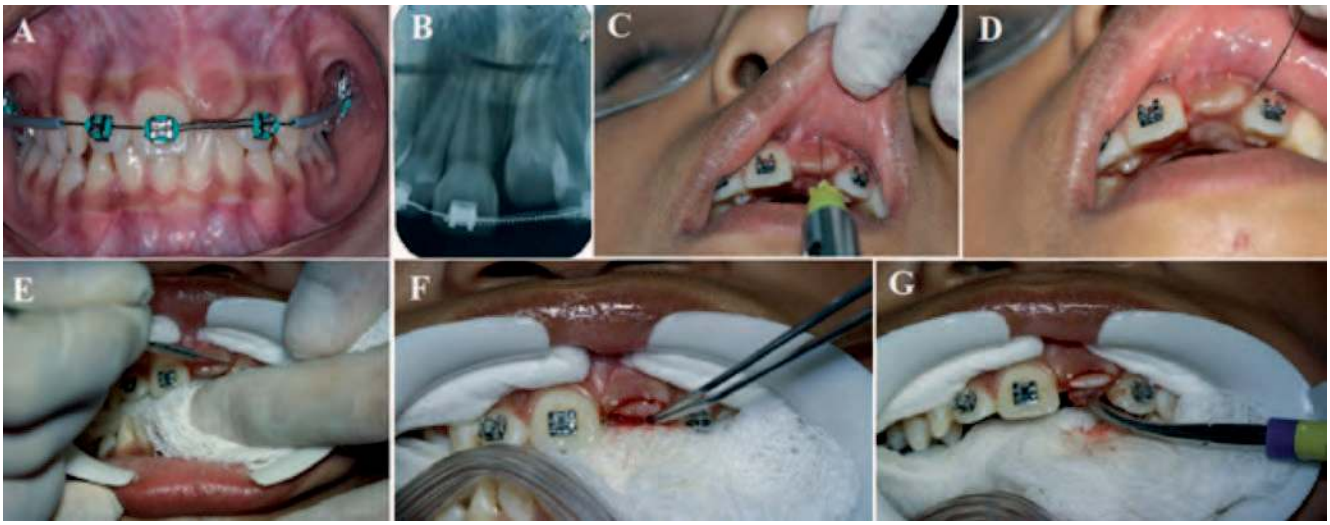

***Figure 3**: A) Fixed orthodontic appliance in place and final appearance after space opening. B) Periapical radiographic. C) Local infiltration anesthesia. D) Intrapapillary anesthesia. E) Elliptical incision of the gingival tissue. F) Excision of the gingival tissue. G) Removal of the tissue and exposure of the incisal edge.*

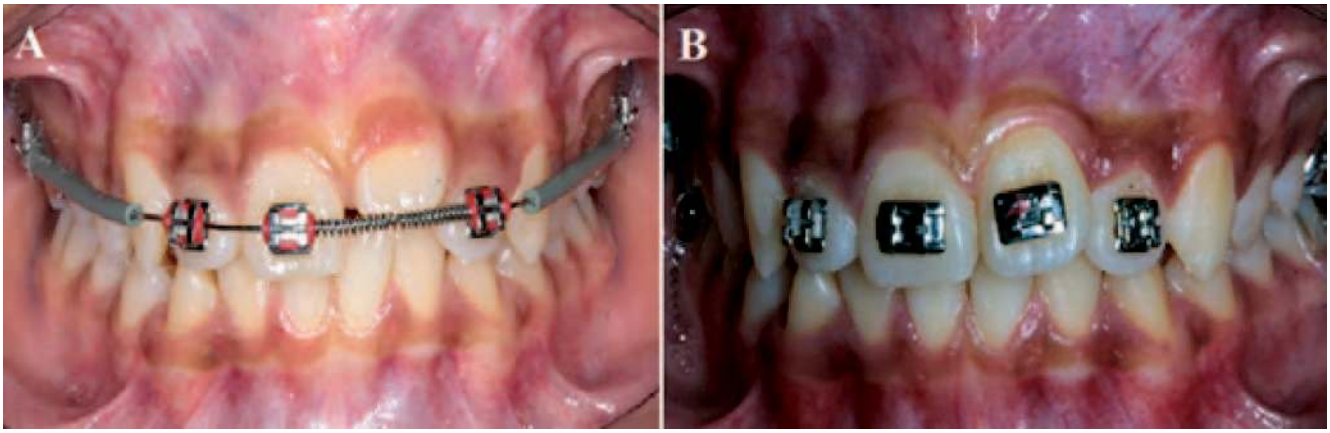

***Figure 4**: A) Frontal view, at 14 days follow-up; B) Frontal view, clinical aspect after 2 months (comprehensive orthodontic treatment will be performed).*

DISCUSSION

During monitoring of the teeth eruption in the stages of deciduous, mixed and permanent dentitions the chronology of eruption is one of the factors to be observed in the search for a physiological normal occlusion. A malocclusion may occur as a result of changes in the pattern of eruption.

Therefore, when there is absence of a tooth or delay in its eruption, the etiology should carefully be investigated in order to plan the beginning and type of treatment. Dental agenesis and delayed eruption are similar clinical signs, thus making the differential diagnosis extremely necessary.[5] However, the imminent presence of an impacted tooth was evidenced by signs such as increased volume and contoured marks in the tissue,[5] as observed at the present report (Figure 3).

Considering the treatment of an impacted tooth by surgical exposure and assisted eruption, Koch et al.[10] stated that if the eruption of a tooth is paralyzed it is recommended he removal of any barrier at least when the root of the tooth is formed in 2/3 of its extension.[10] Since, if the ulectomy is postponed there is a risk of bending the root apex and the closure of space through the inclination of adjacent teeth, resulting in the need of subsequent orthodontic treatment for space opening.[9,10] In this sense, as soon as the space for the impacted tooth was obtained, the ulectomy was performed.

In the present case report there was evidence of tooth dilaceration. The presence of bone layer, agenesis and degree of reduced root formation are factors that contraindicate the ulectomy procedure. However, the previous report of a supernumerary tooth, in the region of the impacted tooth, may have been associated as a relevant condition for the delayed tooth eruption observed.[11-14]

The surgical technique of the ulectomy is configured by elliptical, circular or oval incisions that delimit the area for tissue excision. Its extension should allow exposure of the incisal edge or occlusal face of the tooth. Scalpel and blade, as described, laser or electrocautery may be used.[15] The surgery involved only the gingival tissue and the postoperative was great, since the patient did not complain of pain and tooth eruption was well-succeed.

In addition, achieving the tooth positioning in function at the arch, improves the esthetics and social relationships. The period of dental exchange is delicate, since in pre-adolescence and childhood most of the psychosocial and emotional development occurs. Thus, a tooth that has its eruption chronology altered can generate a negative repercussion in the development and life of the child.[16]

The interception of malocclusions at the proper time avoids the worsening of the malocclusion and may avoid the need for extractions of permanent teeth in the future.The interceptive management of the impacted tooth by the space opening and ulectomy interventions was effective.

CONCLUSION

The technique of ulectomy associated with orthodontic procedure is shown as a necessary and effective surgical and therapeutic option for situations of delayed tooth eruption with impacted teeth, showing favorable results for the development of occlusion of the patient.

REFERENCES

1) Lascala NT, Lascala Júnior NT. Aspectos cirúrgicos na prevenção – frenectomia, bridectomia e ulectomia. In. LASCALA, N. T. Prevenção na clínica odontológica: Promoção de saúde bucal. São Paulo: Artes Médicas, p. 209-220, 1997.

2) McDonald RE, Dean JA. Odontopediatria para crianças e adolescentes. 9ª ed. Rio de Janeiro: Elsevier Editora Ltda. 2011.

3) Health Sciences Descriptors: DeCS [Internet]. 2017 ed. São

Paulo (SP): BIREME / PAHO / WHO. 2017 [updated 2017 May 18; cited 2017 Jun 13]. Available from: http://decs.bvsalud.org/I/homepagei.htm.

4) Varvara G, Bernardi S, Piattelli M, CutilliT.Rare and life-threatening complication after an attempted lower third molar extraction: Lemierre syndrome. Ann R Coll Surg Engl. 2018;(29):1-3.

5) Candeiro GTM, Correia FC,Candeiro SALM. Ulectomia como opção cirúrgica no retardo da erupção dentária: relato de caso. Revista Odontológica de Araçatuba. 2009;(30)2:45-49.

6) Giugliani R, Villarreal ML, Valdez CA, Hawilou AM, Guelbert N, Garzón LN, Martins AM, Acosta A, Cabello JF, Lemes A, Santos ML, Amartino H. Guidelines for diagnosis and treatment of Hunter Syndrome for clinicians in Latin America. Genet Mol Biol. 2014;37(2):315-29.

7) Carreira MA, Pacenko MR, Matsumoto MA, Dekon AFC. Cisto de erupção e resolução cirúrgica por ulectomia: caso clínico. J Appl Oral Sci. 2003;11(3):234.

8) Gregori C, Motta LFG. Cirurgia em odontologia. In: Guedes–Pinto AC. Odontopediatria. 7ª ed. São Paulo: Santos;2003.

9) Issao M, Guedes-Pinto AC. Manual de odontopediatria. 10ª ed. São Paulo: Pancast. 1999.

10) Koch G, Modeér T,Pousen S, Rasmussen P. Odontopediatria: Uma abordagem clínica. In: Patologia bucal e cirurgia. 2ª Ed. São Paulo: Santos; 1995.

11) American Academy of Pediatric Dentistry. Management of the Developing Dentition and Occlusion in Pediatric Dentistry. Reference Manual. 2018;40(6):352-365.

12) Cavalcante AL, Paiva LCA. Utilização da ulectomia na clínica infantil: relato de caso. Ciências Biológicas e da Saúde. 2006;12(3):39-42.

13) Arnaud RR, Santos MGC, Valença AMG, Forte FDS, Lima KJRS, Beltrão RTS. Ulotomia: coadjuvante do tratamento da má oclusão. Revista da Faculdade de Odontologia, Passo Fundo. 2014;19(2):234-238.

14) Vantine FF, Carvalho PL, Candelária FLA. Estudo dos fatores que alteram a cronologia de erupção dentária. Revista Virtual de Odontologia. 2007;1(3):18-23.

15) Stuani AS, Souza AHF, Stuani AS, Stuani MBS. Solução alternativa para incisivo superior impactado. Revista Íbero-americana de Odontopediatria e Odontologia de Bebê. 2004;7(38):335-340.

16) Poricelli E, Ponzoni D. Cirurgia bucal pediátrica. In: Toledo OA. Odontopediatria: Fundamentos para a prática clínica. 3ª ed. São Paulo: Premier; 2005.