AMELOBLASTIC FIBRODENTINOMA IN A BABY MAXILLA: CASE REPORT

Daniela Maria Carvalho **Pugliesi**[1]*, Camila Maria Beder **Ribeiro**[1], Valdeci Elias dos **Santos Junior**[1], Lisa Danielly Curcino **Araujo**[1], José Ricardo **Mikami**[2], Tamires Quicyane Sampaio **Araújo**[2], Luiza Eduardina Ferreira **Barros**[2]

[1]Dentistry College, Federal University of Alagoas, Maceió, AL, Brazil.
[2] Dentistry College, Centro Universitário Cesmac, Maceió, AL, Brazil.

Palavras-chave: Odontopediatria. Mucosa oral. Tumores odontogênicos.

RESUMO

Introdução: O Fibrodentinoma Ameloblástico (FDA) é um tumor odontogênico misto, raro, assintomático e de crescimento lento, acometendo normalmente crianças e jovens em sua primeira ou segunda década de vida. Essa lesão geralmente provoca expansão óssea da região envolvida e dificulta a erupção dentária. **Objetivo**: O objetivo deste trabalho é relatar um caso de FDA em maxila anterior de bebê de 3 anos de idade e seu tratamento, ressaltando a importância do atendimento odontológico precoce e o tratamento para este tipo de lesão. **Relato de caso**: Paciente do gênero feminino, 3 anos, compareceu à clínica odontológica de atendimento a bebês do Centro Universitário Cesmac (Maceió – AL, Brasil), acompanhada de sua mãe, relatando uma gengiva inchada há aproximadamente 6 meses. Ao exame clínico, observou-se um aumento de volume na região do incisivo central e lateral direito, com coloração discretamente avermelhada, superfície lisa, formato esférico, com inserção séssil, sem mobilidade e de consistência firme. Ao exame radiográfico constatou-se uma lesão mista com área radiolúcida compatível com reabsorção óssea e áreas radiopacas compatíveis com material calcificado no interior da lesão. Foi realizado uma biopsia incisional, confirmando o diagnóstico de Fibrodentinoma Ameloblástico. **Conclusão**: O tratamento desta anomalia requer uma abordagem precoce com o objetivo de melhorar a qualidade de vida desses pacientes, devendo-se aconselhar os pais ou responsáveis quanto à necessidade do acompanhamento periódico após a realização do tratamento.

Keywords: Pediatric Dentistry. Oral mucosa. Odontogenic Tumors.

ABSTRACT

Introduction: Ameloblastic fibrodentinoma (AFD) is a rare, asymptomatic, slow-growing mixed odontogenic tumor, usually affecting children and young people in their first or second decade of life. This lesion usually causes bone expansion of the involved region and makes tooth eruption difficult. **Objective**: the aim of this study is to report a case of AFD in the anterior maxilla of a 3-year-old baby and its treatment, highlighting the importance of early dental care and treatment for this type of injury. **Case report**: A 3-year-old female patient attended the dental care clinic at Cesmac University Center (Maceió- AL, Brazil), accompanied by her mother, reporting a swollen gum for approximately 6 months. Clinical examination revealed an increase in volume in the right central and lateral incisor region, discreetly reddish in color, smooth surface, spherical shape, sessile insertion, no mobility and firm consistency. Radiographic examination revealed a mixed lesion with radiolucent area compatible with bone resorption and radiopaque areas compatible with calcified material within the lesion. An incisional biopsy was performed, confirming the diagnosis of Ameloblastic Fibrodentinoma. **Conclusion**: Treating this anomaly requires an early approach to improve the quality of life of these patients. Parents or guardians should be advised of the need for periodic follow-up after treatment.

Submitted: July 4, 2019
Modification: October 14, 2019
Accepted: October 23, 2019

***Correspondence to:**
Daniela Maria Carvalho Pugliesi
Address: Av Lourival Melo Mota, S / N, the Martins Board, CEP: 57072-970, Maceió, AL, Brazil.
Telephone number: + 55 (82) 99993-9933
E-mail:dpugliesi@hotmail.com

INTRODUCTION

During childhood, the oral cavity may develop several phenomena that contribute to establishing developmental alterations or pathogens.[1] The oral manifestations usually detected in pediatric dentistry are natal and neonatal teeth, Bohn's nodules, Epstein pearls, lamina cyst, cleft palate, micrognathia, tongue-associated alterations and several others.[2]

Odontogenic tumors are lesions derived from epithelial or mesenchymal tissues that are part of the complex process of odontogenesis and are histologically classified according to their origin in epithelial, mesenchymal or mixed. The etiology of these changes is related to disturbances in the development of teeth and associated structures.[3] Jaw bone tissue is the major region affected by these tumors, although some peripheral forms of these lesions are recognized. Odontogenic tumors are usually slow-growing and asymptomatic, and some of them have a predilection for specific age, gender and race.[3,4]

Ameloblastic fibrodentinoma (AFD) is a mixed odontogenic tumor composed of odontogenic epithelium and of odontogenic mesenchyme resembling dental papilla. This rare, asymptomatic, slow-growing tumor usually affects children and young people between the first and the second decades of life. It is usually diagnosed before the age of 20. It has a predilection for the posterior mandible (molars and premolars area) causing bone expansion and difficulties in tooth eruption of the involved teeth.[5,6] When AFD affects primary teeth, it is usually observed in the anterior region, mostly in incisors area6. Radiographically, it presents a uni or multilocular radiolucent lesion, with well-defined edges. Usually, the presence of amorphous radiopaque material is observed; linked to a badly positioned tooth, associated to a displaced tooth.[7]

Thus, the purpose of this study is to report a case of Ameloblastic Fibrodentinoma in the anterior maxilla of a 3-year-old baby and its treatment, highlighting the importance of early dental care and treatment for this type of injury.

CASE REPORT

A 3-year-old female patient, melanoderma, attended the dental clinic at the Centro Universitário Cesmac, Maceió - AL, Brazil, accompanied by her mother; the girl's gums had been swollen for approximately 6 months. In the intra-oral physical examination, there was an increase in volume in the region of the central and right upper lateral incisors, which were poorly positioned. It had a slightly reddish coloration, smooth surface, spherical shape, with sessile insertion, fixed and firm consistency.

To verify if there was bone involvement, a maxillary occlusal x-ray with periapical film was performed. A mixed lesion was found with a radiolucent area compatible with bone resorption and radiopaque areas compatible with calcified material inside the lesion. The limits were not defined, there was dental displacement, mainly of tooth 51 and root resorption of teeth 51 and 52 involved in the lesion. An incisional biopsy was performed under local anesthesia with the aid of "punch" surgical cut for its accuracy and practicality. The material was sent to the laboratory of oral pathology of the Centro Universitário Cesmac, hypothesizing the diagnosis of calcifying odontogenic cyst, calcifying epithelial odontogenic tumor or central giant cell lesion.

The histological evaluation of specimens revealed proliferation of odontogenic epithelial bundles with columnar peripheral cells intermingled by a cellular myxoid stroma, resembling ameloblastic fibroma. Mineralized dentinoid material was observed in close relation to epithelial and mesenchymal cells leading to a final diagnosis or Ameloblastic fibrodentinoma. A microscopic consult was asked to the Piracicaba School of Dentistry of the State University of Campinas (Unicamp), which supported our diagnosis.

For a better visualization of the lesion and surgery planning, a cone beam CT scan was performed, two weeks after the incisional biopsy. The tomographic images allowed observing that the lesions showed higher volumetric increase on the buccal side and delimited with size 21.76 mm (height) x 22, 18mm (width) and 13.69mm (depth), and with calcified areas inside (Figure 1).

The removal of the lesion was performed under general anesthesia with orotracheal intubation. After the incision with a trapezoid shape and flap displacement, the lesion was exposed and enucleated with complete removal and without rupture, using a Molt curette, and a good cleavage plane was observed, which favored the enucleation. The removal of the lesion showed tooth 53 was committed, and we decided to extract it. The cavity was cared for, with curettage to prevent the lesion from remaining, the regulation of bone protrusions with bone file, and irrigation with saline 0.9%, leaving a cavity of about 20x15 mm. We also decided for superior labial frenectomy, followed by suture with resorbable polyglactin 910 4-0. In the macroscopic aspect of the surgical specimen, the lesion could be observed to comprise teeth 51 and 52, presenting a fibrous capsule, and calcified structures were found within it

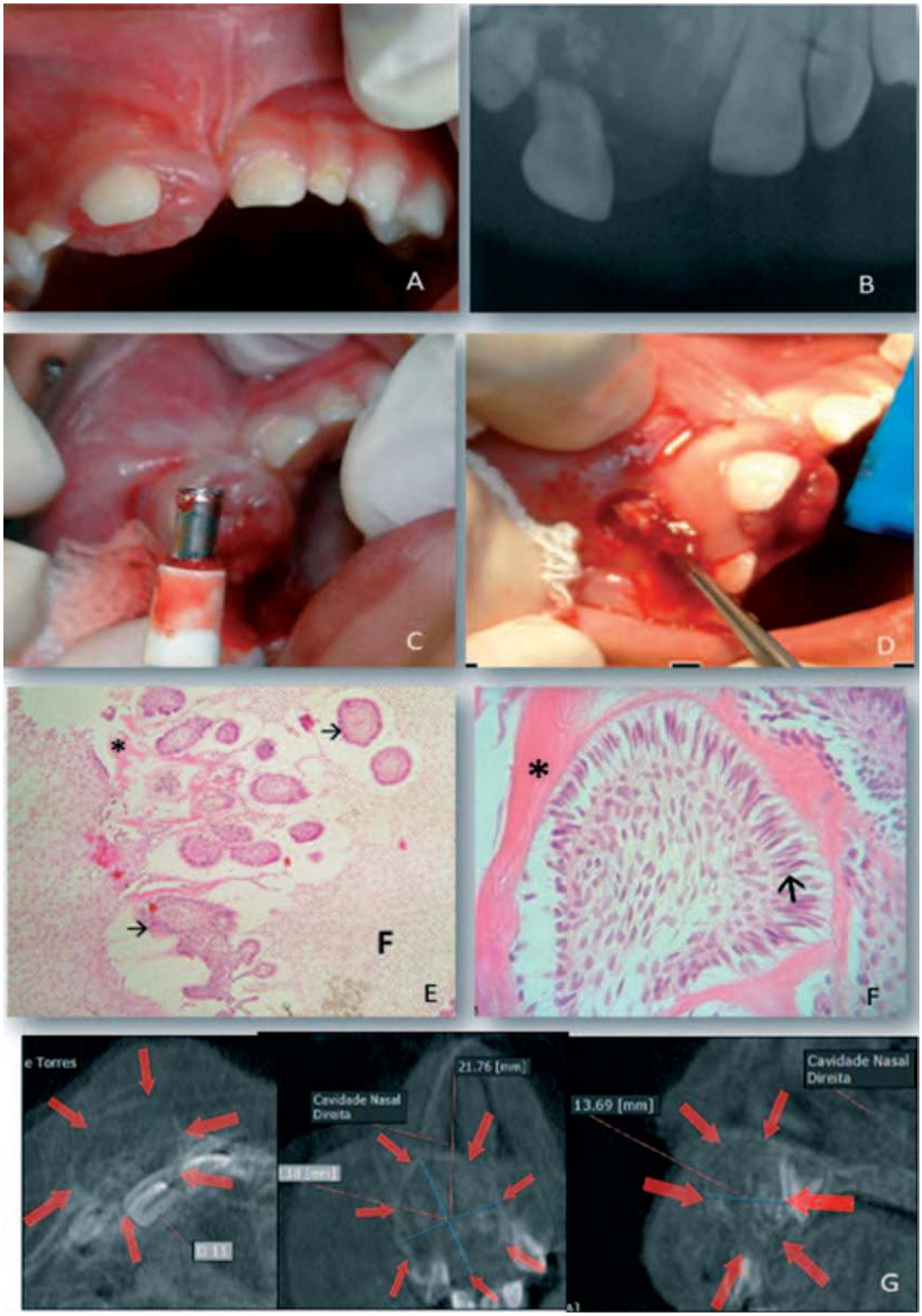

***Figure1**:(A) Initial intraoral aspect in an occlusal view: tooth 51 with vestibular displacement associated with a volumetric increase mainly by palatine, (B) Occlusal radiography of the maxilla with periapical film: radiopaque areas compatible with calcified material inside the lesion. (C) Surgical "punch" used to aid biopsy (D) Incisional biopsy: removal of material from the buccal region of maxillary volumetric enlargement, (E) Photomicroscopy of histological section: histological sections show epithelial (->) bundles permeated by mineralized component (*) resting amidst richly cellular myxoid stroma (f) (HE 40x), (F) Photomicroscopy of histological section: epithelial bundles (*) (HE 400x and (G)) Computed tomography: a - axial cut - lesion with anterior expansion with destruction of part of the cortical vestibular, but preserving the germs of teeth 11, 12 and 13 b - coronal cut - displacement of the floor of the nasal fossa, but without rupture of the cortical bone, c - sagittal cut - calcified areas inside the lesion (red arrows) and little expansion in the palatal region*

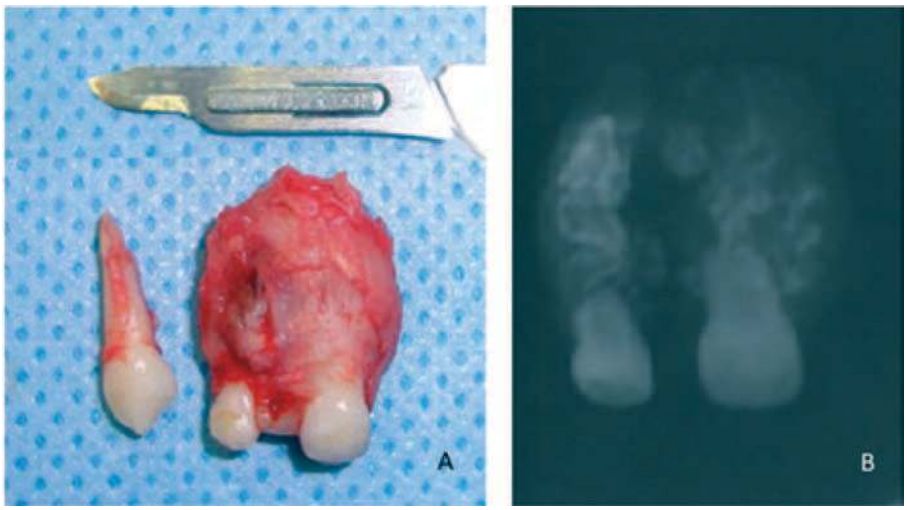

***Figure 2**: (A and B) teeth 53 compromised by the lesion, 51 and 52 associated with the lesion and periapical radiograph of the lesion: radiopaque areas relative to calcified material.*

A normal healing process was observed in clinical follow up 15 days after surgery. Pain or feeding difficulties were not reported by the patient. Radiographically, a radiolucent area compatible with the remaining bone cavity at the lesion site was observed and the germs of teeth 11, 12 and 13 were preserved (Figure 3). The patient is under strict clinical and radiographic follow up and had no recurrences.

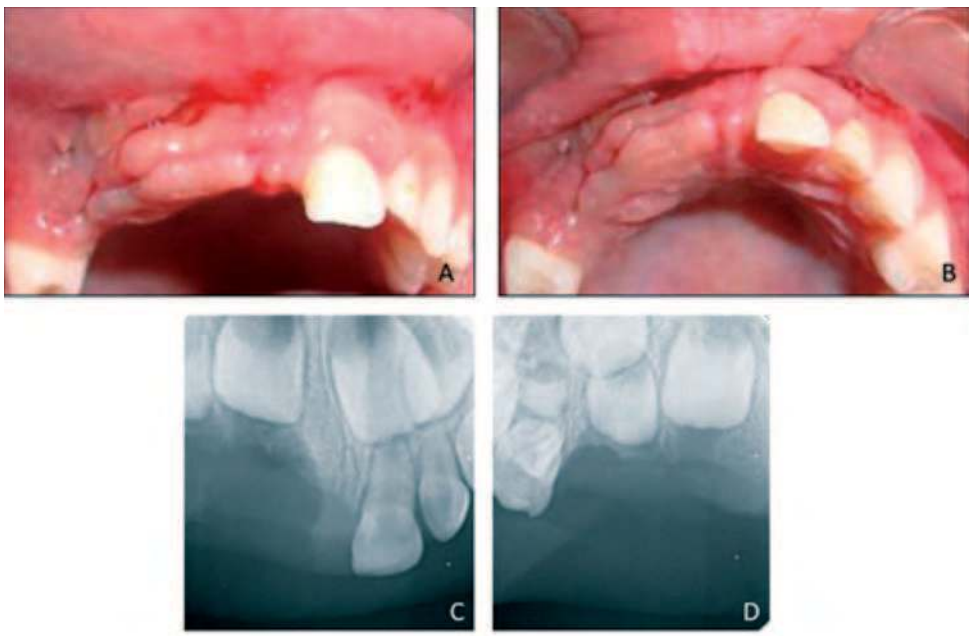

***Figure 3**: (A and B) Intraoral appearance after 15 days in an occlusal view: adequate maxillary arch contour and absence of teeth 51, 52 and 53 extracted in surgery, (C and D) Periapical radiographs after 15 days: compatible radiolucent area with the remaining cavity of the lesion. Germs of teeth 11,12 and 13 preserved.*

DISCUSSION

Ameloblastic Fibroma (AF) is indicated as a true mixed tumor, presenting neoplastic epithelial and mesenchymal tissues. Integrated by odontogenic ectomesenchima, which looks like a dental papilla, with epithelial bundles that resemble dental lamina and enamel organ. Ameloblastic Fibro-odontoma (AFO) is an uncommon benign odontogenic tumor, which has in its composition dentin and enamel, ameloblastic fibroma structures like. [2,4]

AF and AFD are considered mixed odontogenic tumors, composed of epithelial cells and ectomesenchymal

neoplastic components. According to WHO (2017), in the latest book of classification of head and neck tumors in the section of ameloblastic fibroma, based on histopathological features, it is not possible to distinguish between AFs (true neoplasms) and early stage odontomas. However, rare AF show the formation of hard dental tissues and reach an exceptional size. These lesions have been referred to as ameloblastic fibrodentomas or ameloblastic fibroid odontomas, but are probably developing odontomas. Thus, due to the histopathological features presented in the case described, the descriptive diagnosis corroborated the WHO classification.[5] They are differentiated by the fact that AFDs exhibit dysplastic or tubular dentin material, while AFOs exhibit deposits of the enamel matrix, and ameloblastic fibromas have any type of hard tissue dental deposits.[6] Radiographically, a radiolucent image with definited limits of cystic appearance was observed, presenting radiopaque calcified material with tooth dislocation and resorption in relation to the involved tooth, as reported in the literature.[1,6,7,8]

The treatment of choice was enucleation with subsequent curettage, corroborating the works described in the literature.[1,6,9,10,11] The prognosis of the development of the permanent dentition of the patient in question is favorable for the future, since the preservation of tooth germs has been observed radiographically.[1,12,13,14] Also in this case, the upper lip frenectomy was performed due to the extension of the lesion, as seen clinically and in the imaging exams, with low lip frenum insertion, indicating the procedure in this case.[15]

The early discovery of changes in the oral cavity of infants is ctitically important and brings many benefits, since diagnosis at the initial stage of these lesions prevents future damage.

More data on the AFD need to be collected, in order to better understand the lesion, biological behavior, the threat of malignant transformation, as well as its relationship with other odontogenic lesions. However, treating this anomaly requires an early approach to improve the quality of life of these patients. The need for periodic follow-up after treatment has to be made clear to parents or guardians.

REFERENCES

1. Sabu AM, Gandhi S, Singh I, Solanki M, Sakharia A. R.Ameloblastic Fibrodentinoma: A Rarity in Odontogenic Tumors. Journal of maxillofacial and oral surgery. 2018; 17(4): 444-448

2.Silva FWGP, Queiroz AM, Borsatto MC, Filho PN. Main odontogenic tumors that can affect the oral cavity of children. Dental Review of Universidade Cidade de São Paulo.2007; 19 (2): 181-187.

3. Chrcanovic, BR, Gomez RS. Ameloblastic fibrodentinoma and ameloblastic fibro-odontoma: an updated systematic review of cases reported in the literature. Journal of Oral and Maxillofacial Surgery. 2017; 75(7): 1425-1437.

4.Neville BW, Damm DD, Allen CM, Bouquot JE.Patologia oral and maxillofacial.2ª ed.Rio de Janeiro-RJ: Guanabara; 2008. Odontogenic Cysts and Tumors; p 580-582;601-604.

5.Chan JKC, El-Naggar AK, Grandis JR, Takata T, Slootweg PJ. WHO Classification of Head and Neck Tumours. World Health Organization, 4th edition; 2017.

6. Molina RB, Rodríguez SS, Borella AMB, Burciaga RGC, Repetto GT, Frechero NM. A histopathological and Immunohistochemical analysis of ameloblastic fibrodentinoma.a case report.Hindawi Publishing Corporation.2013: 1-7.

7.Cassidy JP, Crocker DJ, Grade WH. Ameloblastic fibrodentinoma. J Oral Maxillofac Surg.1987; 45 (8): 734-736.

8.Fernández RL, Rodríguez JT, Molina RB. Ameloblastic fibrodentinoma in a pediatric patient: presentation of a case.Revista Odontológica Mexicana.2009; 13 (1): 43-46.

9.Napier SS, Devine JC, Rennie JS, Lamey PJ.Unusual leiomyomatous hamartoma of hard palate: a case report. Oral Surg Oral Med Oral Pathol Oral Radiol Endod.1996; 82 (3): 305-307.

10.Brandt SK, Mason MH, Barkley R.Ameloblastic fibrodentinoma: report of case.ASDC J Dent Child.1988; 55 (5): 372-375.

11. Kaur V, Tilakraj TN. Peripheral ameloblastic fibrodentinoma in a 3-year-old boy: Report of an unusual and rare case. J Oral Maxillofac Pathol. 2018 Jan-Apr;22(1):112-115.

12.Akal UK, Gunhan O, Guler M.Ameloblastic fibrodentinoma.Report of two cases.Int J Oral Maxillofac Surg.1997; 26 (6): 455-457.

13.Ulmansky M, Bodner L, Praetorius F, Lustmann J. Ameloblastic fibrodentinoma: report on two new cases.J Oral Maxillofac Surg.1994; 52 (9): 980-984.

14.Sankireddy S, Kaushik A, Krishna BA, Reddy AG, Vinod VC, Sridevi V. Ameloblastic fibrodentinoma involving anterior maxilla: A rare case report. J Indian Soc Pedod Prev Dent 2013; 31: 275 -8..

15.Delli K, Livas C, Sculean A, Katsaros C,Bornstein MM.Facts and myths regarding the maxillary midline frenum and its treatment: a systematic review of the literature.Quintessence international. 2013;44(2): 177-187.