DEVELOPMENT OF ODONTOMA IN THE PERMANENT DENTITION AFTER INTRUSION OF PRIMARY INCISORS: CASE REPORT

Daniela Maria Carvalho **Pugliesi**[1]*, Valdeci Elias dos Santos **Junior**[1], Camila Maria Beder **Ribeiro**[1], Lisa Danielly Curcino **Araujo**[1], Pedro Jorge Cavalcante **Costa**[1], Guilherme Costa do **Amaral**[2]

[1]School of Dentistry, Federal University of Alagoas, Maceió, AL, Brazil.
[2]Faculty of Dentistry of the University Center Cesmac, Maceió, AL, Brazil.

Palavras-chave: Traumatismos Dentários. Luxação Intrusiva. Odontoma.

RESUMO

Introdução: O traumatismo dentário na infância é uma intercorrência grave, de incidência alta devido principalmente a fase de descobertas, com o início dos primeiros passos, sem ter coordenação motora adequada, tornando as crianças mais propensas a quedas. Um trauma em um dente decíduo pode deixar sequelas em razão da proximidade anatômica ao germe do dente sucessor permanente. **Objetivo:** O objetivo deste trabalho foi relatar um caso de intrusão grave em bebê de 10 meses, com surgimento de Odontoma após trauma dentário. **Relato de Caso:** Paciente de 9 anos de idade, acompanhada pela responsável, procurou atendimento pelo atraso na esfoliação dos dentes decíduos. Durante a anamneses foi constatado traumatismo na dentição decídua aos 10 meses de idade, e em seguida realizado o exame clínico e radiográfico, demostrando a presença de odontoma nos dentes 11 e 21. O plano de tratamento multidisciplinar compreendeu a cirurgia para remoção do odontoma, com posterior tratamento ortodôntico reabilitador. **Conclusão:** O trauma na dentição decídua pode gerar diversas consequências para a dentição permanente. Desse modo é necessário um atendimento odontológico logo após o incidente e um proservação do caso, para avaliar possíveis sequelas.

Keywords: Dental Injuries. Intrusive Dislocation. Odontoma.

ABSTRACT

Introduction: Dental trauma in childhood is a serious and high incidence complication, mostly due to the discovery phase. This is when the first steps begin, without adequate motor coordination, making children more prone to falls. Trauma to a deciduous tooth can leave sequelae owing to the anatomical proximity to the permanent successor tooth germ. **Objective**: This study aimed to report a case of severe intrusion in a 10-month-old baby with the emergence of odontoma after dental trauma. **Case Report:** A 9-year-old patient, accompanied by the guardian, sought attendance for delayed primary teeth exfoliation. During anamnesis, the trauma to the deciduous dentition was found in a 10-month old child, followed by clinical and radiographic examination, showing the presence of odontoma in teeth 11 and 21. The multidisciplinary treatment plan included surgery to remove the odontoma, with subsequent rehabilitation. **Conclusion**: Trauma to primary dentition can have several consequences for permanent dentition. Thus, dental care is required soon after the incident, besides careful follow-up to evaluate possible sequelae.

Submitted: June 27, 2019
Modification: August 21, 2019
Accepted: September 6, 2019

***Correspondence to**:
Daniela Maria Carvalho Pugliesi
Address: Av Lourival Melo Mota, S / N, the Martins Board, Maceió, AL, Brazil. Zip code: 57072-970.
Telephone number: 55 (82) 99993-9933
E-mail: dpugliesi@hotmail.com

INTRODUCTION

Traumatic injuries in primary teeth are common events in early childhood, with prevalence around 30%, from a very early age, considering children are learning to walk and discover everything around and are more likely to suffer traumatic injuries.[1,2]Curiosity and restlessness, behavioral characteristics of this age group, cause the child to explore the environment surrounding it. However, because they do not have sufficiently mature motor skills to prevent falls and to promote self-protection, they are potential subjects to mouth[3]trauma.[4]

Note that, as in very young patients, trauma is not only physical. There is the children's emotional involvement and that of their companions, who often come forward with an immediate solution.[5,6] Dentists should be prepared to receive and to solve the treatment needs of each type of dental trauma, transmitting security and reassuring the family.[7-9]

About 90% of the injuries affect the maxilla and, as a result of the anatomical arrangement, the upper central incisor teeth are the most often involved. The dislocation type of injury is the most common in deciduous teeth, constituting more than 88% of the different types of traumas affecting these teeth. This is due to the higher porosity and resilience of the alveolar bone in this age group, which favors displacements, contrary to what occurs in permanent teeth, which are prevalent fractures .[5-10,11]

Among the dislocations affecting the deciduous teeth, intrusive trauma occurs at a frequency that varies from 15 to 23%. [9-14] The intrusions are the result of a direct impact, accident in the incisal edge in an axial direction by moving the tooth towards the interior of its cavity, producing a maximum damage to the pulp and the tooth support structures. [2,4,9-10, 12-14]

In addition to the epidemiological relevance, importance determined by other injuries to primary teeth, is the potential to cause disturbances in the germs of the permanent teeth which are developing.[6,7,10,14] Thus, the care of children with trauma in the primary dentition requires a different approach from that to permanent ones, since the anatomical relationship between both dentitions is considered a risk factor in the onset of damage to permanent odontogenesis. [6,7,9, 10-15]

In this sense, intrusion again emerges as the type of dental injury that occurs to primary dentition and more often leads to damage to the germs of permanent teeth, with a prevalence ranging between 18 and 69%. [5-7, 9-12,14,15-17] The sort and severity of the development changes caused at the time of the traumatic impact depend on several factors, including the type of trauma in primary teeth, direction and severity of tooth displacement, the child's age at the time of trauma and type of treatment used. [2,4-7,10-12,16-20]

One of the most serious consequences observed after the intrusion of primary teeth is the development of odontomas involving the permanent successor germs. This kind of defect is considered a benign odontogenic tumor, in which all dental tissues are represented[21]. The histogenesis of the lesion is currently considered a developmental disorder and, as such, can occur under the influence of several causative agents. [22-24]

Clinically, they are most commonly detected in the first two decades of life, with a predilection for females. [21-24].Their pathogenesis is an investigated aspect, albeit undetermined so far. The most accepted etiology is related to trauma, infection or pressure, causing disturbance in the genetic control mechanism and tooth development. [20-27]

Regarding dental trauma, this change is believed to be due to a severe dental injury affecting 1 to 3-year old children, [20-23] when at the time of impact, the deciduous tooth root invades the follicle germ of the permanent tooth in the early stage of its training, fragmenting it. This fragmentation can result in the formation of a mass composed of separate tooth tissue structures. [21-24, 25,26-29]

Thus, the purpose of this study is to report a case of severe intrusive luxation of teeth 51 and 61 in a 10-month old baby with their consequent re-eruption after 5 months. However, at 9 years of age, due to the non-exfoliation thereof, we performed a routine radiographic examination and found odontoma-like malformations involving the central incisors permanent successors.

CASE REPORT

A 9-year old female patient came for dental treatment accompanied by her mother, who reported that "my daughter's teeth were not replaced." During anamnesis, we did not observe any systemic disease but, in an intraoral-physical examination, the preceding prolonged retention of deciduous incisors, and multiple carious lesions in other elements were observed (Figure 1A and 1B). In the image examination, panoramic radiographs showed the presence of two radiopaque calcified lesions in the anterior maxilla, impacting the eruption of the permanent successors, suggesting odontoma (Figure 1C).

The mother reported that her daughter tumbled off the crib at 10 months, and the child hit its mouth against the ground, causing a severe intrusive luxation of teeth 51 and 61. Also according to the mother, after five months, the same re-eruption was uneventful. A CT scan was requested (CT), using cone beam jaw (3D CT scanner Cranex), to close the complete diagnosis of the case. The tomographic report revealed the presence of a two-compound included odontoma, located below the crowns of teeth 11 and 21, interfering with their eruption (Figure 1D).

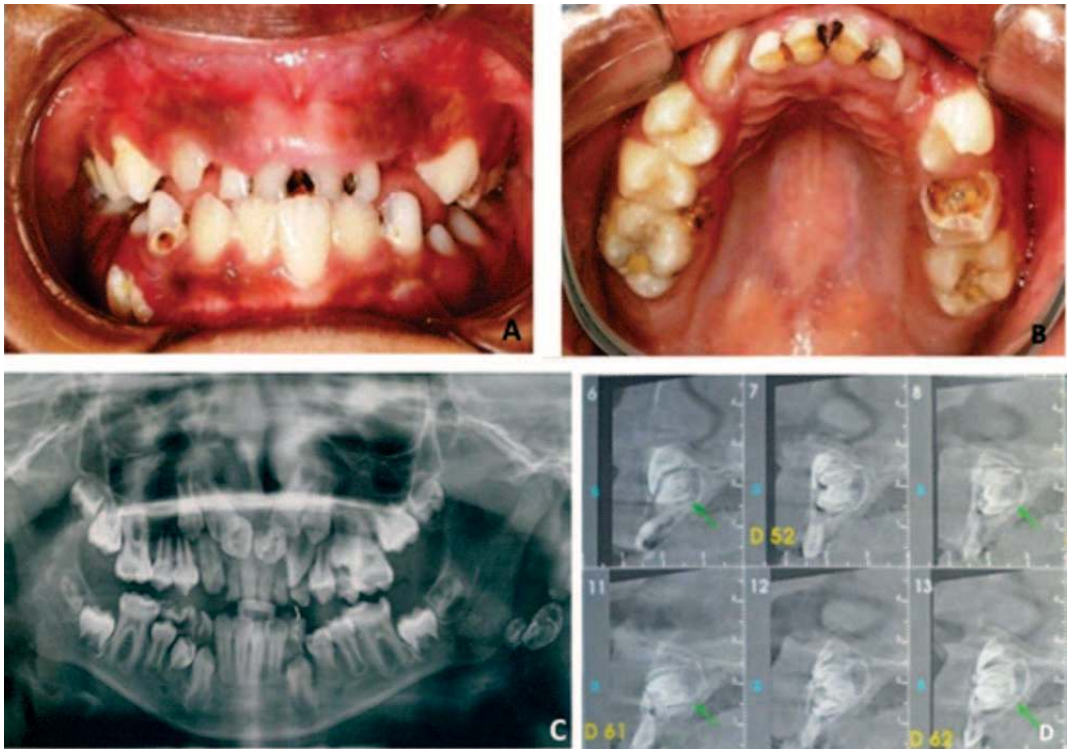

***Figure 1**: (A) Intraoral appearance showing prolonged retention of the foregoing upper deciduous incisors; (B) Intraoral appearance showing extensive carious lesions; (C) Panoramic X-ray image showing retention associated with radiopaque lesions suggesting odontoma; (D) CT image demonstrating sequences of parasagittal sections showing primary elements of the fasteners associated with the presence of odontoma.*

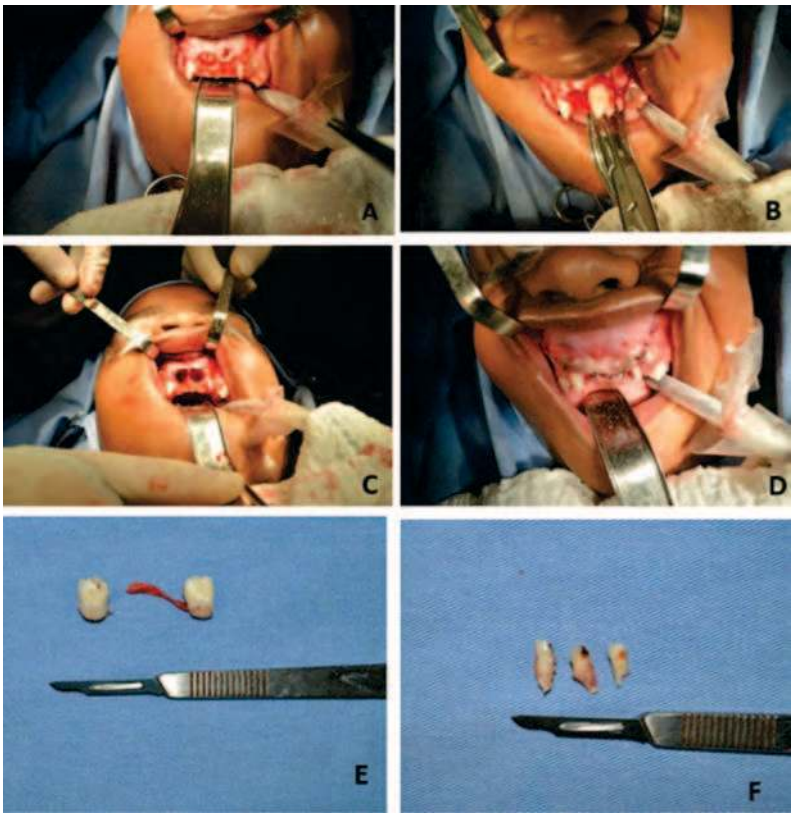

***Figure 2**: (A) Ostectomies and exposure of odontomas right and left; (B) Removing the top left; (C) Intraoral appearance of the front view of the surgical sites; (D) Retail repositioned and isolated simple point suture; (E) Macroscopic aspects of odontomas sent for histopathological examination; (F) Deciduous extracted elements.*

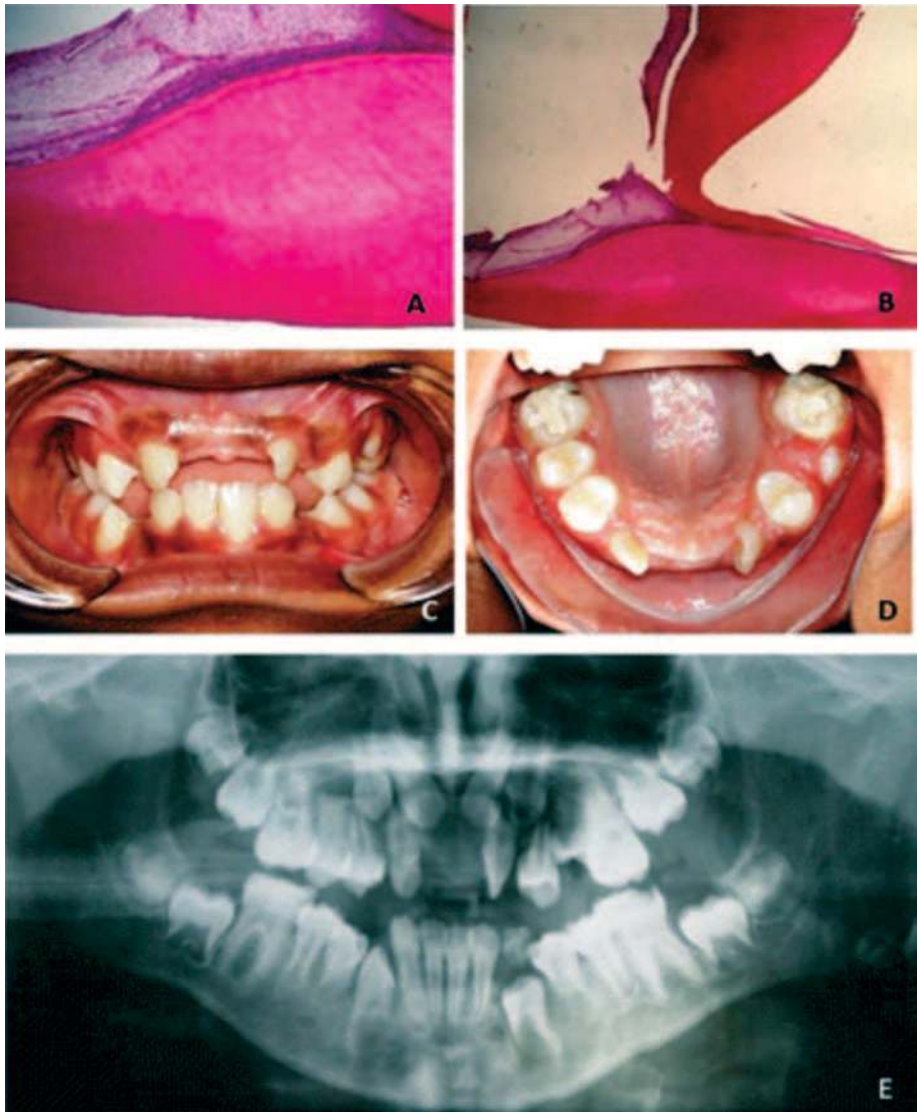

***Figure 3**: (A) Light microscopy 100x HE stains, descaling blade showing the tubular dentin and dentin pre-dental pulp; (B) 40X light microscopy HE stains, descaling blade showing the tubular dentin and dentin pre-dental pulp; (C) Intra-oral findings presenting normality; (D) Intra-oral findings presenting normality;(E) Panoramic postoperative image after 1 month and 15 days during follow-up queries.*

With clinical and imaging diagnosis compatible with odontoma compounds, we carried out the planning of the treatment. We decided for surgical removal, under general anesthesia with intubation. The surgical protocol consisted of extra and intraoral antisepsis with 2% chlorhexidine gluconate. A buccal access was made, after the removal of the primary elements. We performed the Newman incision modified type, two relaxant incisions extending between elements 13 and 23. The mucoperiosteal flap folding apical to the odontoma presented equidistant crowns of elements 11 and 21, not favoring palatal access for the removal. Ostectomy was performed with surgical spherical drill number 6 with micromotor and straight piece, enabling access to both odontomas, which were removed with the aid of curved and straight lifts.

The bony window was curetted and irrigated with 0.9% saline solution. The flap was repositioned, and sutures performed with simple isolated spots (Figure 2). The patient was instructed about the postoperative care and treated with antibiotic, analgesic, anti-inflammatory and targeted hygiene mouthwash without alcohol. There were no major complications in the postoperative period following the surgical procedure.

Odontomas were sent for histopathologic examination at the University Center CESMAC and the primary teeth were extracted, reporting that macroscopic bone fragments had the same oval shapes, lobulated, of hard consistency and whitish; the microscopy histological sections revealed fragments of dental structures, such as dentin and pulp, which confirmed the histologic diagnosis of compound odontoma (Figures 3A and B).

Seven days after the odontomas surgical removal, there was favorable healing, and the suture was in position without signs of infection. The patient has been followed clinically and radiographically, showing no signs of recurrence and bone structures showing normal characteristics (Figure 3C, D and E). After 3 months, a CT scan for postoperative evaluation was performed, and it was possible to observe the movement of the permanent central incisors, to the operating space, where they occupied the odontomas place.

DISCUSSION

In 1970, Andreasen[30] stated that the periapical region of deciduous incisors is separated from the bone crypt permanent successors by a thin connective tissue membrane. This membrane, however, is not resistant to root displacement of deciduous teeth, as in cases of traumatic injury. Hence, any trauma to temporary teeth can lead to odontogenesis disturbances in the permanent dentition. Therefore, less or more severe defects can be observed in the morphology of this dentition, both clinically and radiographically.

An intruded primary tooth is strongly related to damage to the permanent successors, as there is a high possibility of physical contact between the traumatized tooth and successor germs. The intrusive force is applied by moving the root of the primary tooth to the palate, by contacting the permanent follicle germ in development. [2,5-7,15,20-24]

One of the consequences that can be observed in the permanent teeth after trauma, particularly in intrusions in deciduous predecessors, is the formation of odontomas. Although their etiology is not yet fully elucidated, dental trauma is suggested to be responsible for their formation; the injury to deciduous root causes a change in odontogenesis germ-forming, causing fragmentation. [21,23, 25-27]

In the reported case, the 10-month old child, who was still in the early development of successor germs, fell from the cradle, causing teeth 51 and 61 to suffer severe intrusion. The earlier the stage of odontogenesis, the more severe the consequences for the teeth in formation are known to be.[25] This episode is believed to have accounted for causing these anomalies involving the successors. Thus, there is a direct relationship between the age at which the patient suffered the trauma, the type of trauma and the consequences for the permanent successor tooth.

Odontoma can be defined as an odontogenic tumor that consists of epithelial and mesenchymal cells.[20-26] According to Tommasi,[21] odontoma is classified into complex and compound. The complex one is formed by a spherical or oval dental tissue mass and is irregularly distributed. The compound one was defined as an injury in which all the dental tissue is shown in an orderly manner, with at least a surface anatomic similarity to normal teeth often presented in the form of denticles. [21,25-27]The effect of the compound odontoma corresponds to 67% of the cases, while the complex one has a prevalence of 33%. Both more often affect females, children and adolescents [21,25-27] and are more frequently located in the anterior maxillary region, involving central incisors, lateral and permanent canines. [7,15,21,25-27]

As previously reported, the clinical case is in line with several previous works: the compound odontoma type (most common), affected a female (9-year old) child and reached the anterior maxilla (permanent central incisors).The radiographic image of the pathognomonic compound odontoma consists of 2 or more denticles, which simulate small teeth as having a disordered conglomerate radiopaque areas mediated by the assembly being surrounded by a radiolucent area. [21,22,25-27] In panoramic radiography, we observed the presence of two opaque calcified masses in the anterior maxilla, which impacted the eruption of the permanent successors.

The presence of odontoma can cause great inconvenience, and highlight the problems related to interference with the teeth eruption process, slowing or preventing normal eruption movements. For these reasons, most authors recommend that once this anomaly is detected, it must be surgically removed. The treatment is its total surgical excision, with favorable prognosis, adequate bone repair, and rare cases of recurrence. [18,25-27,29]

In the reported case, the patient was taken to hospital for having the lesions removed. Odontomas were entirely removed. When the child first came to rehabilitation treatment, it featured several teeth rather compromised by caries. Orthodontic treatment also required applying orthodontic traction to teeth 11, 21, which were included. However, both teeth are now free of the mechanical obstacle that prevented their satisfactory eruptions.

Until the last radiographic and tomographic examinations, there were no complications and / or relapse. According to the tomographic reports, teeth 11 and 21 are included in oblique position with the crown positioned labially with open apex, showing the elements which are following their eruption axis. Due to the decrease of the arch perimeter conditioned by prolonged retention of the deciduous teeth, orthodontic harmony accompaniment to the return of arches and auxiliary eruption is required.

Acknowledgments

This study would have been impossible without the support of the Faculty of Dentistry of University Center CESMAC.

REFERENCES:

1.Joho JP, Marechaux SC. Trauma in the primary dentition: a clinical presentation. ASDC J Dent Child. 1980; 47(3): p. 167-174.
2.Andreasen JO, Andreasen FM. Textbook and color atlas of traumatic injuries to the teeth. 3ª Edn.Mosby, Copenhagen. 1994.
3.Walter LRF, Ferelle A, Issao M. Odontologia para o bebê: odontopediatria do nascimento aos 3 anos. São Paulo: Artes Médicas; 1997.
4.Cardoso M, Rocha MJC. Traumatized primary teeth in children assisted at the Federal University of Santa Catarina, Brazil. Dent Traumatol. 2002; 18(3): p. 129-133.
5.Fried I, Erickson P. Anterior tooth trauma in the primary dentition: incidence, classification, treatment, methods and sequelae: a review of the literature. ASDC J Dent Child. 1995; 62(4): p. 256-261.
6.Conti G, Franchi L, Camporesi M, Defraia E. Treatment protocol for the impaction of deciduous maxillary anterior teeth due to compound odontoma. Eur J Paediatr Dent 2012; 13: 337-41.
7.Andreasen JO, Ravn JJ. The effect of traumatic injuries to primary teeth on their permanent successors. II. A clinical and radiographic follow-up study of 213 teeth. Scand J Dent Res. 1971; 79(4): p. 284-294.
8.Bastone EB, Freer TJ, McNamara JR. Epidemiology of dental trauma: a review of the literature. Aust Dent J. 2000; 45(1): p. 2-9.
9.Cunha RF, Pugliesi DMC, Correa MG, Assuit DM. Early treatment of an intruded primary tooth: a case report. J Clin Pediatr Dent. 2001; 25(3): p. 199-202.
10.Cunha RF, Delbem AC, Vieira AEM, Pugliesi DMC. Treatment of a severe dental lateral luxation associated with extrusion in an 8-month-old baby: a conservative approach. Dent Traumatol. 2005; 21(1): p. 54-56.
11.Fried I, Erickson P, Schwartz S, Keenan K. Subluxation injuries of maxillary primary anterior teeth: epidemiology and prognosis of 207 traumatized teeth. Pediatr Dent. 1996; 18(2): p. 145-151.
12.Lombardi SM, Sheller B, Williams BJ. Diagnosis and treatment of dental trauma in a children's hospital. Pediatr Dent. 1998; 20(2): p. 112-120.
13.Mackie IC, Blinkhorn AS. Dental trauma: 1. General history, examination and management of trauma to the primary dentition. Dent Update. 1996; 23(2): p. 69-71.
14.Pugliesi DMC, Cunha RF, Delbem AC, Sundefeld MLMM. Influence of the type of dental trauma on the pulp vitality and the time elapsed until treatment: a study in patients aged 0-3 years. Dent Traumatol. 2004; 20(3): p. 139-42.
15.Van Gool AV. Injury to the permanent tooth germ after trauma to the deciduos predecessor. Oral Surg Oral Med Oral Pathol. 1973; 35(1): p. 2-12.
16.Bennett DT. Traumatised anterior teeth. Br Dent J. 1964; 116(1): p. 52-55.
17. Bardellini E, Amadori F, Pasini S, Majorana A. Dental Anomalies in Permanent Teeth after Trauma in Primary Dentition. The Journal of Clinical Pediatric Dentistry 2017; 41(1): 5-9.
18.Tekkesin MS, Tuna EB, Olgac, V, Aksakallý N, Alatlý C. Odontogenic lesions in a pediatric population: Review of the literature and presentation of 745 cases. International journal of pediatric otorhinolaryngology 2016; 86:196-199.
19. AmaralFreitas G, Brasileiro CB, Pereira de Araújo Zarzar PM, Ferreira FM. Rare dental developmental disturbance in primary and permanent teeth following trauma prior to tooth eruption: Case report. Dental Traumatology.2019; doi: 10.1111/edt.12500. [Epub ahead of print].
20.Amorim LFG, Estrela C, Costa LRRS. Effects of traumatic dental injuries to primary teeth on permanent teeth – a clinical follow-up study. Dent Traumatol 2011; 27: 117-121.
21.Tommasi, A. F. Diagnóstico em patologia bucal. 3.ed. São Paulo: Pancast, 1998. p. 664.
22.Küchler EC, Fidalgo TKS, Farinhas JA, Costa MC. Developmental dental alterations in permanent teeth after intrusion of the predecessors: clinical and microscopic evaluation. Dent Traumatol 2010; 26: p. 505-508.
23.Scerri E, Gatt G, Camilleri S, Mupparapu M. Morphologic and developmental disturbance of permanent teeth following trauma to primary dentition in a selected group of Maltese children. Quintessence International 2010; 41(9): p. 717-725.
24.Gondim JO, Giro EMA, Neto JJSM, Coldebella CR, Bolini PDA, Gaspar AMM. Sequelas em dentes permanentes após trauma nos predecessores decíduos e sua implicação clínica.RGO – Rev. Gaúcha Odontol., Porto Alegre 2011, v.59, suplemento O, p. 113-120.
25. Lenzi MM, Alexandria AK, Ferreira DM, Maia LC. Does trauma in the primary dentition cause sequel in permanent successors? A systematic review. Dent Traumatol. 2015; 31:79-88.
26. Costa VP, Goettems ML, Baldissera EZ, Bertoldi AD, Torriani DD.Clinical and radiographic sequelae to primary teeth affected by dental trauma: a 9-year retrospective study. Braz Oral Res. 2016;30(1). pii: S1806-83242016000100702.
27.Padmanabhan MY, Pandey RK, Aparana R. Erupted composite odontoma associated with malformed teeth – unusual dental aberrations following maxillofacial trauma. Rom J Morphol Embryol 2013, 54(4): p. 1153-1156.
28.Carvalho V, Jacomo DR, Campos V. Frequency of intrusive luxation in deciduous teeth and its effects. Dent Traumatol 2010; 26: p. 304-307.
29. Fang QG, Shi S, Sun CF. Odontogenic lesions in pediatric patients. J Craniofac Surg. 2014; 25(3):248-251.
30.Andreasen JO. Etiology and pathogenesis of traumatic dental injuries: a clinical study of 1298 cases. Scand J Dent Res. 1970; 78(4): 329-342.