ORAL FINDINGS IN ROBINOW SYNDROME: A CASE REPORT IN PEDIATRIC PATIENT

Camila **Nassur**[1], Adílis Kalina **Alexandria**[2*], Luciana **Pomarico**[1], Gloria Fernanda Barbosa de Araújo **Castro**[1]

[1]Department of Pediatric Dentistry and Orthodontics, School of Dentistry, Federal University of Rio de Janeiro (UFRJ), Rio de Janeiro, RJ, Brazil
[2]Department of Preventive and Community Dentistry, Rio de Janeiro State University (UERJ), Rio de Janeiro, RJ, Brazil

Palavras-chave: Odontopediatria. Saúde Oral.Tratamento Dentário.

RESUMO

Objetivo: O objetivo deste artigo foi descrever um caso de síndrome de Robinow em um paciente pediátrico. **Relato de Caso**: Clinicamente, o paciente apresentava bossas frontais, perfil facial plano com macrocefalia, hipoplasia da face média, hipertelorismo, fissuras palpebrais amplas, boca triangular, nariz curto, filtro curto, anquiloglossia, retenção prolongada de dentes decíduos e dentes desalinhados. Os exames radiográficos indicaram a presença de três elementos supranumerários permanentes impactados, agenesia de oito dentes permanentes e encurtamento radicular de todos os dentes permanentes. O tratamento proposto foi a extração de todos os dentes decíduos retidos e os elementos supranumerários, instruções de higiene bucal e dietética e tratamento ortodôntico. Além disso, aspectos importantes para evitar complicações associadas à síndrome de Robinow são discutidos. **Conclusão**: Este caso descreve achados orais incomuns e alguns aspectos importantes para evitar complicações associadas à síndrome de Robinow. Aconselhamento profissional precoce, tratamento e acompanhamento periódico podem melhorar a qualidade de vida desses pacientes.

Keywords: Pediatric Dentistry. Oral Health. Dental Treatment.

ABSTRACT

Objective: The aim of this article was to describe a case of Robinow syndrome in a pediatric patient. **Case Report:** Clinically, the patient had frontal bossing, flat facial profile with macrocephaly, midfacial hypoplasia, hypertelorism, wide palpebral fissures, triangular mouth, short upturned nose, short philtrum, ankyloglossia, prolonged retention of primary teeth and abnormal aligment of teeth. The radiographic exams indicated the presence of three impacted permanent supernumerary teeth, agenesis of eight permanent teeth and dental root shortening of all permanent teeth. The treatment proposed was the extraction of all retained primary teeth and the supernumerary teeth, dietary and oral hygiene instructions and orthodontic treatment. Also, important aspects to avoid complications associated with Robinow syndrome were discussed. **Conclusion:** This case describes uncommon oral findings and some important aspects to avoid complications associated with the Robinow syndrome. Early professional advice, treatment, and periodical follow-ups can improve the quality of life of these patients.

Submitted: June 7, 2019
Modification: September 6, 2019
Accepted: September 9, 2019

***Correspondence to:**
Adílis Kalina Alexandria
Address: Departamento de Odontologia Preventiva e Comunitária, Faculdade de Odontologia, Universidade do Estado do Rio de Janeiro, Pavilhão Mario Franco Barroso 2º andar. Av. 28 de Setembro, 157 - Vila Isabel, Rio de Janeiro, RJ, Brazil.
Zip code: 20551-030
E-mail: adilis.alexandria@gmail.com.br

INTRODUCTION

The Robinow syndrome (RS) is a rare genetic disorder as a syndrome characterized by a fetal face, orodental abnormalities, mesomelic dwarfism and genital hypoplasia. [1] The syndrome is classified into dominant or recessive type and the recessive form has more severe symptomology. [2-3] Affected in equal frequency males and females and occur in 1:500.000 births, the prevalence is low, because due cardiac problems, 5–10% of the children die in infancy. [4] The gene for the autosomal recessive Robinow syndrome was mapped and first localized to chromosome 9q22. [5] Facial and oral findings are important to diagnosis, management and planning of dental treatment for Robinow syndrome patients.

Cardiovascular, craniofacial and renal tract abnormalities were reported, skeletal abnormalities as wide forehead, hypertelorism, midface hypoplasia, depressed nasal bridge, compressed and enlarged nose, low-set ears, micrognathia and triangular mouth were observed. [6-8] Usual oral findings comprise dental anomalies and dental crowding, gingival hyperplasia and tongue abnormalities. [6,9] The aim of this article is to present a case of a child with autosomal recessive Robinow syndrome and describe the facial and dental abnormalities.

CASE REPORT

A 13 year old male, leucoderma, was diagnosed with Robinow syndrome and was referred by his pediatric doctor to the Pediatric Dentistry Department of a public university in Rio de Janeiro, Brazil, for a dental appointment.

During anamnesis, the mother reported an uneventful pregnancy, and hospitalization of the patient for 28 days at birth was due to septic arthritis. According to his medical history, the patient was diagnosed at birth as having the



***Figure 1**: (A) Frontal extraoral aspect of patient. (B) Lateral extraoral aspect of patient.*



Figure 2**: (A) Intraoral aspect of mouth. (B) Upper arch aspect and (C) Lower arch **aspect.

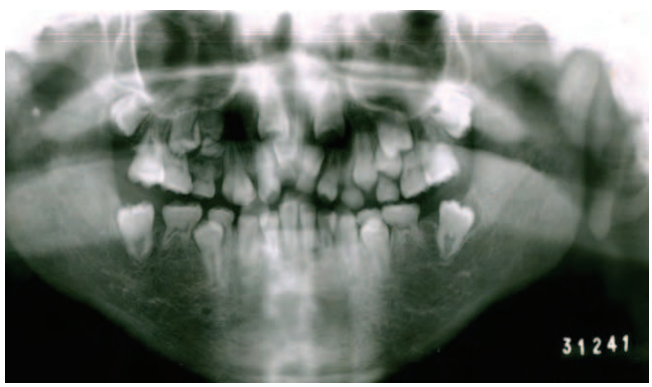

***Figure 3**: Orthopantographic radiograph: dental root shortening of all permanent teeth.*



Figure 4: *Orthodontic treatment using a fixed orthodontic appliance.*

Robinow syndrome with the autosomal recessive form (diagnosis based on clinical features alone), as he had characteristic facial dysmorphism (fetal facies), genital hypoplasia, and mesomelic brachymelia.

The family history was negative for even the mildest manifestations of the Robinow syndrome and revealed the absence of parental consanguinity; also the patient´s elder sibling showed none of the clinical aspects typical of the syndrome. At the age of 6, he underwent a surgical procedure to evaginate his micropenis. He exhibited a normal intelligence, and no congenital heart disease was diagnosed.

Extraoral examination revealed frontal bossing, flat facial profile with large head, long philtrum, lower lip deficiency, midfacial hypoplasia, hypertelorism, wide palpebral fissures, ear abnormality, small and lower set, triangular mouth, short upturned nose and broad nasal bridge (Figure 1A and 1B).

Intraoral examination revealed shortened and bifid tongue, gingival hyperplasia, and ankyloglossia. Also, the exam showed a prolonged retention of four primary canines, the primary upper central incisors and the primary lower and upper first molars. Good oral hygiene was observed and no caries were found but there were misaligned teeth (Figure 2A, 2B and 2C).

The radiographic exams indicated the presence of another two impacted permanent supernumerary elements in the pre-maxilla region and one supernumerary tooth near the upper right first premolar, agenesis of the four second premolars, lower permanent second and third molars. Furthermore, panoramic radiograph showed dental root shortening of all permanent teeth (Figure 3).

The treatment proposed extraction of all retained primary teeth and the supernumerary elements, dietary and oral hygiene instruction. The treatment of patient was planned after medical approval. The patient was referred for orthodontic treatment and, is using a fixed orthodontic appliance since one year ago (Figure 4).

DISCUSSION

Robinow syndrome is a genetic disorder characterized by facial dysmorphisms, genital hypoplasia, and orodental abnormalities. [1] The autosomal recessive form is caused by variants in ROR2 at 9q22 and encodes a tyrosine kinase receptor involved in cell growth and differentiation. [5-6]

Recognize facial and oral findings is important to planning dental treatment and some common findings in a Robnow syndrome patient were also observed in our clinical case as short stature, mesomelic limb shortening, short and broad fingers, macrocephaly and a dysmorphic face with prominent eyes, flat nasal bridge, frontal bossing, hypertelorism, short noses and dental anomalies. [6,8,9] According to Mazzeu *et al.,* [7] over 79% of patients with RS present these characteristic facial features. Other associated malformations include cleft lip and palate, syndactyly and heart defects [6,7] that were not observed in the patient.

In relation to orofacial manifestations of the Robinow syndrome, Basman *et al.* [9] described a case with a boy that presented tongue tip absence, ankyloglossia, arched palate and delayed tooth eruption. In our case, these findings were also present, except the arched palate. Others findings that coincide with our case were also recognized by Altunkas *et al.* [10] as new syndrome features and include: short tooth roots and narrow and thick-oored pulp chambers. However, some features described in our case are rarely described in a case of RS, including prolonged retention of primary teeth, supernumerary teeth and the absence of permanent teeth. Although facial dysmorphism is evident, intraoral aspects are little explored in literature, so we emphasize the importance of reporting such findings and proposing treatments that may bring quality of life for these patients.

Mazzeu *et al.* [7] described supernumerary teeth exclusively in patients with the dominant form, only in 10.3% of these patients. The problems most commonly associated with supernumerary teeth include impairment of the chronology of eruption, rotation and crowding, resorption of adjacent teeth and cyst formation. [7,11] Prolonged retention of deciduous teeth can be also associated with dental crowding, that are prevalent in patients with RS. The severity of the dental crowding contributes to increase the appearance of gingival hyperplasia and alveolar deformity. [7,11] Despite dental crowding, there isn't necessarily a lack of space, and the diastemas which can be observed are a result of hypodontia. [11] Shift in the normal midline, difficulty in dental hygiene, severe anterior open bite, deep bite, anterior and posterior crossbite were frequently found in these patients. [7,12] Though, no specific malocclusion characterizes this syndrome [8,12] early diagnosis and treatment are essential to prevent or minimize complications.

Most of the patients with Robinow syndrome have normal intelligence and accept treatment, however, they often require surgical interventions due to bone deformities and the need for dental extractions. [4] Hypertension, heart and kidney disease are frequent findings associated to RS and may represent complicating factors for surgeries. [9,11] Our patient did not report any systemic problem during anamnesis, despite that, medical authorization were requested before the extraction of supernumerary and retained primary teeth. Cardiac, renal disease, hypertension and vertebral anomalies have been reported in older patients, [9,11,13] it seems that such problems may arise in childhood or later. But no reports of surgical complications were found in RS patients.

A disabled person most often presents some difficulties or a delay in their psychomotor development, speech acquisition and other skills, thus, often the dental treatment provided is less than the real needs. However, when the patient has the ability to cooperate during dental treatment, which was the case with our patient, the treatment can be performed more efficiently. The good behavior of our patient allowed extractions under local anesthesia and then the orthodontic treatment to promote dental alignment, improving aesthetics and facilitating patient oral hygiene. The patient is still undergoing orthodontic treatment, but this could be performed as usual. Other articles cited the need for gingival and orthodontic corrections in patients with RS, successfully performing common treatment. [9,13] Only one case has been found reporting severe hyperplastic gingival tissue impeding both normal tooth eruption as well as orthodontic movement, probably caused by the use of growth hormone. [8]

This case describes uncommon oral findings and some important aspects to avoid complications associated with the Robinow syndrome. Early professional advice, treatment, and periodical follow-ups can improve the quality of life of these patients.

REFERENCES

1. Robinow M. The Robinow (fetal face) syndrome: a continuing puzzle. Clin Dysmorphol. 1993, 2(3):189-98.

2. Jain PS, Gupte TS, Jetpurwala AM, Dedhia SP. Robinow Syndrome and Fusion of Primary Teeth. Contemp Clin Dent. 2017, 8(3):479-481.

3. Kamath BM, Bason L, Piccoli DA, Krantz ID, Spinner NB. Consequences of JAG1 mutations. J Med Genet. 2003, 40(12):891-5.

4. Hosalkar HS, Gerardi J, Shaw BA. Robinow syndrome. J Postgrad Med. 2002, 48(1):50-1.

5. Soman C, Lingappa A. Robinow Syndrome: A Rare Case Report and Review of Literature. Int J Clin Pediatr Dent. 2015, 8(2):149-152.

6. Mishra S, Agarwalla SK, Pradhan S. Robinow Syndrome: A Rare Diagnosis. J Clin Diagn Res. 2015, 9(12):SD04-5.

7. Mazzeu JF, Pardono E, Vianna-Morgante AM, Richieri-Costa A, Kim C, Brunoni D, Martelli L, de Andrade CE, Colin G, Otto PA. Clinical characterization of autosomal dominant and recessive variants of Robinow syndrome. Am J Med Genet. 2007, 143(4):320-5.

8. Grothe R, Anderson-Cermin C, Beiraghi S. Autosomal recessive Robinow syndrome: a case report. J Dent Child. 2008, 75(1):48-54.

9. Basman A, Akay G, Peker I, Gungor K, Akarslan Z, Ozcan S, Ucok CO. Dental management and orofacial manifestations of a patient with Robinow Syndrome. J Istanb Univ Fac Dent. 2017, 51(2):43-48.

10. Altunkas A, Sarikaya B, Aktas F, Ozmen Z, Sonmezgoz F, Acu B, Pinarbasili T, Firat MM. Vertebral anomalies accompanying Robinow syndrome. Spine J. 2016, 16(5):e341-2.

11. Beiraghi S, Leon-Salazar V, Larson BE, John MT, Cunningham ML, Petryk A, Lohr JL. Craniofacial and intraoral phenotype of Robinow syndrome forms. Clin Genet. 2011, 80:15-24.

12. Cerqueira DF, de Souza IP. Orofacial manifestations of Robinow's syndrome: a case report in a pediatric patient. Oral Surg Oral Med Oral Pathol Oral Radiol Endod. 2008, 105(3):353-357.

13. Tufan F, Cefle K, Türkmen S, Türkmen A, Zorba U, Memduh D, Ozturk S, Palanduz S, Ecder T, Mundlos S, Horn D. Clinical and molecular characterization of two adults with autosomal recessive Robinow syndrome. American Journal of Medical Genetics. 2005, 136A:185-189.