EVALUATION OF THE SUCCESS RATES OF IMMEDIATE IMPLANT PLACED IN ANTERIOR AND POSTERIOR REGIONS: A RETROSPECTIVE STUDY

Rodrigo Ramos Silveira **Lucas**[1], Cintia Carneiro Pinheiro **Martins**[1], Henrique Eduardo **Oliveira**[1], Bruno Queiroz da Silva **Cordeiro**[1], Aldir Nascimento **Machado**[1], Priscila Ladeira **Casado**[1*], Telma Regina da Silva **Aguiar**[1], Gilson Coutinho **Tristão**[1]

[1]Department of Dental Clinic, School of Dentistry, (UFF) Fluminense Federal University, Niterói, RJ, Brazil.

Palavras chaves: Implante Imediato. Alvéolo Fresco. Índice de Sucesso.

RESUMO

Introdução: A utilização de implante imediato em regiões posteriores tem apresentado resultados contraditórios. **Objetivo**: O objetivo deste estudo foi comparar o índice de sucesso e previsibilidade à curto prazo de implantes imediatos instalados em regiões anterior e posterior. **Métodos:** Um total de 1000 prontuários foram analisados, dos quais 43 foram incluídos neste estudo: Anterior (n=20) e posterior (n=23). Os critérios de inclusão foram: Indicação de extração dentária, instalação de implantes imediatos unitários, no mínimo doze meses de segmento com implante funcional. Os critérios de sucesso foram baseados na escala de saúde dos implantes dentários do Congresso Internacional de Implantologia Oral, eixo I. e II.: ausência de dor, ausência de mobilidade, ausência de exudato e perda óssea de até 4 mm. Valor de p<0.05 foi considerado estatisticamente significante. **Resultados:** O índice de sucesso dos implantes imediatos foi de 97,7% para implantes em função por pelo menos 12 meses. O uso de biomaterial (p=0,03) e prótese provisória (p<0,0001) foi significantemente maior em região anterior. Não foi encontrado diferença significante quanto a falha dos implantes comparando os dois grupos (p=0,47). Não houve diferença estatisticamente significante entre os grupos, considerando a idade, gênero, motivo da extração, torque inicial, tempo de tratamento e tipo de plataforma do implante (p>0,05). **Conclusão:** Pode-se concluir que as regiões anterior e posterior apresentaram alta taxa de sucesso a curto prazo quanto a técnica de implante imediato.

Keywords: Immediate Implants. Fresh Socket. Success Rate.

ABSTRACT

Introdution: Immediate implants placement has shown contradictory results in the posterior region. **Objective:** The aim of the study was to compare the success rate and predictability of the short-term treatment using immediate implants in anterior and posterior regions. **Methods:** A total of 1000 dental charts were analyzed, of which 43 were included in the study: anterior (n=20) and posterior (n=23). The inclusion criteria were: tooth extraction indication, immediate single-tooth implant placement and at least twelve months of follow-up with functional implant. The success rates were based on the criteria I. and II. from the health scale for dental implants proposed at the International Congress of Oral Implant Dentistry: no pain; no mobility, until 4 mm of bone loss, no exudate. *P*-value <0.05 was considered significant. **Results:** The total success rate of immediate implants was 97.7% for immediate implants in function for at least 12 months. The use of biomaterial (p=0.03) and temporary prosthesis (p<0.0001) were significantly higher in the anterior group. There was no significant difference in implant failure between groups (p=0.47). There was no statistical difference between the groups, considering age, sex, extraction reason, initial torque immediately following implant placement, treatment time and implant platform type (p> 0.05). **Conclusion:** It may be concluded that the anterior and posterior regions present a high short-term success rate when the immediate implant technique was used.

Submitted: May 11, 2019
Modification: October 4, 2019
Accepted: October 7, 2019

***Correspondence to:**
Priscila Ladeira Casado
Address: Mario Santos Braga Street, 28 - Centro - Niterói – RJ – Brazil.
Zip code: 24020-140
Telephone number: +55 (21) 2629-9920
E-mail: priscilacasado@id.uff.br

INTRODUCTION

The success of osseointegrated implants in daily practice derives from the research of Professor Per Ingvar Branemark who, after his prospective and multicentric studies, contributed to the predictability of these devices as success rates were above 90%,[1-4] making most rehabilitation cases of edentulous areas and replacement of teeth indicated for extraction[5] a reality and the first choice in implant dentistry based on his concept of osseointegration.[6,7]

Post-extraction bone resorption is critical during the first six months and it occurs both in the bucco-lingual and apical-coronal directions.[8] Studies that observed alveolar remodeling, using radiographic image subtraction, study models and linear radiographs, have found bone loss of up to 50% in the bucco-lingual area during the first twelve months following extraction[9] of which 2/3 occur in 3 months.[8] In the anterior maxillary region, bone loss is greater in the buccal region, making the esthetics more difficult.[10]

Within this context, implant dentistry has developed the technique of immediate implant placement following tooth extraction that consists of using the remaining bone walls to insert the implant in a way that 3 to 5 mm exceeds the apical limit of the alveolus, with the purpose of achieving primary stability and preserving the bone structure.[11-13] Although this technique does not prevent bone resorption, it may decrease its extent. [11-13]

The advantages when choosing immediate implants include reduction of time and cost of rehabilitative treatment, lower morbidity, patient satisfaction, and improved esthetic results.[14-17]

However, the following technical and biological factors should be considered when opting for immediate implant placement following extraction: morphology of the bone defect and favorable three-dimensional positioning of the implant, time of surgery for implant placement, presence of acute infection, reason for tooth extraction, thickness of buccal alveolar wall, skill of surgeon, and achievement of primary stability.[10,14,18,19]

Ten to fourteen days after implant placement, a process of immature trabecular bone formation adjacent to the implant begins, culminating with the achievement of secondary or biological stability that, despite lower mechanical competence, offers high resistance for early implant loading.[20] The process of osseointegration is complete in 2 and 3 months, showing a high degree of mineralization of mature bone formation.[6,21]

However, despite advances and predictability of this technique, studies point to a higher risk of infection or failures in immediate implant procedures and it is considered a complex technique with high risks if the criteria for case selection and planning are not respected[8,22] such as in cases where implants are placed more buccally or when the bone wall is thin or damaged, or cases of thin gingival biotypes.[23,24]

In addition, some studies[25,27] question the use of the technique in the posterior region due to the low quantity and poor quality of bone (especially in the maxilla), greater occlusal forces that affect the area, and proximity to anatomical structures (maxillary sinus or mandibular canal), which hinder the achievement of primary stability.

In clinical practice in implant dentistry, many cases of immediate implant placement show a high success rate in the anterior region and contradictory results in the posterior region, considering a prognosis. [25,28,29]

Therefore, the purpose is to increase the treatment prognosis with implants placed in fresh alveoli, furthering knowledge on the use of this technique in the posterior region. Thus, the aim of the study was to compare the success rate and predictability of the short-term treatment using immediate implants in the anterior and posterior regions of the oral cavity. Our hypothesis is that there is no difference in success rates between regions.

MATERIALS AND METHODS

This is a retrospective research that was submitted and approved by the Research Ethics Committee of the School of Medicine of the Fluminense Federal University, Rio de Janeiro, Brazil, under report No 1,779,121, October 17, 2016.

Sample

A total of 1000 dental charts from the Specialization Course in Implant Dentistry of the Fluminense Federal University were analyzed, of which 250 dental charts described tooth extraction and immediate implant procedures.

Of these, 45 dental charts were selected according to the following inclusion criteria: cases of indication for extraction followed by immediate placement of single-tooth osseointegrated implants into the alveolus, submitted to implant surgery, and at least twelve months of follow-up with implant in function, from 2003 to 2013.

Patients who did not receive implants placed into the alveoli or those receiving multiple prostheses (such as protocol-type and overdenture prosthesis) were excluded from the study.

However, 2 cases of anodontia of permanent dentition with immediate implant placement after deciduous extraction were also excluded. Thus, a total of 43 dental charts were included in this study.

The following data were collected from the dental

charts: age, sex, number of tooth extracted, extraction reason, date of surgery, type and sizes of implant, torque obtained, use and type of biomaterial, use and type of temporary prosthesis, date of placement of definitive prosthesis.

The health scale for dental implants proposed at the International Congress of Oral Implant Dentistry,[30] in Pisa, 2008, was used as a criterion for implant success or failure in our analysis. The clinical criteria included in this scale are: I. Success (no pain; no mobility, < 2mm bone loss, no exudate) II. Satisfactory Survival (no pain, no mobility, 2-4mm bone loss, no exudate); III. Compromised Survival (possible sensitivity, no mobility, > 4mm bone loss, probing depth > 7mm and history of exudate); IV. Failure (pain, mobility, radiographic bone loss greater than half its length, uncontrolled exudate, or if the implant is no longer in mouth). In this study we considered implant success according to criteria I and II for the scale of health.[30]

Statistical analysis

Numerical variables were represented as mean and standard deviation. The Shapiro-Wilk test for the normality of the distribution and Student's-t test were used. The nominal variables were compared using the Pearson chi-square test. P-values lower than 0.05 were considered statistically significant. All analyses were performed in the GraphPad Prism 7.0 software.

RESULTS

Of the 1000 dental charts analyzed from the Clinic of the Specialization Course in Implant Dentistry of the Fluminense Federal University, 43 cases of immediate implant placement that met the inclusion criteria of the study were identified, 20 in the anterior region and 23 in the posterior.

The mean age of the patients was 47.83 ± 10.83 years, of which 29 were women and 14 men, with implant in function for at least 12 months. The most common cause of dental extraction was tooth fracture (22 cases - 51.1%) (Figure 1 and Figure 2), of which 33 (76.7%) were maxillary implants and 10 (23.3%) mandibular implants. Thirty-eight implants were of the external hexagon type (88.4%) (Figure 3), 4 (9.3%) cone morse implants and 1 (2.3%) internal hexagon implant (Conexão Sistema de Próteses, São Paulo, Brazil), with lengths ranging from 10mm to 13mm.

The mean torque achieved during immediate implant placement was 41.97 ± 12.54 N, all implants achieved primary stability.

Biomaterial was used to fill the alveolar implant gap in 26 sites (60.5%), with predominance of: Osteogen® (Intra-Lock, São Paulo, Brazil) in 16 cases (37.2%), Bioss® (Geistlich Pharma do Brasil, São Paulo, Brazil) in 3 cases (7%), Alobone® (Osseocon Biomateriais, Rio de Janeiro, Brazil) in 2 cases (4.6%), GeniOx® (Baumer, São Paulo, Brazil) Brazil) in 1 case (2.3%), Osteosynt® (Eincobio, Minas Gerais, Brazil) in 1 case (2.3%), and autogenous grafts from the intra-oral region in 2 cases (4.6%).

A temporary prosthesis was used only in the anterior region, representing 100% of the cases in this region, with only 1 (5%) being an immediate loading case with an anchoring provision in the implant itself. Partial removable prostheses were used in 18 (90%) cases and a temporary adhesive fixed prosthesis in 1 case (5%).

The total time of evaluation after implant placement was 6 ± 2.23 years after implant placement. The success rate of immediate implants at the Clinic of Implant Dentistry of the Fluminense Federal University, over the course of 12 months with implant in function was 97.7%.

For comparative analysis of the success rate in the anterior and posterior regions, the placement of immediate implants was divided into two groups: anterior (n = 20) and posterior (n = 23). The analysis of the differences between the groups studied is shown in Table 1.

There was no statistical difference between the groups, considering age, sex, extraction reason, initial torque immediately following implant placement, treatment time and implant platform type (p> 0.05).

Considering the type of implant, although the EH type was predominant in both groups, there was a higher incidence of MC (p=0.05) in the group that received immediate anterior implants.

The use of biomaterial during the surgical procedure as well as the temporary implants (p <0.0001) was significantly higher in the anterior group than in the posterior group (p = 0.03). However, considering the success rate in both groups, there was no statistically significant difference in implant failure (p = 0.47).

Only 1 case of implant loss was reported, in a patient showing bruxism during the anamnesis and that received a regular platform EH immediate implant after tooth fracture, without the use of biomaterial, and with provisional removable temporary prostheses. The implant length was 10 mm and it showed mobility after prostheses rehabilitation.

***Table 1**: Results comparing the anterior and posterior regions.*

	Anterior N=20	Posterior N=23	*p*-value
Age	45.85 ±10.69	49.39 ±10.73	0.14
Sex			
Women	13	16	0.50
Men	7	7	
Extraction reason			
Frature	13	9	0.11
Endodontic failure	2	4	
Caries	4	3	
Periodontitis	1	7	
Type of Implant[a]			
MC	4	0	**0.05**
EH	16	22	
IH	0	1	
Implant plataform			
Regular	18	23	0.21
Narrow	2	0	
Torque (N)	40.5 ±9.98	46.23 ±14.02	0.23
Region			
Maxilla	20	13	**<0.0001**
Mandible	0	10	
Biomaterial	16	10	**0.03**
Temporary Implant	19	1	**<0.0001**
Time of pre-prosthesis (months)[b]	9.31 ± 6.42	13.18±11.99	0.10
Implant failure	1	0	0.47

***Note**: [a]MC: Morse cone; EH: external hexagon; IH: internal hexagon; [b]time interval between implant placement and prosthesis.*

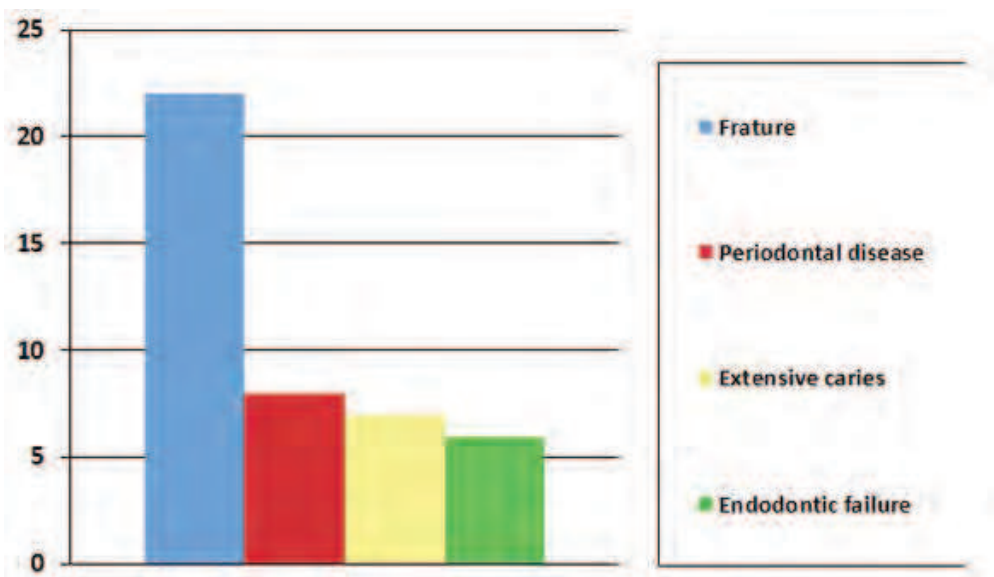

***Figure1**: Reasons for indication for extraction in the studied population (in absolute numbers).*



***Figure 2**: Indication for extraction due to fracture (red arrow) of tooth 22.*

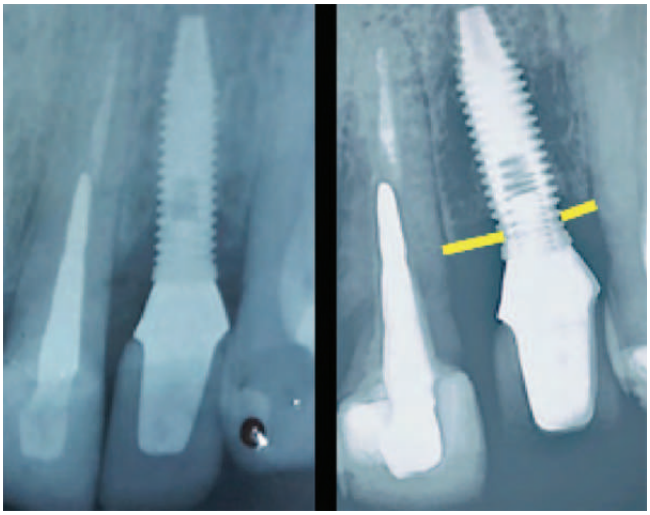

***Figure 3**: External-hexagon immediate implant placed in the area of tooth 22 (patient from Figure 2). This X-ray represents the image immediately after implant placement (left) and 2 years after healing (right) showing the saucerization around external hexagon implant and the level of bone formation.*

DISCUSSION

When considering the therapeutic choice for replacing a tooth indicated for extraction, some factors should be taken into consideration such as: bone preservation, esthetic result, lower morbidity and greater predictability. The option for immediate implant procedure is well established in the literature,[31] but there is debate regarding the technique protocol, as well as the success rates according to the region of the implant placement.

This study did not identify a significant difference in the use of immediate implants into the alveoli in the anterior or posterior regions, comparing, characterizing and, above all, evaluating the longevity of the technique over the course of 12 months.

Modern implant dentistry has been primarily focused on the rehabilitation of partially or completely edentulous patients.[2,3] At present, there is a large influx of patients at clinics in need of tooth replacements. This is a great opportunity for the clinician to decide which moment is the best for implant placement following tooth extraction.[14,31] The therapeutic choice for immediate implant placement to replace a tooth indicated for extraction is good and safe[32] with high success rates in the scientific literature that range from 92.7% to 98.0%,[8,13,15] reported mainly in the anterior region. Our retrospective study corroborates these data showing a survival rate of 97.7% of implants in the anterior and posterior region after at least 12 months following implant placement.

Interestingly, despite contradictory literature,[25,33,34] considering rehabilitation with immediate implant in the posterior region, the success rate among the regions studied was similar in our study and the only case of implant loss occurred in the anterior region after 2 months.

The failure rate for single implants is low in the literature, from 1 to 2.4%, both in early and late failure of implant placements, including in the molar area.[12,13] The minimum follow-up of 12 months after implant is in function seems adequate and sufficient for this analysis regarding the survival of the implant.[34,35] Therefore, in our study, a follow-up of at least 12 months after implant placement was performed, reinforcing the predictability not only of the immediate implant placement in the anterior and posterior regions, but also when the implant is in function.

However, correct planning, considering the site and its anatomical defects, is important for the viability and survival of the immediate implants [8]. In a tomographic evaluation of the thickness of the buccal wall of teeth in the anterior maxillary region, Braut et al.[36] observed that, in most cases, thickness was less than 1mm at the crest level (62.9%) and at the middle of the root (80.1%). The study by Cooper et.al [37] showed that implant surgery of 15 patients (21%) out of 73 patients were canceled due to anatomical conditions (bone loss, dehiscence and fenestrations in the buccal wall).

Recently, Garcia e Sanguino[38] suggested a protocol for the diagnosis and selection of cases for immediate implants, pointing out 5 key points: presence of buccal wall, achievement of primary stability, conical implant design, atraumatic surgery, gap filling and favorable gingival biotype. In addition, whenever possible, temporary crowns

attached to the implant is recommended to favor the tissue profile. [37]

In our study, only the cases of immediate implant placement following extraction and rehabilitation with single prostheses in function for a minimum period of twelve months were considered. Thus, a small number of cases of immediate single-tooth implants were selected (43 cases). Furthermore, our sample was homogeneous regarding age, sex, extraction reason, initial torque following immediate implant placement, treatment time, and type of implant platform, reinforcing our finding of short-term results.

The causes for tooth extraction and consequent replacement by immediate implant were most frequently due to tooth fracture, followed by periodontal bone loss, extensive caries and endodontic failure, corroborating the current literature that reports dental fracture and periodontal impairment as the main causes for tooth extraction.[15]

Primary stability (measured in Ncm) has been cited as one of the fundamental requirements for immediate implant loading with values ranging from 30 to 40 Ncm in the literature.[23] In our study, this prerequisite was respected, mean torque being of 41.97 ± 12.54 N, which may explain the positive result and implant clinical success.

The selected implant sizes were based on the available anatomical space,[14] respecting the distances of the neighboring teeth or implants, distance from the buccal wall (2mm), and achievement of primary stability, exceeding the apical limit of the alveolus in 3-4mm in anterior region, which explains the choice for implants with a length equal to or greater than 10mm.

Although esthetics was not assessed in this study, there is literature evidence that a more significant esthetic result is achieved when the immediate implant receives immediate restoration, providing adequate peri-implant tissue regeneration and patient satisfaction.[38] De Rouck et al.[39] concluded that the immediate implant without restoration causes 2 to 3 times more gingival recession than the immediate implant with immediate restoration.

In a retrospective study of immediate implants following extraction using 800 dental charts, Bassi et al.[40] found 197 immediate implants and only 27.4% of them were rehabilitated with single-tooth implants, that is, 54 cases, which is in agreement with our study.

It is recommended that posterior implants do not receive occlusal loads during bone healing, [41] which was respected by the Clinic in Implant Dentistry, explaining the non-reporting of immediate loading in the posterior region and a temporary removable prosthesis only in one region.

Parafunctional habits such as bruxism and teeth clenching are highly related to failure in implant therapy as they generate forces that affect the cervical region, which may lead to resorption of the bone crest.[41] In our study it was observed that the only case of implant loss was of a patient who reported having bruxism during the anamnesis.

The site with the highest indication for immediate single-tooth implants was the anterior maxillary region (20 cases or 46.5%). This higher prevalence may be due to this region being considered an esthetic area, which involves greater patient demand and professional effort to restore, briefly, esthetics and function.

The absence of immediate implants in the anterior mandibular region is justified by the fact that immediate implants in this area, in all cases of our sample, require multiple or total rehabilitation, such as protocol-type or overdenture prosthesis, and thus these were excluded.

The present results emphasize a similar distribution among implants in anterior and posterior sites, reinforcing studies that showed indistinctness for indication and results between these areas.[42]

Some studies have failed to prove that filling the gap with biomaterial is effective to prevent vertical bone loss.[5,38] Others, however, have shown that this resource is used much less frequently, such as the study by Bassi et al.[40] who reported that the gap was filled with biomaterial in 33% of the cases. In these situations, the most important is the more palatal position of the implant and correct axial inclination.[8] In our study, the use of biomaterial in the surgical site and a temporary implant were significantly higher in the anterior group than in the posterior one. However, considering the success rate, no statistically significant difference was found in either groups regarding the use or not of biomaterial.

This result must be pointed out as it is known that single-tooth implants in posterior regions, especially molars, present occlusal, biomechanical and anatomical challenges such as: high occlusal loading, greater width of the alveoli, poor maxillary bone quality, and proximity with structures such as the maxillary sinus and mandibular canal.

The high success rate observed in the posterior maxillary and mandibular and anterior maxillary regions in our study reinforce the trend of success of rehabilitation using immediate implants. However, its important emphasize that our success criteria were based on the International Congress of Oral Implant Dentistry,[30] in Pisa, 2008, that considers implant failure if the following conditions are present: pain, mobility, bone loss greater than half its length, continuous exudate, or if implant has already been removed. If not, the implant placement was considered successful. This fact can be sometimes confounding when comparing the results with other researches. Kolerman et al.[43] showed 92% of success rate after anterior immediate implant placement,

but did not considered bone loss as a crucial aspect for failure characterization. On the contrary, a research from Cosny et al.[44] considered all characteristics around soft and hard peri-implant tissues, after healing, as a real parameter for success classification. This variation of the aspects concerning the true success rates, after implant placement, can become difficult the comparison among works, but do not invalidate the research *per si*, since that the parameters for success are well-described, as shown in our work. Therefore, despite this limitation, we consider that the results showing a high success rate in the anterior and posterior regions, reinforcing that rehabilitation with immediate implants is a highly predictable procedure, irrespective of the region.

CONCLUSION

The anterior and posterior regions present a high short-term success rate when the immediate implant technique was used.

REFERENCES

1. Adell R, Lekolm U, Rocler B, Brånemark PI. A 15 years study of implants in the treatment of the edentulous jaw. Int J Oral Surg. 1981; 10(6):387-416. doi:10.1016/S0300-9785(81)80077-4.

2. Albrektsson T, Brånemark PI, Hansson HA, Lindström J. Osseointegrated titanium implants Requirements for ensuring a long-lasting, direct bone-to-implant anchorage in man. Acta Odont Scand.1981; 52(2):155-170. doi:10.3109/17453678108991776.

3. Brãnemark PI. Osseointegration and its experimental background. J Prost Dent.1983; 50(3):399-409. doi: 10.1016/S0022-3913(83)80101-2.

4. Albrektsson TA. A multicenter study of osseointegrated oral implants. J Prosthet Dent .1983;60:75-84. doi: 10.1016/0022-3913(88)90355-1.

5.Ortega-Martinez J, Pérez-Pascual T, Mareque-Bueno S, Hermandez-Alfaro F, Ferres-Padro E. Immediate implants following tooth extraction. A systematic review. Med Patol Oral Cir Bucal 2012;17(2):251-261. doi: 10.4317/medoral.17469.

6. Mavrogenis AF, Dimitriou R, Parvizi J. Biology of implant osseointegration. J Musculoskelet Neuronal Interact. 2009;9(2):61-71.

7. Avila G, Galindo P, Rios H. Immediate implant loading: current status from available literature. Implant Dent. 2007; 16(3):235-245. doi: 10.1097/ID.0b013e3180de4ec5.

8. Weigl P, Strangio A. Immediately placed and restored single-tooth implants in the anterior maxilla. Eur J Oral Implantol 2016; Supl.1:89–106. doi: 10.1016/j.adaj.2017.05.008.

9.Schropp L, Kostopoulos L, Wenzel A. Bone healing following immediate versus delayed placement of titanium implants into extraction sockets: a prospective clinical study. Int J Oral Maxil Impl 2003;18:189-199. doi: 10.1016/S0022-3913(03)00476-1.

10. Del Fabbro M, Ceresoli V, Taschieri S, Ceci C, Testori T. Immediate loading of postextraction implants in the esthetic area: systematic review. Clin Impl Dent Rel Res. 2015; 17(1):52-69. doi: 10.1111/cid.12074. Epub 2013 Apr 22.

11. Chen ST, Wilson TG Jr, Hämmerle CH. Immediate or early placement of implants following tooth extraction: review of biologic basis, Clinical Procedures, and Outcomes. Int. J. Oral Maxil. Implants 2004;19:12–25.

12. Esposito M, Grusovin MG, Polyzos IP, Felice P, Worthington HV. Interventions for replacing missing teeth: dental implants in fresh extraction sockets (immediate, immediate-delayed and delayed implants). Chochrane Database Syst Rev. 2010; 8(9):CD005968. doi: 10.1002/14651858.CD005968.pub3.

13. Esposito M, Grusovin MG, Polyzos IP, Felice P, Worthington HV. Timing of implant placement after tooth extraction: immediate, immediate-delayed or delayed implants? A Cochrane systematic review. Eur J Oral Impl. 2010; 3(3):189-205.

14. Buser D, Chappuis V, Belser UC, Chen S . Implant placement post extraction in esthetic single tooth sites: when immediate, when early, when late? Periodontol 2000 2017; 73: 84-102. doi: 10.1111/prd.12170.

15. Peñarrocha M, Uribe R, Balaguer J. Immediate implants after extraction. A review of the current situation. Med Oral. 2004;9(3):234-242.

16. Cristalli MP, Marini R, La Monaca G, Sepe C, Tonoli F, Annibali S. Immediate loading of post-extractive single-tooth implants: a 1-year prospective study. Clin Oral Impl Res. 2015;26(9):1070-1079. doi: 10.1111/clr.12403. Epub 2014 Apr 16.

17. Goodacre C, Naylor WP. Single implant and crown versus fixed partial denture: a cost-benefit, patient-centred analysis**.** Eur J Oral Impl. 2016;9(supl.1):59-67.

18. Da Silva BC, De Carvalho PS, Vedovato E. Estudo retrospectivo da taxa de sobrevivência de implantes instalados por profissionais com diferentes graus de experiência na implantodontia. *RFO* 2015;20(3):295-301. doi: 10.5335/rfo.v20i3.4611.

19. Patil SS, Balkunde AS, Samanti A, Patil R, Kadam P. Complications of immediate implant placement and its management; a review article. Int J Cur Med App Sci. 2015; 8(3):78-80.

20. Botticelli D, Persson LG, Lindhe J, Berglundh T. Bone tissue formation adjacent to implants placed in fresh extraction sockets: an experimental study in dogs. Clin Oral Impl Res. 2006; 17:351–358. doi: 10.1111/j.1600-0501.2006.01270.x.

21. Esposito M, Hirsch JM, Lekholm U, Thomsen P. Biological factors contributing to failures of osseointegrated oral implants. (I) Success criteria and epidemiology. Eur J Oral Sci .1998; 106:527–551. doi: 10.1046/j.0909-8836..t01-2-.x.

22. Chrcanovic BR, Albrektsson T, Wennerberg A. Dental

implants inserted in fresh extraction sockets versus healed sites: A systematic review and meta-analysis. J Dent 2015; 43(1):16-41. doi: 10.1016/j.jdent.2014.11.007.

23. Nkenke E, Schliephake H. Immediate loading and immediate restoration of oral implants: indications and survival rates. J Dent implantol 2009; 25(2).

24. Lioubavina-Hack N, Lang NP, Karring T. Significance of primary stability for osseointegration of dental implants. Clin Oral Impl Res. 2006;17:244–250. doi: 10.1111/j.1600-0501.2005.01201.x.

25. Tolstunov L. Implant zones of the jaws: implant location and related sucess rate. J Oral Imp. 2007;33(4):211-220.

26. Jemt T, Karouni M, Abitbol J, Zouiten O, Antoun H. A retrospective study on 1592 consecutively performed operations in one private referral clinic. Part II: Peri-implantitis and implant failures. Clin Implant Dent Relat Res. 2017;19(3):413-422. doi: 10.1111/cid.12481

27. Simsek B, Simsek S. Evaluation of success rates of immediate and delayed implants after tooth extraction. Chin Med J. 2003;116(8):1216-1219.

28. Bilhan H, Mumcu E, Geçkili O, Atalay B. The Evaluation of the success of immediately placed single implants: A retrospective clinical study. Impl Dent. 2011;20(3):215-225. doi: 10.1097/ID.0b013e3182181ee6.

29. Moy PK, Nishimura GH, Pozzi A, Danda AK. Single implants in dorsal areas – A systematic review**.** Eur J Oral Impl 2016; 9(supl.1):163-172.

30. Misch CE, Perel ML, Wang HL, Sammartino G, Galindo-Moreno P, Trisi P, at al. Implant success, survival, and failure: The International Congress of Oral Implantologists (ICOI) Pisa Consensus Conference**.** Impl Dent. 2008; 17(1):5-15. doi: 10.1097/ID.0b013e3181676059.

31. Albrektson T, Wennerberg A. The impact of oral implants- past and future,1962-2042. J Can Dental Assoc. 2005;71(5):327-327d.

32. Tarazona B, Tarazona-Alvarez P, Penarrocha-Oltra D, Penarrocha-Diago M. Relationship between indication for tooth extraction and outcome of immediate implants: a retrospective study with 5 years. J Clin Exp Dent. 2014**;** 6(4):384-388. doi: 10.4317/jced.51616. eCollection 2014 Oct.

33. Chang PC, Lang NP, Giannobile WV. Evaluation of functional dynamics during osseointegration and regeneration associated with oral implants. Clin Oral Impl. Res. 2010;.21:1-12. doi: 10.1111/j.1600-0501.2009.01826.x.

34. Arlin ML. Immediate placement of osseointegrated dental implants into extraction sockets: advantages and case reports**.** Oral Health, 1992:.19-26.

35. Lang NP, Pun L, Lau KY, Li KY, Wong MC. A systematic review on survival and success rates of implants placed immediately into fresh sockets after at least 1 year. Clin Oral Impl Res**.** 2012; 23(supl.5):39-66. doi: 10.1111/j.1600-0501.2011.02372.x.

36. Braut V, Bornstein MM, Belser U, Buser D. Thickness of the anterior maxillary facial bone wall: a retrospective radiographic study using cone beam computed tomography. Int J Periodontics Restorative Dent. 2011**;** 31:125-131.

37. Cooper LF, De Kok IJ, Rojas-Vizcaya F, Pungpapong P, Chang SH. The immediate loading of dental implants. Comp Con Educ Dent. 2007; 28(4):216-225.

38. Garcia J, Sanguino D. A new protocol for immediate implants. The rule of 5 triangles. European Academy of Osseointegration – Clin Oral Impl Res. 2014; 4-5.

39. De Rouck T, Collys K, Cosyn J. Single-toth replacement in the anterior maxilla by means of immediate implantation and provisionalization: a review. Int J Oral Maxillofac Impl. 2008; 23(5):897-904.

40. Bassi AP, Ponzoni D, Carvalho P, Carrera ET. Estudo retrospectivo de implantes osseointegrados instalados imediatamente após exodontias. INPN 2014**;**11(2):233-236.

41. Vidal F, Rescala B, Rosalém Jr. W. Oclusão e protocolos de aplicação de cargas funcionais em implantes unitários posteriores. Implant News. 2013**;**10(1):41-48.

42. Ketabi M, Deporter D, Atenafu EG. A systematic review of outcomes following immediate molar implant placement based on recently published studies. *Clin Impl Dent Rel Res* 2016;18(6):1084-1094. doi: 10.1111/cid.12390. Epub 2016 Feb 8.

43. Kolerman R, Mijiritsky E, Barnea E, Dabaja A, Nissan J, Tal H. Esthetic assessment of implants placed into fresh extraction sockets for single-tooth replacements using a flapless approach. *Clin Implant Dent Relat Res*. 2017;19(2):351-364. doi: 10.1111/cid.12458.

44. Cosyn J, Eghbali A, De Bruyn H, Collys K, Cleymaet R, De Rouck T. Immediate single- tooth implants in the anterior maxilla: 3-year results of a case series on hard and soft tissue response and aesthetics. *J Clin Periodontol* 2011; 38: 746–753. doi: 10.1111/j.1600-051X.2011.01748.x.