

# IMPACTION OF MANDIBULAR CANINE ASSOCIATED WITH A DENTIGEROUS CYST: A 2.5-YEAR FOLLOW-UP REPORT

Thiago Isidro **Vieira**<sup>1,2</sup>, Thais Rodrigues Campos **Soares**<sup>1</sup>, Priscila Assunção de **Almeida**<sup>1</sup>, Fernanda Blaudt Carvalho **Marques**<sup>1</sup>, Monica Tirre de Souza **Araujo**<sup>1</sup>, Gloria Fernanda Barbosa de Araújo **Castro**<sup>1\*</sup>

<sup>1</sup>Department of Paediatric Dentistry and Orthodontics, School of Dentistry, Universidade Federal do Rio de Janeiro, Rio de Janeiro, RJ, Brazil.

<sup>2</sup>Postgraduate program, School of Dentistry, Universidade Federal da Paraíba, João Pessoa, Paraíba, PB, Brazil.

**Palavras-chave:** Cisto Dentígero. Dente Impactado. Mandíbula.

## RESUMO

**Introdução:** O cisto dentígero é uma lesão odontogênica ao redor da coroa de um dente não irrompido ou impactado na mandíbula. **Objetivo:** O objetivo deste relato de caso é descrever o plano do tratamento e o acompanhamento de um cisto dentígero associado à impaction do canino permanente inferior direito em uma criança do gênero feminino de 11 anos de idade. **Relato do caso:** A avaliação radiográfica revelou lesão unilocular radiolúcida de forma arredondada, localizada na sínfise mandibular. A enucleação foi realizada e o dente afetado foi removido sob anestesia geral. A paciente encontra-se em acompanhamento devido o tratamento ortodôntico. A área afetada curou sem complicações. **Conclusão:** Dois anos e meio após a enucleação, o cisto desapareceu totalmente e não houve recidivas. Remodelação óssea e neoformação foram observadas.

**Keywords:** Dentigerous Cyst. Tooth Impacted. Mandible.

## ABSTRACT

**Introduction:** Dentigerous cyst is an odontogenic cyst lesion surrounding the crown of an unerupted or impacted tooth in the jaw. **Objective:** The aim of this case report is to describe the treatment planning and follow-up of a dentigerous cyst associated with the impaction of the permanent mandibular right canine tooth in an 11-year-old female. **Case report:** Radiographic assessment revealed a radiolucent unilocular round-shaped lesion localized in the mandibular symphysis. Enucleation was performed and the affected tooth was removed under general anesthesia. The patient is under follow-up due to orthodontic treatment. The affected area healed without complications. **Conclusion:** Two and a half years after the enucleation, the cyst had totally disappeared, and no recurrences were observed. Bone remodeling and neoformation were noticed.

## INTRODUCTION

Dentigerous cyst is an odontogenic cyst lesion surrounding the crown of an unerupted or impacted tooth in the jaw. It is commonly asymptomatic and may appear as a painless swelling of the affected region and because of its specific feature it may be detected in routine radiograph examinations. Usually, it is a unilocular and radiolucent area associated with a well-defined sclerotic border.<sup>1</sup>

The prevalence of dentigerous

cyst shows that the male to female ratio ranges from 1.8:1 to 3:2.<sup>1,2</sup> In large sample studies, permanent mandibular canine is not the most commonly affected. The most frequent is third molar, followed by supernumerary teeth, second premolar and first molar / first premolar.<sup>3</sup> Other study indicates third molar as the most prevalent followed by supernumerary teeth.<sup>4</sup> An unerupted permanent tooth that has been affected may erupt or not in the oral cavity. Orthodontic correction can be employed for this purpose. Thus, the

Submitted: July 10, 2020  
Modification: Sept 08, 2020  
Accepted: Oct 14, 2020

### \*Correspondence too:

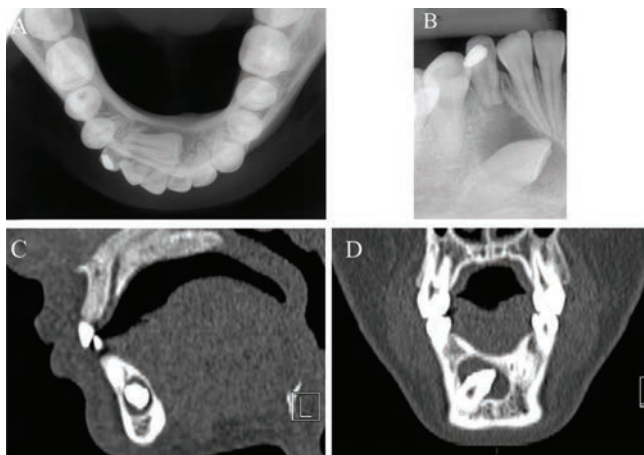
Glória Fernanda Barbosa de Araújo Castro  
Address: Caixa Postal: 68066 – Cidade Universitária - CCS  
Zip Code: 21941-971 - Rio de Janeiro – RJ – Brazil  
Telephone number/FAX: +55 (21) 3938-2101  
E-mail: gfbacastro@yahoo.com.br

aim of this report is to describe a case of a dentigerous cyst associated with the impaction of the permanent mandibular right canine tooth in an 11-year-old female child. This report was carried out according to the CARE Statement.<sup>5</sup>

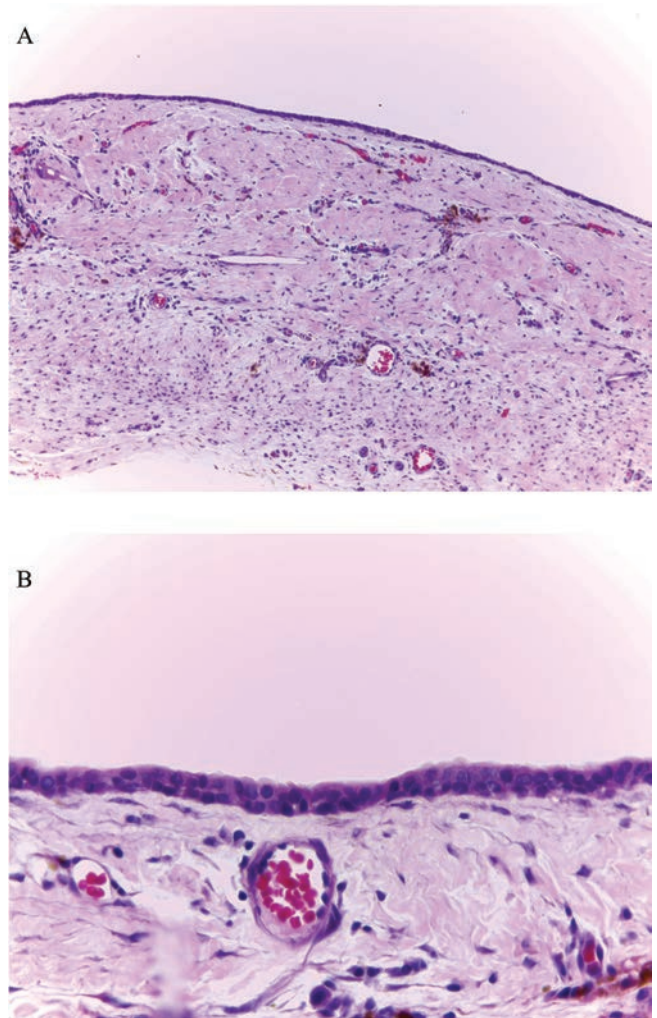
## CASE REPORT

An 11-year-old female child and her guardian came to the Department of Pediatric Dentistry and Orthodontics of Universidade Federal do Rio de Janeiro seeking for dental treatment. A term of free and informed consent signed by the participant and/or her legal guardian was obtained. According to the anamnesis, she was born by Caesarean section at 38 weeks with normal weight; she is not allergic to any drug and has never been hospitalized. Past medical history evidenced no illnesses. The subject was not taking any medication at her initial appointment.

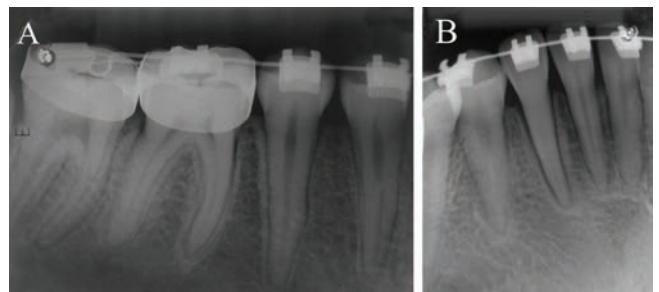
Clinical examination showed primary mandibular right canine tooth had a temporary filling in the cervical third. Oral hygiene was satisfactory. No changes in gingival color or purulent discharge were noticed in the region related to primary mandibular right canine tooth. The permanent mandibular right canine had not erupted while its homologous tooth had already been satisfactorily erupted in oral cavity. The occlusal (Figure 1A) and periapical (Figure 1B) radiographs and the multi-slice images from the computed tomography (Figure 1C and Figure 1D) scan examination showed the presence of impacted tooth (permanent mandibular canine) with an oblique arrangement in the right mandibular symphysis, inferior to the roots of the incisors and the lower right primary canine. A radiolucent round-shaped lesion was observed involving the crown of the impacted tooth measuring about 16 x 11 mm. The presumptive diagnosis was a dentigerous cyst at the time.



**Figure 1:** A) Occlusal radiograph. B) Periapical radiograph. C) Computed tomography sagittal scan showing a large hypodense lesion with intact lingual and buccal cortices. D) Computed tomography coronal scan.



**Figure 2:** A) H&E stained slide scan showing histological feature of the mandibular dentigerous cyst presenting non-keratinized squamous epithelium with cholesterol clefts (x10 magnification). B) Blood vessels (x40 magnification).



**Figure 3:** A) and B) Two and a half years follow-up. A post-treatment periapical radiograph showing complete bone formation.

The treatment plan consisted of extraction of primary mandibular right canine and permanent mandibular right canine, surgical removal of the lesion under general anesthesia, and oral hygiene instructions. This approach was conducted by the age of 11.33 years old. The patient was referred to orthodontics service. The histopathological results

confirmed the initial diagnosis of a dentigerous cyst. Microscopic findings showed cystic lesion with non-keratinised stratified squamous epithelium and a connective tissue with cholesterol clefts (Figure 2A) and blood vessels (Figure 2B).

Follow-up radiographs were taken by the age of 13.83 years old and the affected area healed without complications, complete bone formation was observed and there were no recurrences during this 2.5-year follow-up (Figure 3A and Figure 3B). A suggestive image of pulp calcium metamorphosis related to the permanent mandibular right lateral incisor was observed as well as an increase in its periodontal ligament space.

## DISCUSSION

Maxillary canine impaction is a relatively common dental problem observed in dental practice. Regarding lower teeth the occurrence of mandibular canine impaction ranges from 0.92 to 5.1%. The etiology of this condition is not solidified in pertinent literature but cysts and others pathological disorders may interact in this context.<sup>6</sup> According to gender predilection regarding tooth impaction, females are more affected than males with percentage frequencies ranging from 50.76 to 64.28%.<sup>7-9</sup> As reported herein the current study describes the case of a monolateral canine impaction in an 11-year-old female patient.

Regarding the radiographic analysis, additional exposure due to repeated evaluations should be avoided according to the European Academy of Paediatric Dentistry policy document.<sup>10</sup> The imaging characterization was possible because the patient is a cooperative child and was able to collaborate during the x-ray exposure. Cone-beam computed tomography was employed because cross-sectional slices were required for the current treatment planning.<sup>10</sup>

The treatment of young patients with large dentigerous cysts may vary according to morbidity; maintenance or not of affected permanent tooth and age of the patient.<sup>11</sup> Cyst enucleation and marsupialization are surgical options for dentigerous cyst treatment. The treatment employed in our case consisted of cyst enucleation and extraction of the impacted canine. This treatment plan is indicated for a single impaction such as in the current case as well as the cyst size not being so extensive. For an extensive cyst it is contraindicated because it would lead to the loss of some teeth. Cyst decompression is adequate conservative treatment for children because they regenerate bone faster than do adults.<sup>12</sup> This approach was not conducted due to location of the lesion and the impossibility of orthodontic realignment of the canine. Additionally, tooth associated with a dentigerous cyst can be maintained if it may erupt spontaneously or with the aid of orthodontics techniques.

Marsupialization surgical treatment may be employed in such cases and a successful outcome is expected.<sup>13</sup>

Regarding the histopathological assessment, the current case describes a cystic lesion with non-keratinised stratified squamous epithelium and a connective tissue with cholesterol clefts and blood vessels. These features are in accordance with pertinent literature. Stratified squamous lining epithelium and cholesterol clefts were frequently observed<sup>3,14,15</sup> as well as blood vessels.<sup>16</sup> The differential diagnoses include glandular odontogenic cyst; odontogenic keratocyst; unicystic ameloblastoma<sup>1</sup> and may be associated with adenomatoid odontogenic tumour.<sup>17</sup>

Previous literature has already assessed a 2-year follow-up period to observe lesion regression in children and adolescents.<sup>16</sup> The prevalence of recurrence is 13.43% (9/67) and the prevalence of neoplastic change is 1.49% (1/67).<sup>18</sup> Two and a half years after the enucleation, the cyst had totally disappeared and no recurrences were observed. Bone remodeling and neoformation were noticed. During follow-up the patient presented pulp obliteration of the permanent mandibular right lateral incisor, this calcification is caused by the deposition of diffuse hard tissue in the coronary pulp and may extend to the root canal space. Orthodontic treatment is considered one of the main etiological factors, however the exact mechanism of action is still unknown. Endodontic intervention is not necessary, as the tooth is asymptomatic and has no clinical or radiographic signs of caries or periapical disease.<sup>19-22</sup>

The current case reinforces the importance of the histopathological examination of all excised lesions from the jaws and vigilant follow-up appointments in order to observe any complication or recurrence after the surgical treatment. It should be emphasized that although dentigerous cyst is a common and benign lesion, careful anamneses, accurate diagnosis and good interpretation of clinical and radiographic findings is recommended.

## ACKNOWLEDGEMENTS

Marcello Roter Marins for surgical management of the case. This study was financed in part by the Coordenação de Aperfeiçoamento de Pessoal de Nível Superior – Brasil (CAPES) – Finance Code 001 and CNPq (159961/2018-1).

## REFERENCES

1. Thompson LD. Dentigerous Cyst. *Ear Nose Throat J.* 2018; 97(3):57. doi: 10.1177/014556131809700317.
2. Tamiolakis P, Thermos G, Tosios KI, Sklavounou-Andrikopoulou A. Demographic and Clinical Characteristics of 5294 Jaw Cysts: A Retrospective Study of 38 Years. *Head Neck Pathol.* 2019; 13(4):587-596. doi: 10.1007/s12105-019-01011-7.

3. Lin HP, Wang YP, Chen HM, Cheng SJ, Sun A, Chiang CP. A clinicopathological study of 338 dentigerous cysts. *J Oral Pathol Med.* 2013; 42:462–467. doi: 10.1111/jop.12042.
4. Mourshed F. A roentgenographic study of dentigerous cysts. III. Analysis of 180 cases. *Oral Surg Oral Med Oral Pathol.* 1964; 18:466–73. doi: 10.1016/0030-4220(64)90392-5.
5. Gagnier JJ, Kienle G, Altman DG, Moher D, Sox H, Riley D, et. al. The CARE Guidelines: Consensus-based Clinical Case Reporting Guideline Development. *Glob Adv Health Med.* 2013 Sep;2(5):38-43. doi: 10.7453/gahmj.2013.008.
6. Dalessandri D, Parrini S, Rubiano R, Gallone D, Migliorati M. Impacted and transmigrant mandibular canines incidence, aetiology, and treatment: a systematic review. *Eur J Orthod.* 2017; 39(2):161-169. doi: 10.1093/ejo/cjw027.
7. Yavuz MS, Aras MH, Büyükkurt MC, Tozoglu S. Impacted mandibular canines. *J Contemp Dent Pract.* 2007; 8(7):78–85.
8. Kara MI, Ay S, Aktan AM, Sener I, Bereket C, Ezirganli S, et al. Analysis of different type of transmigrant mandibular teeth. *Med Oral Patol Oral Cir Bucal.* 2011; 16(3):e335-40. doi: 10.4317/medoral.16.e335.
9. Jain S, Shetty KS, Prakash AT, Agrawal M, Jain S. Permanent mandibular canine(s) impaction: expansion of our understanding. *Aust Orthod J.* 2014; 30(1):39–44.
10. Kühnisch J, Anttonen V, Duggal MS, Loizides Spyridonos M, Rajasekharan S, Sobczak M, et. al. Best clinical practice guidance for prescribing dental radiographs in children and adolescents: an EAPD policy document. *Eur Arch Paediatr Dent.* 2020 Aug;21(4):375-386. doi: 10.1007/s40368-019-00493-x
11. Santos TS, Sehn FP, Dias RR, Xavier SP. Volume Increase of Dentigerous Cyst After Decompression. *J Craniofac Surg.* 2014; 25(6):2254-5. doi: 10.1097/SCS.0000000000000979.
12. Motamedi MHK, Talesh KT. Management of extensive dentigerous cysts. *Br Dent J.* 2005; 198:203–206. doi: 10.1038/sj.bdj.4812082.
13. Qian WT, Ma ZG, Xie QY, Cai XY, Zhang Y, Yang C. Marsupialization facilitates eruption of dentigerous cyst-associated mandibular premolars in preadolescent patients. *J Oral Maxillofac Surg.* 2013 Nov;71(11):1825-32. doi: 10.1016/j.joms.2013.06.223
14. Yeo JF, Rosnah BZ, Ti LS, Zhao YY, Ngeow WC. Clinicopathological study of dentigerous cysts in Singapore and Malaysia. *Malays J Pathol.* 2007; 29:41–7.
15. Chiang CP, Kwan HW. A clinicopathologic study of 70 cases of dentigerous cysts. *J Formos Med Assoc.* 1982; 81:686–91.
16. Marques NP, Marques NCT, Sakai VT, Hanemann JAC. Inflammatory Follicular Cysts Associated to Necrotic Primary Teeth. *Eur Arch Paediatr Dent.* 2017; 18(4):279-285. doi: 10.1007/s40368-017-0297-5.
17. Nonaka CF, de Souza LB, Quinderé LB. Adenomatoid odontogenic tumour associated with dentigerous cyst—unusual case report. *Braz J Otorhinolaryngol.* 2007; 73(1):129-31. doi: 10.1016/s1808-8694(15)31135-6.
18. Fickling BW. Cysts of the jaw: a long-term survey of types and treatment. *Proc R Soc Med.* 1965 Nov;58(11 Part 1):847-54.
19. Gomes CB, Treister NS, Miller B, Armand P, Friedland B. Pulp obliteration in a patient with sclerodermatous chronic graft-versus-host disease. *J Endod.* 2016; 42(4):678-680. doi: 10.1016/j.joen.2016.01.009.
20. McCabe PS, Dummer PM. Pulp canal obliteration: an endodontic diagnosis and treatment challenge. *Int Endod J.* 2012; 45:177–97. doi: 10.1111/j.1365-2591.2011.01963.x.
21. Goga R, Chandler NP, Oginni AO. Pulp stones: a review. *Int Endod J.* 2008; 41:457–68. doi: 10.1111/j.1365-2591.2008.01374.x.
22. Nayak M, Kumar J, Prasad LK. A radiographic correlation between systemic disorders and pulp stones. *Indian J Dent Res.* 2010; 21:369–73. doi: 10.4103/0970-9290.70806.